

Comparison of two protocols for maxillary protraction: bone anchors versus face mask with rapid maxillary expansion

Lucia Cevидanes^a; Tiziano Baccetti^b; Lorenzo Franchi^b; James A. McNamara, Jr^c; Hugo De Clerck^d

ABSTRACT

Objective: To test the hypothesis that there is no difference in the active treatment effects for maxillary advancement induced by bone-anchored maxillary protraction (BAMP) and the active treatment effects for face mask in association with rapid maxillary expansion (RME/FM).

Materials and Methods: This is a study on consecutively treated patients. The changes in dentoskeletal cephalometric variables from start of treatment (T1) to end of active treatment (T2) with an average T1–T2 interval of about 1 year were contrasted in a BAMP sample of 21 subjects with a RME/FM sample of 34 patients. All subjects were prepubertal at T1. Statistical comparison was performed with *t*-tests for independent samples.

Results: The BAMP protocol produced significantly larger maxillary advancement than the RME/FM therapy (with a difference of 2 mm to 3 mm). Mandibular sagittal changes were similar, while vertical changes were better controlled with BAMP. The sagittal intermaxillary relationships improved 2.5 mm more in the BAMP patients. Additional favorable outcomes of BAMP treatment were the lack of clockwise rotation of the mandible as well as a lack of retroclination of the lower incisors.

Conclusions: The hypothesis is rejected. The BAMP protocol produced significantly larger maxillary advancement than the RME/FM therapy. (*Angle Orthod.* 2010;80:799–806.)

KEY WORDS: Class III malocclusion; Maxillary protraction; Bone anchors; Facial mask; Cephalometrics

INTRODUCTION

Class III malocclusions result from a spectrum of cranial base, maxillary, and mandibular skeletal and

dental compensation components.^{1–5} To date, investigations have focused largely on treatment modalities and outcomes, with inconsistencies in the timing, duration, and type of treatment.^{5–19} The timing for effective maxillary expansion and protraction with combined rapid maxillary expansion and face mask therapy remains limited to the deciduous or early mixed dentitions,¹⁶ while maxillary protraction with bone anchors and Class III elastics^{20–23} has been successful in the late mixed or permanent dentition phases. The present study evaluated the effects of these two treatment modalities during the ideal timing for maxillary protraction with either therapy, provided that all observed patients in either group were prepubertal (a requisite for an orthopedic impact on maxillary sutural structures^{15,24}).

Specifically, the purpose of this study on consecutively treated patients was to compare active treatment effects in the skeletal maxillary and mandibular structures, and dentoalveolar compensations for two protocols for Class III treatment: bone-anchored maxillary protraction (BAMP) and face mask therapy in association with rapid maxillary expansion (RME/FM).

^a Assistant Professor, Department of Orthodontics, School of Dentistry, University of North Carolina, Chapel Hill, NC.

^b Assistant Professor, Department of Orthodontics, University of Florence, Florence, Italy; Thomas M. Graber Visiting Scholar, Department of Orthodontics and Pediatric Dentistry, School of Dentistry, University of Michigan, Ann Arbor, Mich.

^c Thomas M. and Doris Graber Endowed Professor of Dentistry, Department of Orthodontics and Pediatric Dentistry, School of Dentistry; Professor of Cell and Developmental Biology, School of Medicine; Research Professor, Center for Human Growth and Development, The University of Michigan, Ann Arbor, Mich; Private practice, Ann Arbor, Mich.

^d Adjunct Professor, Department of Orthodontics, School of Dentistry, University of North Carolina, Chapel Hill, NC; Private practice, Brussels, Belgium.

Corresponding author: Dr Tiziano Baccetti, Department of Orthodontics, University of Florence, Via del Ponte di Mezzo, 46-48, Florence, Italy 50127
(e-mail: t.baccetti@odonto.unifi.it)

Accepted: January 2010. Submitted: November 2009.

© 2010 by The EH Angle Education and Research Foundation, Inc.

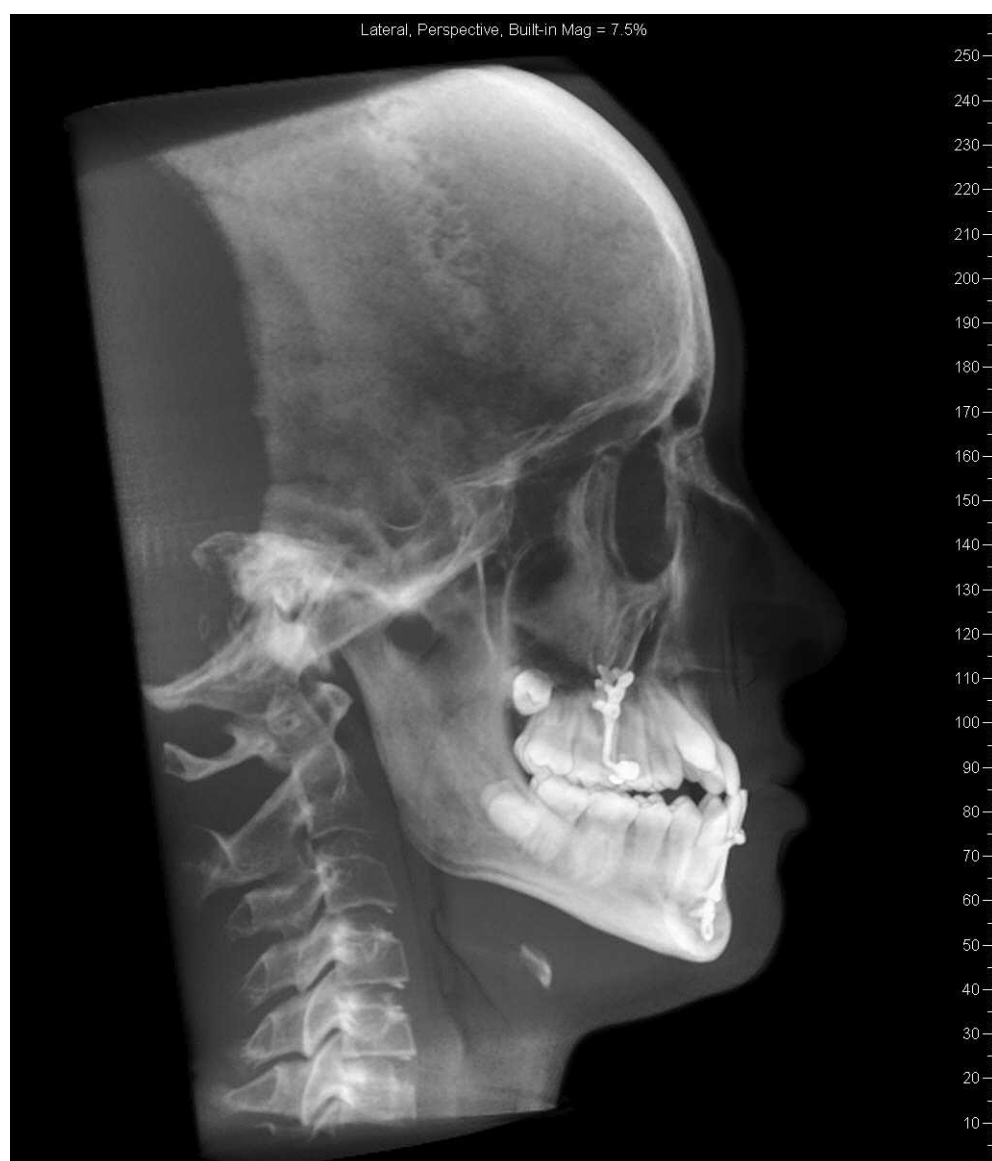

Figure 1. Synthetic lateral cephalogram generated from cone-beam computed tomography (CBCT).

MATERIALS AND METHODS

Subjects

The sample consisted of Class III malocclusion patients treated with BAMP or RME/FM. At the time of initial observation (T1), all patients in both groups had Class III malocclusion in the mixed or permanent dentitions characterized by a Wits appraisal of -1 mm or less, anterior crossbite or incisor end-to-end relationship, and Class III molar relationship. All patients were of White ancestry, with a prepubertal stage of skeletal maturity according to the cervical vertebral maturation method (CS1–CS3).²⁴ All patients were treated at least to a positive dental overjet before discontinuing treatment; most patients were overcorrected toward a Class II occlusal relationship.

Compliance with the instructions of the orthodontist and staff varied among the patients; variations due to compliance were not assessed in this study.

Twenty-one (11 girls, 10 boys) consecutive patients were treated by a single operator (Dr De Clerck) with the BAMP technique. Success of therapy at the end of the observation period was not a determinant factor for selection of patients because this sample was collected prospectively. An informed consent was signed by the parents of the patients before treatment. Cone-beam computed tomograms (CBCTs) were taken immediately following the placement of the miniplates (T1), and after approximately 1 year (T2). Scans were acquired using an iCat machine (Imaging Sciences International, Hatfield, Pa) with a $16\text{ cm} \times 22\text{ cm}$ field of view. The CBCTs were used to generate synthetic

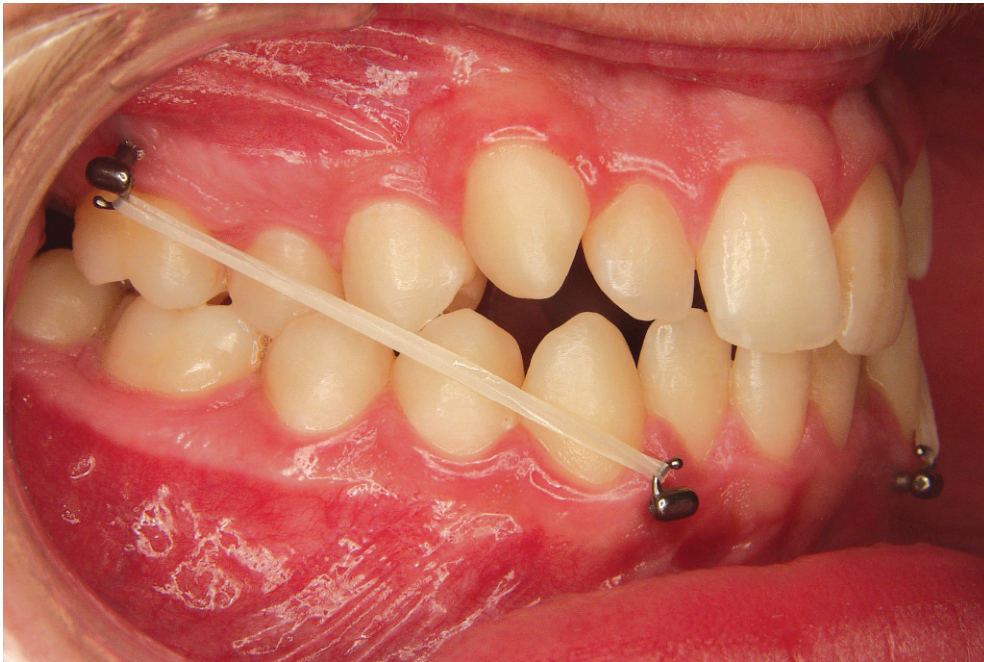


Figure 2. Class III correction achieved with the bone-anchored maxillary protraction (BAMP) orthopedic protocol.

lateral cephalograms²⁵⁻²⁶ with magnification of 7.5% (Dolphin Imaging 10.5, Dolphin Imaging & Management Solutions, Chatsworth, Calif; Figure 1).

Cephalometric records of 34 patients (20 girls, 14 boys) who were treated consecutively with RME/FM therapy were obtained from The Department of Orthodontics and Pediatric Dentistry at the University of Michigan. All cephalograms of adequate quality were available at T1 and within 1 month after RME/FM therapy (T2).

Mean age for the BAMP sample at T1 was 11 years 10 months \pm 1 year 10 months, and at T2 it was 12 years 10 months \pm 1 year 10 months, with a mean treatment duration of 12 months. Mean age for the RME/FM sample at T1 was 8 years 3 months \pm 1 year 10 months, and at T2 it was 9 years \pm 1 year 10 months, with a mean treatment duration of 10 months. The enlargement factor of the cephalograms in the two samples was very similar (about 8%), and no correction was made for enlargement in the analysis of the films.

BAMP Protocol

In each patient, four miniplates were inserted on the left and right infrazygomatic crest of the maxillary buttress and between the lower left and right lateral incisor and canine. Small mucoperiosteal flaps were elevated, and the modified miniplates (Bollard, Tita-Link, Brussels, Belgium) were secured to the bone by two (mandible) or three (maxilla) screws (2.3 mm diameter,

5 mm length). The extensions of the plates perforated the attached gingiva near the mucogingival junction (Figure 2). Three weeks after surgery, the miniplates were loaded. Class III elastics applied an initial force of about 150 g on each side, increased to 200 g after 1 month of traction, and to 250 g after 3 months.

The patients were asked to replace the elastics at least once a day and to wear those 24 hours per day. In 14 patients, after 2 to 3 months of intermaxillary traction, a removable bite plate was inserted in the upper arch to eliminate occlusal interference in the incisor region until correction of the anterior crossbite was obtained. Placement and failure of miniplates as well as patient and surgeon perceptions have been previously described in the literature.²¹

RME/FM Protocol

The three components of the orthopedic face mask therapy used in this study were a maxillary expansion appliance, a face mask, and heavy extraoral elastics.^{16,27-28} Treatment began with the placement of a bonded or banded maxillary expander to which were attached vestibular hooks extending in a superior and anterior direction. Patients were instructed to activate the expander once or twice a day until the desired transverse width was achieved.

Patients were given face masks with pads fitted to the chin and forehead for support immediately after expansion. Elastics were attached from the soldered hooks on the expander to the support bar of the face

mask in a downward and forward vector, producing orthopedic forces of 300 g (first 2 weeks) to 500 g per side. The patients were instructed to wear the face masks for at least 14 hours per day.

Cephalometric Analysis

All cephalograms were digitally traced by two examiners, using the Dolphin 10.5 and Viewbox softwares (Viewbox 3.1, dHal, Kifissia, Greece). The cephalometric measures selected were based on a previously described reference system¹⁵ traced through craniofacial stable structures, with addition of Pg to VertT, the inclination of the incisors to their respective bases, the Wits appraisal, the maxillomandibular differential, and the mandibular angle Co-Go-Me (Figure 3).

Before the cephalometric analysis, 15 lateral cephalograms were traced and measured two times within a week by the same operator (Dr Baccetti). The intraclass correlation coefficients (ICC) indicated excellent intraobserver agreement of the repeated measurements (ICCs varied between 0.966 for the ML-SBL angle and 0.995 for the inclination of the maxillary incisor to NL). Linear measurement errors averaged 0.4 mm (SD 0.8 mm), and angular measurements averaged 0.6° (SD 0.6°).

Statistical Analysis

The homogeneity between the two treatment groups allowed for comparisons without annualizing the data. At exploratory analysis by Shapiro-Wilks test, the data revealed a normal distribution. Therefore, parametric statistics were applied. Significant differences between the cephalometric variables (Mx-Md differential, Wits, NL-ML, ANS-Me, Co-Go-Me, Ovj, Ovb, and molar relation) at T1 in the two treated groups were tested with independent sample *t*-tests. Linear skeletal measures were not compared between the two groups at T1 because of differences in age.

Descriptive statistics were calculated for all measures at T1 and T2 for the two treated groups. T1-T2 changes in both groups and statistical significance of comparisons on the changes between the two groups were assessed with independent sample *t*-tests (SPSS 12.0, SPSS Inc, Chicago, Ill). Statistical significance was tested at $P < .05$, $P < .01$, and $P < .001$. The power of the study was adequate (greater than 0.85), calculated using the mean values and standard deviations of A-VertT,¹⁵ at an alpha of .05, for a clinical detectable difference of 2.5 mm.

RESULTS

The analysis of the dentofacial characteristics in the two treated samples at T1 revealed that there were no

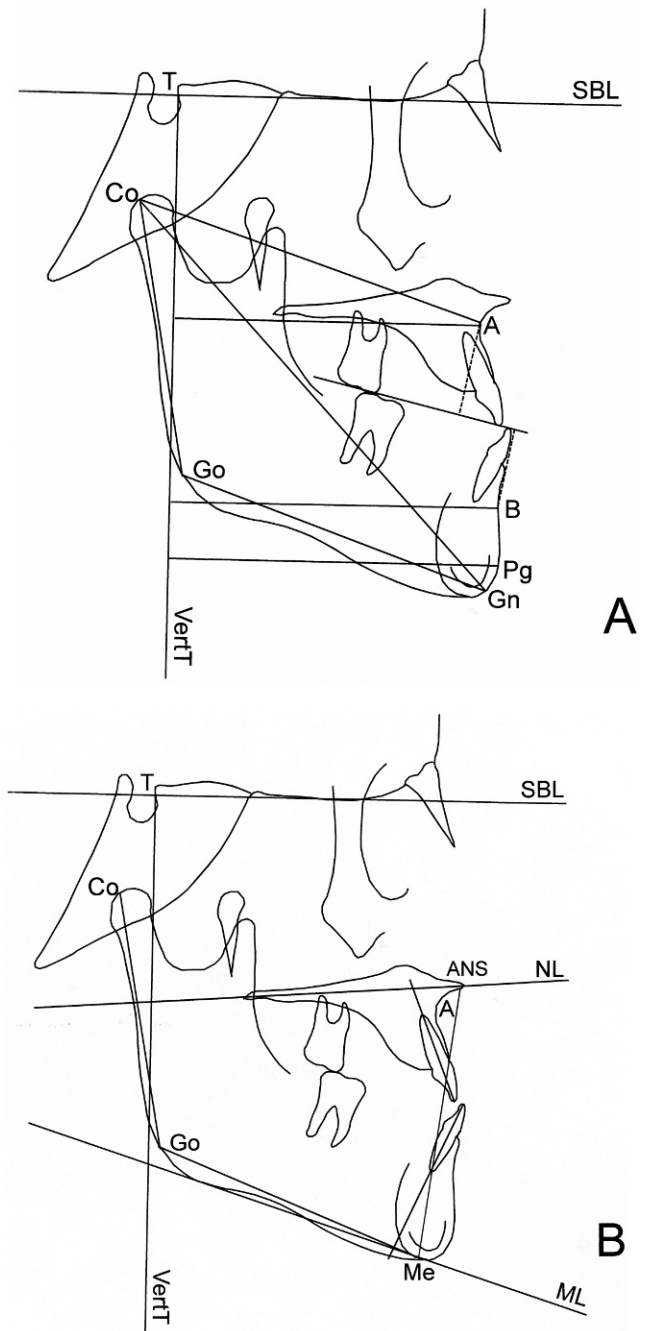


Figure 3. Cephalometric measures. (A) Linear measures. (B) Angular measures.

statistically significant differences between the two groups at T1 for the analyzed parameters.

The changes between T1 and T2 (Table 1) revealed significant differences between the two groups in terms of active treatment effects. In particular, both A-VertT and midfacial length (Co-A) showed an average greater improvement in the BAMP subjects over the RME/FM subjects of 2.3 mm and 2.9 mm, respectively.

Intermaxillary skeletal variables revealed significantly greater improvements in the BAMP group, with

Table 1. Descriptive Statistics for T1–T2 Changes and Comparisons^a

| | BAMP (n = 21) | | RME + FM (n = 34) | | Difference | <i>t</i> | Sig |
|------------------------|---------------|-----|-------------------|------|------------|----------|-----|
| | Mean | SD | Mean | SD | | | |
| A-VertT, mm | 5.2 | 1.9 | 2.9 | 1.3 | +2.3 | 5.33 | *** |
| Co-A, mm | 5.3 | 2.0 | 2.4 | 1.4 | +2.9 | 5.76 | *** |
| B-VertT, mm | −0.6 | 2.0 | −1.2 | 2.6 | +0.6 | 1.77 | NS |
| Pg-VertT, mm | −0.6 | 2.3 | −1.1 | 2.4 | +0.5 | 1.01 | NS |
| Co-Gn, mm | 2.1 | 1.7 | 1.5 | 1.6 | +0.6 | 1.41 | NS |
| Co-Go, mm | 1.7 | 1.2 | 0.6 | 1.2 | +1.1 | 2.31 | * |
| Go-Gn, mm | 1.8 | 1.3 | 0.9 | 1.9 | +0.9 | 1.25 | NS |
| Wits, mm | 5.9 | 2.2 | 3.6 | 1.8 | +2.3 | 4.23 | *** |
| Mx-Md differential, mm | −3.2 | 2.1 | −0.9 | 1.6 | −2.3 | −4.34 | *** |
| ML-SBL, degree | −1.2 | 1.3 | 1.1 | 2.3 | −2.3 | −3.88 | *** |
| NL-SBL, degree | −0.4 | 1.2 | 0.9 | 2.5 | −1.3 | −2.31 | * |
| NL-ML, degree | −0.8 | 1.4 | 2.1 | 2.0 | −2.9 | −5.58 | *** |
| Co-Go-Me, degree | −2.6 | 2.3 | 0.1 | 6.2 | −2.5 | −2.01 | NS |
| ANS-Me, mm | 2.1 | 2.2 | 3.4 | 2.8 | −1.3 | −2.27 | * |
| U1-NL, degree | 0.6 | 3.1 | 0.9 | 10.6 | −0.3 | −0.09 | NS |
| L1-ML, degree | 1.9 | 1.6 | −4.3 | 3.3 | +6.2 | 7.75 | *** |
| Ovj, mm | 3.7 | 1.9 | 4.6 | 1.8 | −0.9 | −1.96 | NS |
| Ovb, mm | 1.4 | 1.8 | 1.1 | 1.9 | +0.3 | 0.02 | NS |
| Molar relation, mm | 4.6 | 1.8 | 3.2 | 1.5 | +1.4 | −3.03 | ** |

^a BAMP indicates bone-anchored maxillary protraction; SD, standard deviation; RME, rapid maxillary expansion; FM, face mask therapy; Sig, significance.

* $P < .01$; ** $P < .001$; *** $P < .0001$. NS indicates not significant.

both an increase in the Wits appraisal and a reduction in the maxillomandibular differential of 2.3 mm.

No significant differences were found in the sagittal position of the mandible in the BAMP group compared with the RME/FM group. However, control of the mandibular vertical growth was statistically significantly different in the two groups. The BAMP group showed a slight closure of the angle between the mandibular line and the stable basicranial line, of the angle between the nasal line and the stable basicranial line, as well as of the angle between the mandibular line and the nasal line. This treatment protocol also resulted in reduced increment in lower anterior facial height, even though there was greater vertical ramal growth in the BAMP group.

In the BAMP group, the molar relationship improved significantly more (1.4 mm), and a significant difference in the amount of proclination was recorded for the lower incisors (6.2° more than the RME/FM group). No other significant differences were found.

DISCUSSION

The present study is the first to compare dentoskeletal changes with RME/FM vs bone anchors for correction of Class III malocclusion. These two protocols for Class III correction differ in point of force application, vectors, frequency, magnitude of force, and timing of treatment. In fact, despite the difference in age at time of initial observation, the comparison

analyzed here considered patients treated with either one of the two protocols who started treatment at the optimal time for that specific protocol, so that the impact of treatment timing would not affect the results negatively. The RME/FM protocol demonstrates the best outcomes in terms of maxillary protraction in the early mixed dentition,^{16,24} whereas the BAMP can be applied more successfully during the late mixed dentition or early permanent dentition (because of the maturation of the maxillary bone and the eruption of the lower canines in the area of the anchors).^{20–23} However, the prepubertal (CS1–CS3) stage of skeletal development of all subjects in the two treatment groups still allowed for a favorable response to therapy in the maxillary structures.^{16,24}

The BAMP protocol (Figure 4) was able to induce a significantly larger short-term response in terms of maxillary advancement and changes in midfacial length compared with the RME/FM protocol. The average difference in favor of the BAMP protocol was about 2.5–3.0 mm. This protraction also was reflected by significant differences in the outcomes of the Wits and maxillomandibular differential (about 2.5 mm greater improvement in the BAMP patients).

Previous studies have indicated that both treatment approaches are able to induce a favorable control of the growth of the mandible, which is a goal for patients with components of mandibular prognathism.^{15,16,23} No differences in terms of sagittal growth or position of the mandible were recorded between the two treatment protocols in this study. As for the vertical component of

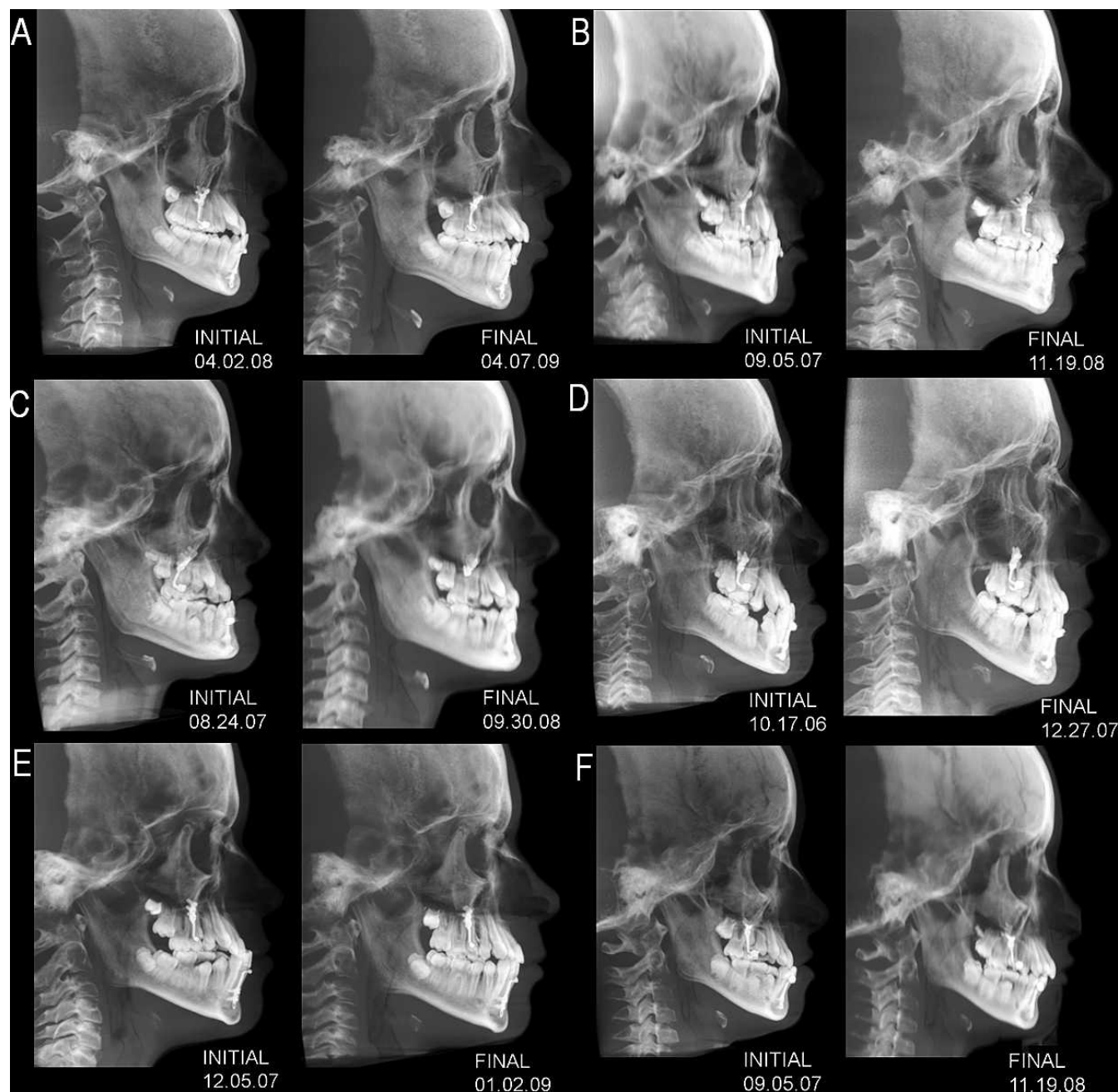


Figure 4. Initial and final cephalograms of 6 of the 21 BAMP patients evaluated in the study.

correction, the BAMP protocol proved to decrease the maxillomandibular divergency slightly (a significant difference of about 3° compared with the RME/FM group). The mandibular line showed significantly different rotation in relation to both the cranial base and the nasal line in the BAMP patients compared with the RME/FM patients (slight counterclockwise rotation with BAMP compared with clockwise rotation with the facial mask). These differences in rotational response of the mandible also may affect the sagittal position of the mandible. A smaller increase in lower anterior

facial height was recorded in the BAMP sample with respect to the RME/FM sample. The slight tendency to an increase in the maxillomandibular divergency in the subjects treated with the face mask could be reduced by inclining the extraoral elastics in a more downward direction during therapy.²⁹

The BAMP group did not show the significant amount of lingual inclination of the lower incisors that was present in the RME/FM group. This favorable outcome probably limited the amount of difference in the overjet change between the two groups, which was

expected to be greater due to the significantly larger maxillary skeletal changes in the BAMP group. The improvement in molar relation, which was not affected by dental inclination, was significantly greater in the BAMP group compared to the RME/FM group.

When comparing the two treatment protocols some clinical aspects deserve to be highlighted. The face mask protocol requires a smaller amount of hours per day during which the appliance is worn. However, the facial mask is more bulky and less easily tolerated than intraoral Class III elastics. On the other hand, the BAMP protocol requires eight surgical interventions, though modest in scope, to apply and then remove the four anchorage plates before and after therapy.²⁰ It also is true that in the BAMP protocol, after maxillary protraction the bone anchors can be used to distalize the upper molars and/or increase space in the maxillary arch if needed during the subsequent fixed orthodontic appliance phase (maxillary permanent canines sometimes present with eruption disturbances in Class III patients).

The later start of treatment in the BAMP protocol also leads to a shorter total treatment time because of a shorter interval between Phase I and Phase II treatments. At the completion of BAMP therapy, the patients are ready to start comprehensive orthodontics. Further, BAMP may allow clinicians to treat patients who had not been seen at an earlier age for orthodontic consultation or for whom facial mask therapy had not been successful.

The results from this study are limited to a short-term observation period immediately after active treatment; long-term studies are needed, both for the appraisal of the stability of BAMP results and to compare these to the outcomes of RME/FM therapy at a postpubertal evaluation.¹⁶

CONCLUSIONS

- The BAMP protocol is able to induce significantly larger maxillary advancement than the RME/FM therapy.
- Mandibular sagittal changes are similar, while vertical changes are better controlled with BAMP.
- Other favorable aspects of BAMP treatment are represented by the lack of clockwise rotation of the mandible and of retroclination of the lower incisors.

REFERENCES

1. Jacobson A, Evans WG, Preston CB, Sadowsky PL. Mandibular prognathism. *Am J Orthod*. 1974;66:140–171.
2. Guyer EC, Ellis EE III, McNamara JA Jr, Behrents RG. Components of Class III malocclusion in juveniles and adolescents. *Angle Orthod*. 1986;56:7–30.
3. Kerr WJ, TenHave TR. Mandibular position in Class III malocclusion. *Br J Orthod*. 1988;15:241–245.
4. Battagel JM. The aetiological factors in Class III malocclusion. *Eur J Orthod*. 1993;15:347–370.
5. De Toffol L, Pavoni C, Baccetti T, Franchi L, Cozza P. Orthopedic treatment outcomes in Class III malocclusion. *Angle Orthod*. 2008;78:561–573.
6. Abu Alhaija ES, Richardson A. Long-term effect of the chin cap on hard and soft tissues. *Eur J Orthod*. 1999;21:291–298.
7. Deguchi T, Kuroda T, Minoshima Y, Graber TM. Craniofacial features of patients with Class III abnormalities: growth-related changes and effects of short-term and long-term chin cup therapy. *Am J Orthod Dentofacial Orthop*. 2002;121:84–92.
8. Battagel JM, Orton HS. A comparative study of the effects of customized facemask therapy or headgear to the lower arch on the developing Class III face. *Eur J Orthod*. 1995;17:467–482.
9. Kilicoglu H, Kirlic Y. Profile changes in patients with Class III malocclusions after Delaire mask therapy. *Am J Orthod Dentofacial Orthop*. 1998;113:453–462.
10. Deguchi T, Kanomi R, Ashizawa Y, Rosenstein SW. Very early face mask therapy in Class III children. *Angle Orthod*. 1999;69:349–355.
11. Yuksel S, Ucem TT, Keykubat A. Early and late facemask therapy. *Eur J Orthod*. 2001;23:559–568.
12. Ucem TT, Ucuncu N, Yuksel S. Comparison of double-plate appliance and facemask therapy in treating Class III malocclusions. *Am J Orthod Dentofacial Orthop*. 2004;126:672–679.
13. Vaughn GA, Mason B, Moon HB, Turley PK. The effects of maxillary protraction therapy with or without rapid palatal expansion: a prospective, randomized clinical trial. *Am J Orthod Dentofacial Orthop*. 2005;128:299–309.
14. Baccetti T, McGill JS, Franchi L, McNamara JA Jr, Tollaro I. Skeletal effects of early treatment of Class III malocclusion with maxillary expansion and face-mask therapy. *Am J Orthod Dentofacial Orthop*. 1998;113:333–343.
15. Baccetti T, Franchi L, McNamara JA Jr. Treatment and posttreatment craniofacial changes after rapid maxillary expansion and facemask therapy. *Am J Orthod Dentofacial Orthop*. 2000;118:404–413.
16. Westwood PV, McNamara JA Jr, Baccetti T, Franchi L, Sarver DM. Long-term effects of Class III treatment with rapid maxillary expansion and facemask therapy followed by fixed appliances. *Am J Orthod Dentofacial Orthop*. 2003;123:306–320.
17. Cozza P, Marino A, Mucedero M. An orthopedic approach to the treatment of Class III malocclusions in the early mixed dentition. *Eur J Orthod*. 2004;26:191–199.
18. Baik HS, Jee SH, Lee KJ, Oh TK. Treatment effects of Frankel functional regulator III in children with Class III malocclusions. *Am J Orthod Dentofacial Orthop*. 2004;125:294–301.
19. Kajiyama K, Murakami T, Suzuki A. Comparison of orthodontic and orthopedic effects of a modified maxillary protractor between deciduous and early mixed dentitions. *Am J Orthod Dentofacial Orthop*. 2004;126:23–32.
20. Cornelis MA, Scheffler NR, Mahy P, Siciliano S, De Clerck HJ, Tulloch JF. Modified miniplates for temporary skeletal anchorage in orthodontics: placement and removal surgeries. *J Oral Maxillofac Surg*. 2008;66:1439–1445.
21. Heymann GC, Cevidanes L, Cornelius M, De Clerck H, Tulloch JFC. 3D analysis of maxillary protraction using intermaxillary elastics to miniplates. *Am J Orthod Dentofacial Orthop*. In press.

22. De Clerck HJ, Cornelis MA, Cevidanes LH, Heymann GC, Tulloch CJ. Orthopedic traction of the maxilla with mini-plates: a new perspective for treatment of midface deficiency. *J Oral Maxillofac Surg.* 2009;67:2123–2129.
23. De Clerck H, Cevidanes L, Baccetti T. Dentofacial effects of bone-anchored maxillary protraction: a controlled study on consecutively treated Class III patients. *Am J Orthod Dentofacial Orthop.* In press.
24. Baccetti T, Franchi L, McNamara JA Jr. The cervical vertebral maturation (CVM method for the assessment of optimal treatment timing in dentofacial orthopedics. *Semin Orthod.* 2005;11:119–129.
25. Ludlow JB, Gubler M, Cevidanes LHS, Mol A. Precision of cephalometric landmark identification: CBCT vs conventional cephalometric views. *Am J Orthod Dentofac Orthop.* 2009;136:312.e1–312.e10.
26. Cevidanes L, Oliveira AE, Motta A, Phillips C, Burke B, Tyndall D. Head orientation in CBCT-generated cephalograms. *Angle Orthod.* 2009;79:971–977.
27. McNamara JA Jr. An orthopedic approach to the treatment of Class III malocclusion in young patients. *J Clin Orthod.* 1987;21:598–608.
28. McNamara JA Jr, Brudon WL. *Orthodontics and Dentofacial Orthopedics.* Ann Arbor, Mich: Needham Press; 2001.
29. Gautam P, Valiathan A, Adhikari R. Skeletal response to maxillary protraction with and without maxillary expansion: a finite element study. *Am J Orthod Dentofacial Orthop.* 2009; 135:723–728.