

Case Report

Maxillary ulceration resulting from using a rapid maxillary expander in a diabetic patient

Luiz Guilherme Martins Maia^a; André da Costa Monini^a; Helder Baldi Jacob^a;
Luiz Gonzaga Gandini Jr^b

ABSTRACT One of the characteristics of diabetes mellitus is the exaggerated inflammatory response. The present report shows the reaction from the use of a rapid maxillary expander in a diabetic patient. A 9-year-old child presented an uncommon reaction to the treatment with a rapid maxillary expander, and on follow-up examination, it was discovered that the patient had diabetes mellitus. After controlling the disease, the proposed treatment was used without further incidents. The case calls attention to the presence of uncommon responses to treatment and the need for the orthodontist to suspect a patient's systemic compromise. (*Angle Orthod.* 2011;81:546–550.)

KEY WORDS: Rapid maxillary expansion; Diabetes

INTRODUCTION

Several systemic diseases manifest in oral cavity, one such disease is diabetes mellitus (DM). When the patient does not know of the existence of the disease or the professional does not recognize the signs of the disease in the oral cavity, oral treatment can become complicated.

DM is one of these systemic diseases with buccal manifestations. It is a chronic disease characterized by partial or total deficiency in the production of insulin or a resistance to its action. This deficiency of resistance leads to the abnormality of glucose, protein, and lipid metabolisms resulting in hyperglycemia, thus inducing several systemic abnormalities.^{1–6} Diabetes mellitus is classified as type 1 when there is insulin deficiency, or type 2 when there is a greater resistance to the insulin action.⁷ Usually, type 1 affects children, destroying pancreatic beta cells and leading to an absolute insulin deficiency, while type 2 mostly affects adults older than

40 years and is frequently associated with overweight and with obesity.^{2,3,8,9}

DM buccal manifestations include periodontal and dental tissue infections, salivary gland dysfunction, and greater susceptibility to viral and fungal infections.^{6,9–12} The production of less saliva results in greater susceptibility to mucositis, peeling, and ulcerations.⁶ This report presents the complications of treatment with a Hass rapid maxillary expander (RME) in a patient with diabetes mellitus.

Case Presentation

A 9-year-old girl was taken by her parents to one of the authors for orthodontic assessment and treatment. She presented a Class I malocclusion and a superior arch tending to an atresic shape. She still presented several chronic cavities just on the enamel and did not require any restorative treatment (Figure 1). Radiographic examination did not show any abnormality. The proposed treatment plan was to make the arch shape adequate using a rapid maxillary expander and fixed braces later, after dental exchanges. On history taking the patient described prostration, weakness, physical fatigue, feeling hungry all the time, and no physical activities; physical examination showed the child was overweight. The first molars were separated and bandaged to build a Haas RME. The maxillary expander was cemented. The parents were instructed to perform a quarter-turn activation in the morning and another in the afternoon for 1 week, after which they were asked to return for a new appointment. Four days after cementing the RME, the child returned for reassessment complaining of maxillary discomfort,

^a PhD student, Faculdade de Odontologia de Araraquara, Universidade Estadual Paulista, UNESP, Araraquara, São Paulo, Brazil.

^b Professor, Faculdade de Odontologia de Araraquara, Universidade Estadual Paulista, UNESP, Araraquara, São Paulo, Brazil; Adjunct Clinical Professor, Baylor College of Dentistry, Dallas, Tex, and Saint Louis University, St Louis, Mo.

Corresponding author: Dr Luiz Gonzaga Gandini Jr, Av Casemiro Perez, 560, Vila Harmonia, Araraquara, São Paulo, Brazil, CEP 14802-600 (e-mail: luizgandini@uol.com.br)

Accepted: September 2010. Submitted: March 2010.

Published Online: January 24, 2011

© 2011 by The EH Angle Education and Research Foundation, Inc.

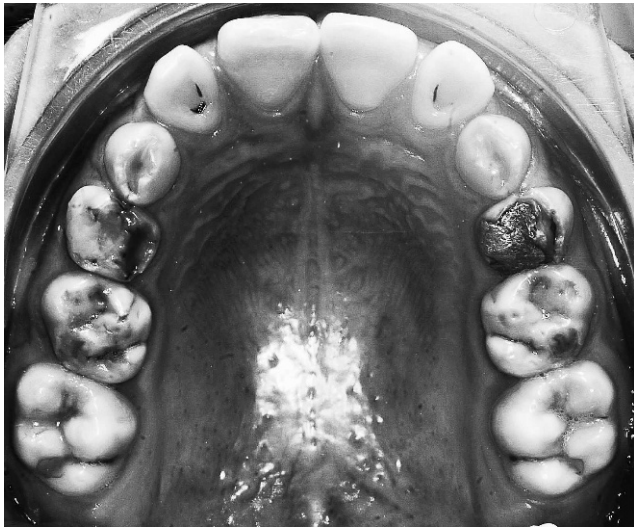


Figure 1. Upper pretreatment occlusal picture.

bleeding, light and localized continuous pain which had started that day. The child took no medication until returning for reassessment. Examination revealed necrotic ulceration, hemorrhagic aspect with rectangular shape from the first permanent molar through the first primary molar. The clinical exam showed a detachable membrane under the pilling action on both the sides of the palate under the acrylic, especially on the left side, and extensive inflammation of the entire palate with partial redraping of the acrylic part by the mucus (Figures 2 and 3). Subsequently, the appliance was removed, and the sore was cleaned with a saline-solution rinse. The child was monitored every 3 days to assess ulcer regression, and 15 days after the removal of the maxillary expander, there were still remnants of the ulcer (Figure 4). Considering the aggressiveness of the inflammatory response, the extension of the

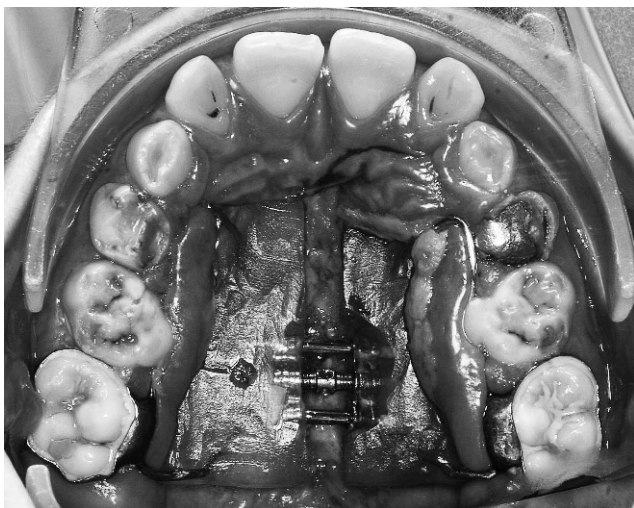


Figure 2. Upper occlusal picture after 1 week of treatment with the rapid maxillary expander.

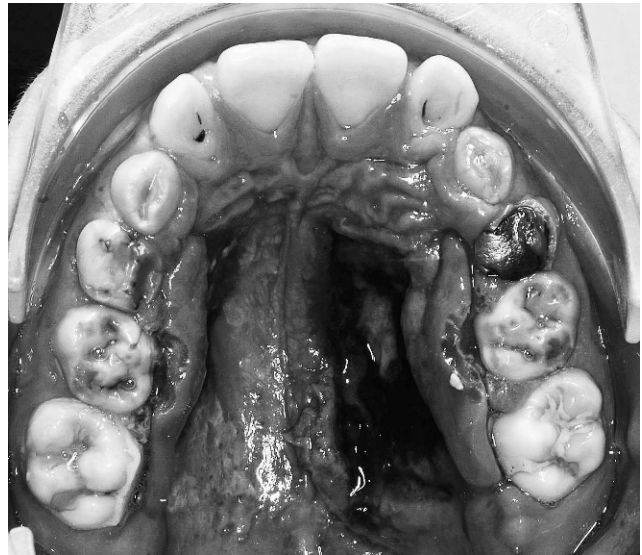


Figure 3. Upper occlusal picture after 1 week of treatment and the removal of the maxillary expander.

ulceration, and prolonged healing, some systemic problem was suspected. The patient was referred for medical assessment, and the exams showed the patient had type 1 diabetes mellitus (DM). Blood studies showed glycosylated hemoglobin (A1c), 10%; preprandial plasma glucose concentration, 120 mg/dL; and postprandial glucose concentration, 171 mg/dL. After confirming diabetes, the mother informed that she was also diabetic. Besides her, nobody in the family had any similar history. The patient began treatment with daily insulin doses, and after 3 months of controlling the glycemia levels, her orthodontic treatment was resumed. Follow-up blood studies after

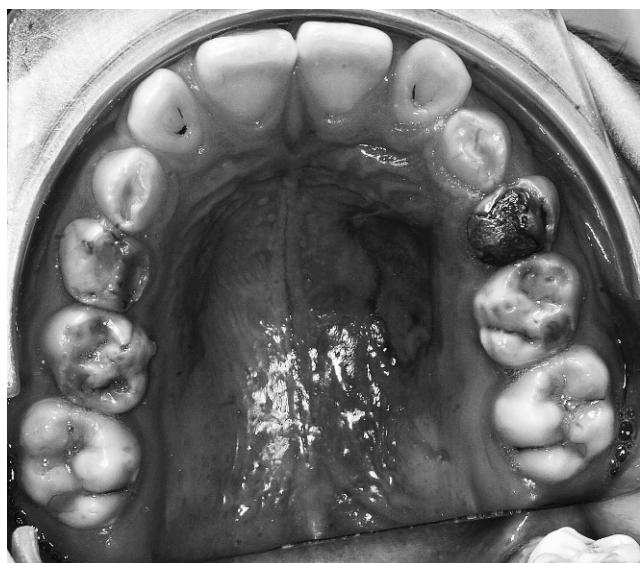


Figure 4. Regression of the lesion 15 days after the removal of the maxillary expander.

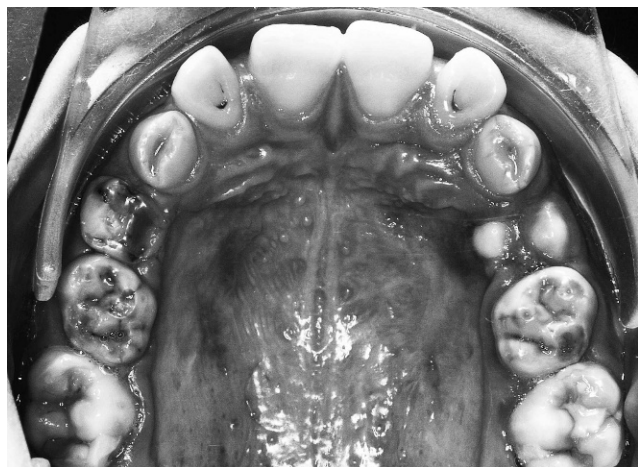


Figure 5. Retention phase of the second attempt with the maxillary expander performed after controlling the diabetes mellitus. Note the aspect of normality of the treatment.

3 months showed hemoglobin A1c, 5%; preprandial plasma glucose concentration, 89.3 mg/dL; and postprandial glucose concentration, 131 mg/dL. A new RME was built, and the same treatment plan was carried out, this time without further incidents (Figure 5).

DISCUSSION

Hyperglycemia modifies metabolic balance, promoting several alterations in vascular tissues and causing peripheral vascular failure, reduced neutrophil efficiency,¹³ increased connective and bone-tissue destruction, vascular damage, and an exacerbated production of inflammatory mediators.^{1,2,5,6,13} This deficient immune response hinders the elimination of pathogenic microorganisms, thus perpetuating and exacerbating the inflammatory process that, when reaching each organ in the body, results in other diabetic complications such as neuropathies, retinopathy, nephropathy, accelerated arteriosclerosis with myocardial infarction and coronary diseases.^{1-3,6,8,13}

In the mouth, the synergy of these factors leads to progressive and increased severity of periodontal disease.^{5,14} Periodontal tissues are the oral structures most affected by DM.^{1,4,6,13} In the initial phase, there is predominance of gingivitis and periodontitis. If not detected at an early stage, these problems can evolve to advanced periodontal disease.^{5,6,15} Considering that microbiota in DM patients is similar to that of nondiabetic patients,¹⁶ hyperglycemia and exaggerated inflammatory response of the host in the presence of oral infections seem to be responsible for the greater prevalence of periodontal destruction in diabetic patients.^{2,4,5,13} The main alterations found in the saliva are reduced production and altered composition,

especially those related to increased glucose, total sugars, total proteins, and α -amylase levels.¹⁷ This disturbance is frequent and can cause ulcers, cheilitis, and fissured tongue.² The greater amount of glucose in the saliva and crevicular gingival fluid stimulates bacterial growth, reduces the fibroblast capacity to promote healing, and increases the production of lactic acid. Glucose also reduces the pH and saliva's buffer activity, which are risk factors for caries and periodontal diseases,^{1,2,6,17} leading DM to a vicious circle in which it exacerbates oral diseases that hinder its control.^{4,6,13,14,18}

Patients with type 1 DM are those who present greater susceptibility to microvascular alterations.⁸ Studies related to dental movement and diabetes show that the disease promotes retarded osseous regeneration,¹⁹ weakening of the periodontal ligament,¹⁹ microangiopathies in the gingival area,^{19,20} and larger and more severe bone gaps on the alveolar walls.²⁰ The reduced new-bone formation capacity is owing to the apoptosis of fibroblastic and osteoblastic cells in diabetic individuals.³ Case reports have been published on life-threatening deep neck infections from periodontal abscess²¹ and fatal maxillary ulcers in patients with DM.²² In the latter, the ulcers were not superficial but represented deep granulomatous disease. However, the extent to which such incidents are a part of the broader spectrum of infection in people with diabetes has not yet been established and shows the importance of the diagnosis of the disease. The presented case clearly illustrates several complications of DM, such as the high susceptibility to infection, connective tissue destruction, microvascular alterations, and difficulties in healing and exaggerated inflammatory response.

Dentists play an important role in identifying patients who may have diabetes mellitus by recognizing oral manifestations of the disease and systemic signs and symptoms.^{2,4,6,9,10,18} The oral cavity may show the first signs or symptoms of an undiagnosed or poorly controlled diabetic condition.^{2,10,12,18} Other findings characteristic of DM are accelerated tooth eruption until 10 years of age, greater gingival bleeding²³ when probing and a higher prevalence of caries.¹¹ Type 1 diabetes develops when the patient is still a child, usually diagnosed only at the end of adolescence,⁸ and can affect the patient's skeletal maturation because diabetic patients have less skeletal maturation when compared with normal patients.^{24,25}

Glycemic control in DM management is a key to reducing the impact of acute oral infections and microvascular complications,^{2,5,6,8,9,14,25} and for diabetes patients under good medical control, all dental procedures can be performed.^{2,6,10,13} A diabetes control and complications trial study revealed that long-term

complications can be reduced by 54% to 76% if DM is managed properly,²⁶ and systemic and oral complications are more likely the longer the disease lasts and remains out of control.⁵

Orthodontic treatment should be avoided in patients with poorly controlled type 1 DM because these individuals are particularly susceptible to periodontal breakdown.^{10,27} There is more gingival inflammation even in well-controlled diabetic patients, probably owing to the impaired neutrophil function.^{2,27} Prior to commencing treatment, patients should be informed about the greater propensity for gingival inflammation when fixed appliances are planned. Therefore, it is important to maintain good oral hygiene to prevent periodontal breakdown progression, especially in type 1 diabetes patients, and such attention with hygiene should be maintained throughout the entire treatment.^{2,10,12,27} Once the disease is under control, orthodontic treatment can resume. However, in our case, a tooth-borne expander could have been used instead of a Haas appliance, only to have an additional care.

Early morning appointments are preferable.^{2,6,13} If a patient is scheduled for a long treatment session (ie, longer than 1½ hours), the patient should be advised to eat his/her usual meal and take his/her medication as usual.^{2,10,13} Before the dental procedure starts, the dental team should check whether the patient has complied with these recommendations or not.^{2,10} In this way, a hypoglycemic reaction in the office can readily be avoided.^{2,10}

A screening protocol should be a search regarding polyuria, polydipsia, polyphagia, weight loss, recurrent infection, retinopathy, neuropathy, nephropathy, angiopathy, acetone breath, xerostomia, oral candidiasis, burning mouth or tongue, impaired wound healing, recurrent oral infections, and severe gingivitis.^{4,6,8,9,12,13} These signs and symptoms could be observed when the disease has been present for a long time. The presented case did not show all these characteristics initially, but the results of treatment suggested diabetes as the underlying problem. This case report calls attention to the concerns one should have with clinical signs that exceed what is usually expected for the detection or suspicion of systemic diseases. Moreover, it is necessary to follow these patients more closely, including radiographic-control exams and greater attention to the periodontal response than the mechanical principles throughout the entire treatment.²⁸

CONCLUSIONS

This case shows the importance of targeted anamnesis in the beginning of the treatment, the conse-

quences of an orthodontic treatment in an uncontrolled diabetic patient, and the role of the dentist in the detection of signs and symptoms of diabetes to refer the patient for medical treatment.

REFERENCES

1. Alves C, Andion J, Brandão M, Menezes R. Mecanismos patogênicos da doença periodontal associada ao diabetes melito. *Arq Bras Endocrinol Metabol.* 2007;51:1050–1057.
2. Bensch L, Braem M, Willems G. Orthodontic considerations in the diabetic patient. *Semin Orthod.* 2004;10:252–258.
3. Graves DT, Liu R, Alikhani M, Al-Mashat H, Trackman PC. Diabetes-enhanced inflammation and apoptosis—impact on periodontal pathology. *J Dent Res.* 2006;85:15–21.
4. Lamster IB, Lalla E, Borgnakke WS, Taylor GW. The relationship between oral health and diabetes mellitus. *J Am Dent Assoc.* 2008;139:19S–24S.
5. Ryan ME, Carnu O, Kamer A. The influence of diabetes on the periodontal tissues. *J Am Dent Assoc.* 2003;134:34S–40S.
6. Vernillo AT. Dental considerations for the treatment of patients with diabetes mellitus. *J Am Dent Assoc.* 2003;134:24S–33S.
7. American Diabetes Association. Diagnosis and classification of diabetes mellitus. *Diabetes Care.* 2008;31:S55–S60.
8. Kidambi S, Patel SB. Diabetes mellitus: considerations for dentistry. *J Am Dent Assoc.* 2008;139:8S–18S.
9. Robertson C, Drexler AJ, Vernillo AT. Update on diabetes diagnosis and management. *J Am Dent Assoc.* 2003;134:16S–23S.
10. Bensch L, Braem M, Van Acker K, Willems G. Orthodontic treatment considerations in patients with diabetes mellitus. *Am J Orthod Dentofacial Orthop.* 2003;123:74–78.
11. Orbak R, Simsek S, Orbak Z, Kavrut F, Colak M. The influence of type-1 diabetes mellitus on dentition and oral health in children and adolescents. *Yonsei Med J.* 2008;49:357–365.
12. Ship JA. Diabetes and oral health: an overview. *J Am Dent Assoc.* 2003;134:4S–10S.
13. Mealey B. Diabetes and periodontal diseases. *J Periodontol.* 1999;70:935–949.
14. Taylor GW, Borgnakke WS. Periodontal disease: associations with diabetes, glycemic control and complications. *Oral Dis.* 2008;14:191–203.
15. Lalla E, Cheng B, Lal S, Tucker S, Greenberg E, Goland R, Lamster IB. Periodontal changes in children and adolescents with diabetes: a case-control study. *Diabetes Care.* 2006;29:295–299.
16. Lalla E, Kaplan S, Chang SM, Roth GA, Celenti R, Hinckley K, Greenberg E, Papapanou PN. Periodontal infection profiles in type 1 diabetes. *J Clin Periodontol.* 2006;33:855–862.
17. Lopez ME, Colloca ME, Paez RG, Schallmach JN, Koss MA, Chervonagura A. Salivary characteristics of diabetic children. *Braz Dent J.* 2003;14:26–31.
18. Mealey BL. The interactions between physicians and dentists in managing the care of patients with diabetes mellitus. *J Am Dent Assoc.* 2008;139:4S–7S.
19. Holtgrave EA, Donath K. Periodontal reactions to orthodontic forces in the diabetic metabolic state [in German]. *Fortschr Kieferorthop.* 1989;50:326–337.
20. Real LASV, Ramos AL, Zanoni JN. Modificações no periodonto de ratos diabéticos após a movimentação

- ortodôntica. *R Dental Press Ortodon Ortop Facial*. 2009;14:124–131.
21. Harrison GA, Schultz TA, Schaberg SJ. Deep neck infection complicated by diabetes mellitus. Report of a case. *Oral Surg Oral Med Oral Pathol*. 1983;55:133–137.
 22. Van der Westhuijzen AJ, Grotepass FW, Wyma G, Padayachee A. A rapidly fatal palatal ulcer: rhinocerebral mucormycosis. *Oral Surg Oral Med Oral Pathol*. 1989;68:32–36.
 23. Lal S, Cheng B, Kaplan S, Softness B, Greenberg E, Goland RS, Lalla E, Lamster IB. Accelerated tooth eruption in children with diabetes mellitus. *Pediatrics*. 2008;121:e1139–e1143.
 24. El-Bialy T, Aboul-Azm SF, El-Sakhawy M. Study of craniofacial morphology and skeletal maturation in juvenile diabetics (Type I). *Am J Orthod Dentofacial Orthop*. 2000;118:189–195.
 25. Silverstein J, Klingensmith G, Copeland K, et al. Care of children and adolescents with type 1 diabetes: a statement of the American Diabetes Association. *Diabetes Care*. 2005;28:186–212.
 26. The effect of intensive treatment of diabetes on the development and progression of long-term complications in insulin-dependent diabetes mellitus. The Diabetes Control and Complications Trial Research Group. *N Engl J Med*. 1993;329:977–986.
 27. Burden D, Mullally B, Sandler J. Orthodontic treatment of patients with medical disorders. *Eur J Orthod*. 2001;23:363–372.
 28. Davidovitch Z, Krishnan V. Role of basic biological sciences in clinical orthodontics: a case series. *Am J Orthod Dentofacial Orthop*. 2009;135:222–231.