

Maxillary arch changes with transpalatal arch treatment followed by full fixed appliances

Gaetana Raucci^a; Camila Pachêco-Pereira^b; Vincenzo Grassia^c; Fabrizia d'Apuzzo^c; Carlos Flores-Mir^d; Letizia Perillo^e

ABSTRACT

Objective: To evaluate short- and long-term maxillary dental arch dimensional changes in patients treated with a transpalatal arch (TPA) during mixed dentition followed by full fixed appliances in the permanent dentition compared with an untreated sample.

Materials and Methods: Dental casts and lateral cephalograms obtained from 36 consecutively treated patients before TPA treatment (T₀), after TPA treatment (T₁), after fixed appliance treatment (T₂), and a minimum of 3 years after fixed appliance treatment (T₃) were analyzed. The control group was matched as closely as possible. Arch widths, perimeter, and length, as well as crowding and incisor proclination, were evaluated.

Results: In the treated group, intercanine, interpremolar, and intermolar widths and arch perimeter increased significantly at T₁. At T₂, only the intercanine width increase was still significant. At T₃ all arch dimensions decreased, remaining larger than they were at T₀. The arch length increased after T₁, significantly decreased at T₂, and slightly decreased at T₃. The crowding decreased significantly at T₁, was eliminated at T₂, and increased at T₃. At T₃, 50% of the patients showed relapse with crowding ranging from 0.5 to 2 mm. In the control group at T₁, only slight changes were noted but crowding increased. At T₂, crowding and upper incisor inclination increased but arch length decreased. At T₃, intercuspisid width, arch perimeter, and arch length continued to decrease, thereby increasing crowding.

Conclusion: Maxillary dental arch dimensions changed significantly after TPA followed by treatment with fixed appliances. Relapse occurred to some extent, especially in intercanine width and arch perimeter, but most of the dental arch changes remained stable. (*Angle Orthod.* 2015;85:683–689.)

KEY WORDS: TPA; Dental arch dimensions; Long term; Untreated sample; Mixed dentition; Transpalatal arch

^a Postgraduate Orthodontic student, Multidisciplinary Department of Medical-Surgical and Dental Specialties, Second University of Naples, Italy, Naples, Italy.

^b MSc student, Department of Dentistry, University of Alberta, Edmonton, Alberta, Canada.

^c PhD student, Multidisciplinary Department of Medical-Surgical and Dental Specialties, Second University of Naples, Naples, Italy.

^d Associate Professor and Head of Orthodontic Division, Department of Dentistry, University of Alberta, Edmonton, Alberta, Canada.

^e Associate Professor, Head of Orthodontic Division and Post Graduate Program, Multidisciplinary Department of Medical-Surgical and Dental Specialties, Second University of Naples, Italy, Naples, Italy.

Corresponding author: Dr Letizia Perillo, Head of Orthodontic Division and Post Graduate Program, Multidisciplinary Department of Medical-Surgical and Dental Specialties, Second University of Naples, Naples, Italy
(e-mail: letizia.perillo@tin.it)

Accepted: August 2014. Submitted: July 2014.

Published Online: October 6, 2014

© 2015 by The EH Angle Education and Research Foundation, Inc.

INTRODUCTION

In patients with moderate crowding (4 to 8 mm), the choice between dental arch expansion or teeth extraction is controversial.^{1–3} A nonextraction treatment is often initiated in patients with mild to moderate crowding who could benefit from increased lip support.⁴ When analyzing dental arch changes in non-extraction patients, there is great variability; some have reported an increase in dental arch measurements, and others have reported a decrease.^{5–7} To further complicate the situation, dental arch changes produced during orthodontic treatment tended to relapse toward pretreatment values after retention is discontinued.^{8–10} Posttreatment dental arch instability is one of the main disadvantages of nonextraction treatment approaches.¹¹ It has been argued that even small dental arch expansion may cause an increase in cheek or lip pressure that potentially pushes teeth back to the original positions unless actively retained.¹²

One of the available orthodontic appliances to relieve crowding through dental arch expansion is the transpalatal arch (TPA). The TPA is primarily used to produce molar derotation along with mild transversal dental expansion, thus inducing both increased arch width and perimeter.¹³ These combined effects make the TPA a treatment option in Class I and Class II malocclusions with mild to moderate crowding and concomitant molar rotations. In Class II malocclusions, maxillary first molars are often rotated with the mesiobuccal cusp displaced in a palatal direction.¹⁴ As a consequence, these molars occupy more dental arch space because of their trapezoidal shape. Their derotation may therefore add dental arch perimeter.^{15–20} Although molar derotation can provide an arch perimeter gain of up to 2.1 mm anterior to the molar,¹⁸ this space gain is unpredictable.¹⁴ Additionally, during molar derotation, transeptal fibers could potentially move deciduous molars or premolars buccally, potentially offering further increases in dental arch width and perimeter.^{13,14} The long-term stability of these changes remains controversial.

Based on this background information two important unanswered questions remain: Does TPA treatment induce changes in maxillary dental arch dimensions and are these changes stable over time? Therefore the purpose of this retrospective clinical study was to evaluate short- and long-term maxillary dental arch changes in patients treated with a TPA in mixed dentition followed by fixed appliances in permanent dentition. A nontreated control group was used to factor out normal dentoalveolar changes.

MATERIALS AND METHODS

Appropriate ethical approval was secured by the Health Research Ethics Board of University of Alberta (Pro00044194), by Burlington Growth Center, University of Toronto, in November 14, 2013, and by the Health Research Ethics Board of the Second University of Naples (No. 12554), in November 26, 2013. Diagnostic records from consecutive patients treated between 1995 and 2007 with a TPA followed by full fixed appliances were gathered from a private orthodontic practice in Naples, Italy (L.P.).

Inclusion criteria were as follows:

- Class I or II malocclusions
- Mild to moderate maxillary crowding
- Mixed dentition
- ≤ 9 years old before treatment started
- Cervical vertebral maturation stage²¹ of 1 or 2 at the start of treatment
- Dental casts and lateral cephalogram at four time points: before TPA treatment (T_0), after TPA treatment (T_1), after fixed appliance treatment (T_2),

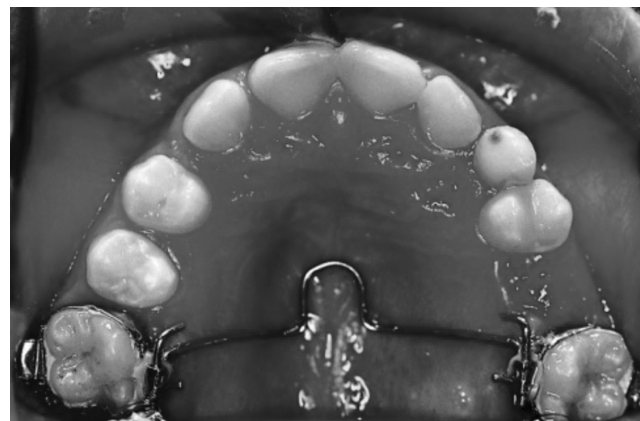


Figure 1. Transpalatal arch applied to the first molars.

and a minimum of 3 years after fixed appliance treatment (T_3)

- No clinically noticeable dentoskeletal crossbites

Patients with previous orthodontic treatment, skeletal posterior crossbite, craniofacial anomalies, and extraction treatment were excluded.

Of the identified 102 potential patients, only 47 met the inclusion criteria. Of those only 36 agreed to come in for follow-up and were the patients evaluated in this study. Thus, the final treated sample consisted of 14 boys and 22 girls.

The control sample, derived from the Burlington Growth Center in Toronto, Canada, consisted of 10 boys and 10 girls closely matched to the treatment group for age, cervical vertebral maturation, sex, and observation periods. The inclusion criteria were similar except that no treatment was provided.

Treatment Protocol

All patients had a two-phase active treatment. The first phase (T_0 – T_1) lasted about 2 years. Each patient was treated with a TPA to gain maxillary dental arch dimensions and, when needed, to improve the molar relationship. A prefabricated TPA (GAC International Inc, Central Islip, NY) was made of 0.036-inch stainless steel wire with a mesially directed loop in the middle (Figure 1).

The TPA was passively inserted at the first visit. Activation for molar derotation was performed with an additional 1-mm expansion at the second visit. This first phase included waiting for eruption of remaining permanent teeth. During this time the TPA remained passively in place.

The eruption of all permanent teeth (except second and third molars) marked the beginning of the second phase (T_1 – T_2). A nonextraction treatment with standard edgewise fixed appliances (0.022×0.028 ") was executed for at least 2 years to correct residual

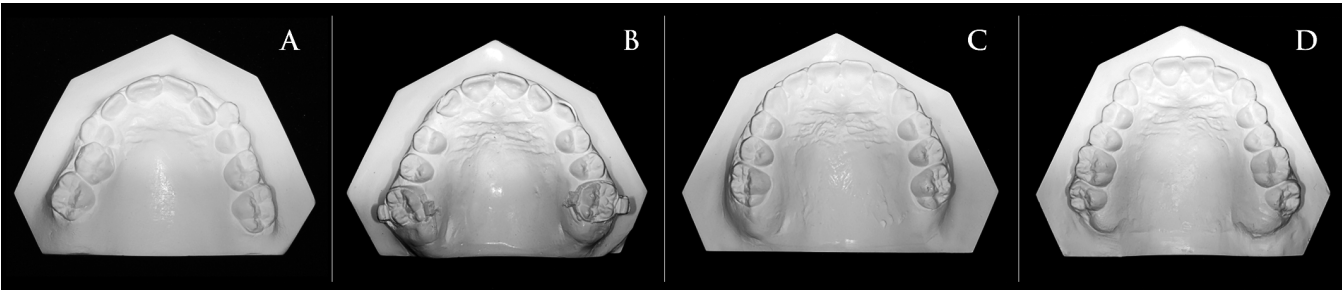


Figure 2. Upper dental casts at the four time periods. (A) Before treatment. (B) After transpalatal arch treatment. (C) After fixed appliance treatment. (D) At follow-up.

crowding and to detail the occlusion. During this phase, the TPA was left passively in place.

The third phase (T_2 – T_3) consisted of a follow-up evaluation for at least 3 years after the end of active orthodontic treatment. This phase included a period of passive retention that lasted roughly 2 years, during which patients wore a Hawley retainer in the maxillary dental arch.

Dental Cast Measurements

A black 2H pencil with a 0.5-mm tip was used to mark the anatomic landmarks on the maxillary dental casts at the four time periods (Figure 2). Measurements were completed with digital calipers. Lingual points on the gingival margin of the deciduous or permanent canines, first deciduous molar or premolar, and first molar were taken to calculate the intercanine, interpremolar and intermolar width measurements²² (Figure 3). The perpendicular distance from the most facial point on the most prominent central incisor to a line constructed between contact points mesial to the permanent first molars was taken to measure arch length²² (Figure 4).

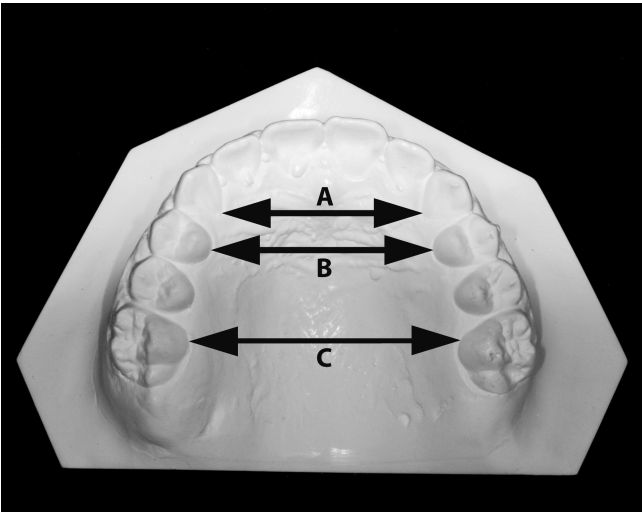


Figure 3. Arch width measurements. (A) intercanine width. (B) interpremolar width. (C) intermolar width.

Points on the mesial aspect of the permanent first molars, on the distal side of the canines and central incisors, were taken to measure the arch perimeter²² (Figure 5). Unerupted teeth were represented by a point halfway between the adjacent permanent teeth centered buccolingually on the alveolar process.

Crowding was evaluated as tooth-size/arch-length discrepancy. Any crowding (>0 mm) at the end of follow-up observation (T_3) in the treatment group was considered relapse. The four casts of each patient were marked consecutively to ensure that the locations of all the landmarks were as identical as possible at each time period.

Cephalometric Analysis

Only maxillary incisor inclination (U1 to palatal plane) was considered for the analysis.

Statistical Analysis

For continuous variables, means and standard deviations were calculated. A one-way analysis of

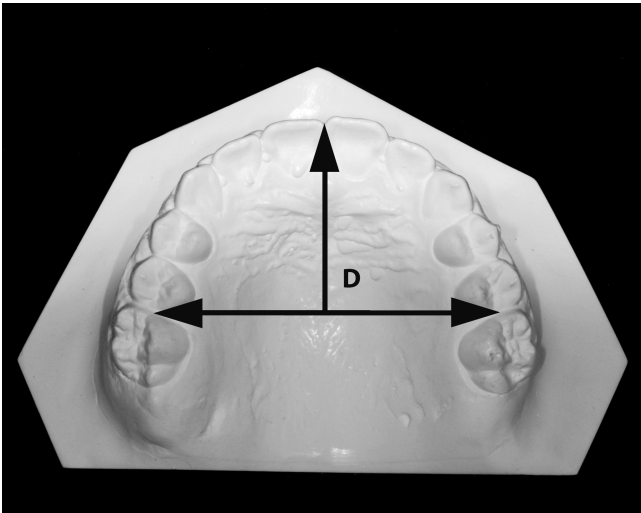


Figure 4. Arch length measurement (D) as the perpendicular distance from the most facial point on the most prominent central incisor to a line constructed between contact points mesial to the permanent first molars.

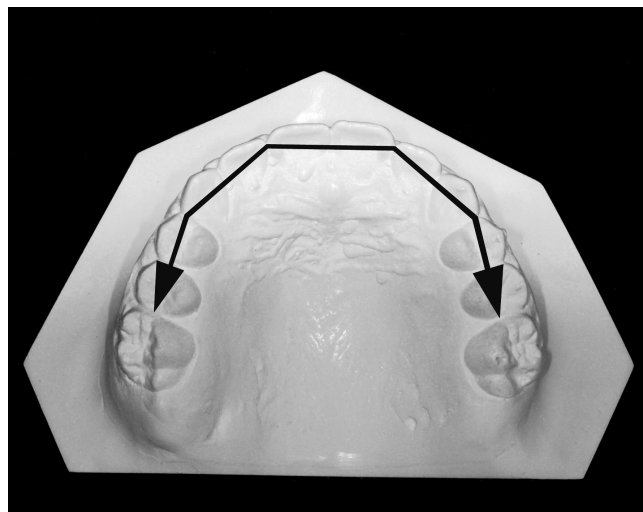


Figure 5. Arch perimeter measurement as the sum of the segment lengths connecting contact points mesial to the permanent first molars.

variance was used to determine the influence of group, sex, and their interaction. Comparison of continuous variables between groups was made through unpaired *t*-tests, while changes within groups were tested through paired *t*-tests.

For categorical variables, absolute numbers were reported. Categorical variables were compared with χ^2 . The level of statistical significance set at $P < .05$ for all statistical tests.

RESULTS

The standard error for each measurement, calculated by Dahlberg's formula, is reported in Table 1. All values can be considered very low, not likely clinically significant.

Characteristics of the treated and untreated groups at baseline as well as the significance of their differences are reported in Table 2. No statistical differences were identified, except for crowding (1.8 mm more in the treated group; $P < .001$) and interpremolar width (1.4 mm more in the control group; $P = .015$).

Table 1. Error of Method Values

Variables (all mm except U1/PP in degrees)	T	C
Intercuspid width	0.14	0.19
Interpremolar width	0.12	0.12
Intermolar width	0.17	0.15
Perimeter	0.18	0.08
Length	0.13	0.17
Crowding	0.16	0.03
U1/PP°	0.04	0.06

Table 2. Comparison of Maxillary Dental Arch Measurements at Baseline (T_0)

Variables (mm)	Treated		Untreated		<i>P</i>
	Mean	SD	Mean	SD	
Intercuspid width	25.09	1.99	25.22	1.53	.985
Interpremolar width	26.30	2.05	27.74	1.73	.015
Intermolar width	31.65	2.54	32.93	2.70	.110
Perimeter	73.65	4.11	74.15	3.78	.933
Length	29.50	2.88	29.10	2.07	.462
Crowding	4.65	2.41	2.88	2.14	.000
U1/PP°	110.13	8.23	111.6	5.94	.693

$P < .05$; $P < .01$; $P < .001$; not significant.

After TPA use in the treated group, all maxillary dental arch dimensions showed significant increases except for arch length and U1/PP angulation. The arch perimeter increased by 4.3 mm and the crowding decreased by 5.6 mm. Whereas in the control group, only minute significant changes were noted, except for crowding that increased by 1.6 mm (Table 3).

Changes after full fixed treatment are reported in Table 4. A decrease was identified in intercuspid width (0.4 mm; $P = .045$), arch perimeter (1.3 mm; $P < .001$) and arch length (0.6 mm; $P = .026$). No other significant changes were identified except for intermolar width, which was different according to sex (0.2 mm; $P < .001$).

Finally, at follow-up (Table 5), for the treated group the reduction of crowding was important (6.2 mm; $P < .001$). The differences between the treated and untreated groups were all significant, except for arch length and upper incisor inclination, which remained the same. All those differences favored the treated group.

DISCUSSION

The results of this study increase our understanding of the maxillary dental arch dimensional changes and their short- and long-term stability among growing patients treated by TPA followed by full fixed appliances. In summary, TPA in mixed dentition followed by fixed appliances was effective in significantly increasing dental arch width and perimeter after an average 6.7-year follow-up.

Table 3. Maxillary Dental Arch Changes Comparisons After Transpalatal Arch Treatment ($T_1 - T_0$)^a

Variables (mm)	Treated		Untreated		<i>P</i>
	Mean	SD	Mean	SD	
Intercuspid width	2.27	1.66	-0.01	0.98	.000
Interpremolar width	4.43	2.47	0.05	1.18	.000
Intermolar width	5.09	2.28	0.83	1.31	.000
Perimeter	4.26	2.22	-0.08	3.37	.000
Length	0.23	2.21	0.01	1.67	.689
Crowding	-4.30	1.97	+1.63	2.45	.000
U1/PP°	1.20	5.78	0.75	5.44	.712

^a T_0 indicates before TPA treatment; T_1 , after TPA treatment.

Table 4. Maxillary Dental Arch Changes Comparisons After Treatment ($T_3 - T_2$)^a

Variables (mm)	Treated		Untreated		P
	Mean	SD	Mean	SD	
Intercuspid width	-0.18	0.36	-0.57	1.07	.045
Interpremolar width	-0.16	0.26	-0.75	0.64	.559
Intermolar width	-0.19	0.34	-0.39	0.81	Sex .000
					Sex * Group .002
Perimeter	-0.48	0.59	-1.78	1.17	.000
Length	-0.05	0.15	+0.56	1.86	.026
Crowding	+0.47	0.54	+0.32	1.91	.668
U1/PP°	0.79	2.89	1.98	5.24	.393

^a T_2 indicates after fixed appliance treatment; T_3 , a minimum of 3 years after fixed appliance treatment.
* $P < .05$; $P < .01$; $P < .001$; not significant.

The overall active treatment induced significant increases in arch width and perimeter by simultaneously reducing crowding. However, the main increase of maxillary arch dimensions occurred during the first phase of active treatment, while only a TPA was used, when posterior teeth moved buccally without the help of orthodontic fixed appliances (except for the maxillary first molars).

Moreover, the behavior of arch length should be considered in detail. During the 4.2-year treatment period, the exfoliation of the upper second deciduous molar and their replacement with smaller second premolars occurred. This should have decreased the arch length. Nevertheless, an increase in arch perimeter was observed, rather than a loss, because of the increase in arch widths. In any event, the differences between the treated and control groups for arch length can be considered clinically irrelevant (0.26 mm); meanwhile, the arch perimeter is clearly clinically relevant (7.42 mm).

At the follow-up period, when all subjects had ended or nearly finished their active facial growth periods, as determined by the cervical vertebral maturation assessment (CS6), all maxillary dental arch dimensions were slightly reduced.

Only slight changes occurred in the posttreatment period (average 6.7 years). A net significant increase of maxillary widths and perimeter increase was observed between T_2 and T_1 . Thereafter (T_3 to T_2), in the treatment group, a high percentage of the intercanine (93%), interpremolar (96%), intermolar (96%), width and arch perimeter (89%) increases were maintained. Keep in mind that 4.2 mm of crowding were previously solved. The maxillary dental arch length decreased significantly, suggesting that incisors were not proclined. This was confirmed through the cephalometric analysis.

Maxillary dental arch dimensions, therefore, may be changed with a TPA in the mixed dentition followed by

Table 5. Maxillary Dental Arch Changes Comparisons From Start to Follow-up ($T_3 - T_0$)^a

Variables (mm)	Treated		Untreated		P
	Mean	SD	Mean	SD	
Intercuspid width	2.51	1.60	-0.44	1.20	.000
Interpremolar width	4.38	1.81	0.19	1.60	.000
Intermolar width	5.19	2.20	1.44	1.80	.000
Perimeter	3.95	2.59	-3.47	3.05	.000
Length	-1.43	2.07	-1.69	1.82	.689
Crowding	-4.18	2.20	+1.95	2.38	.000
U1/PP°	2.66	2.73	2.20	6.39	.705

^a T_0 indicates before TPA treatment; T_3 , a minimum of 3 years after fixed appliance treatment.

fixed appliances in the permanent dentition. After treatment, these arch dimensions tend to relapse toward their pretreatment values, but they could be considered basically stable as only a small percentage of crowding relapsed. These changes may be considered of a clinically irrelevant magnitude.

A potential explanation for the observed stability is that the major changes in arch maxillary dental arch dimensions were primarily achieved during the TPA treatment phase, whereas only small changes occurred after TPA. Theoretically, the greater tooth expansion movements, the greater the rebound toward their initial position (relapse). However, when the correction is achieved through a potentially physiological and not a mechanical expansion, dental relapse may be limited.²³ This may suggest that the smaller the changes with fixed appliances the smaller the tendency to relapse. Avoiding mechanical expansion may help to keep the correction stable. Cheek and/or lip muscular pressures are primarily involved. Another possibility could be that the TPA prevented maxillary molars from rotating and tipping into the second primary molar space when it did exfoliate.

Moreover, in this sample attempts were also made to maintain, during the full fixed appliance period, the arch dimensions and form achieved after TPA treatment, under the assumption that this would enhance stability. This was accomplished through the use of an arch form card used for bending arch wires that was derived from the dental cast arch form after TPA treatment. In addition, for a potential better result, dentoalveolar compensation, such as proclination of incisors, was avoided as much as possible. Thus, arch length was not further increased. Stability of the results may also be a function of good intercuspation. All patients finalized with good intercuspation. Thus, intercuspation might have contributed to stability but could not guarantee it. Relapse occurred even with good intercuspation. Finally, the favorable outcomes may also be related to the treatment timing (CS1 or 2 at T_0) of the nonextraction protocol.¹

When analyzing the literature, a direct comparison of the outcomes of this study with other similar investigations is difficult. Maxillary dental arch changes in patients treated with TPA in mixed dentition, followed by full fixed appliances have been rarely documented. Except for case reports, TPA investigations have been mainly performed *in vitro*.^{15–20} Those carried out on patients are few^{14,24} and not directly comparable. An increase of maxillary intermolar width of 1.1 mm, significantly lower than our reported 5.1 mm, was reported in mixed dentition patients treated with a TPA activated without expansion and used for a significantly shorter period (122 days on average).¹⁴ In another study,²⁴ data were not comparable as patients were treated for posterior crossbite correction for 1 year without a control group and follow-up. Moreover, no long-term studies address the stability of the changes after TPA followed by fixed appliances.

This study had some limitations. The average 6.7-year follow-up included a 2-year retention period; thus, seven patients were only 1 year out of retention. The term “crowding” is ambiguous.²⁵ In this study crowding was defined as the tooth-size/arch-length discrepancy; however, incisor proclination was not directly considered in the statistical analysis but considered through a proxy analysis. Our definition of clinical relapse was conservative, using 0 mm as baseline. The TPA was made of round stainless steel wire although titanium molybdenum alloy reduces the required force by 60%.¹⁵ The effect of such material change has not been investigated.

CONCLUSIONS

- After TPA treatment, a significant increase of maxillary dental arch widths and perimeter was observed along with a significant reduction of crowding without changes in arch length.
- After full fixed appliance treatment, minor increases in the arch width and perimeter were registered, which solved the residual crowding.
- At follow-up, all the arch dimensions decreased slightly. However, those dental arch changes can be considered clinically stable. Minor crowding of about 0.5 mm was observed in the treated group; 50% of the sample showed crowding of about 1 mm.
- Use of TPA in mixed dentition followed by fixed appliances was effective in significantly increasing dental arch width and perimeter, and the changes remained stable after an average 6.7-year follow-up.

ACKNOWLEDGMENT

This study was made possible by use of material from the Burlington Growth Centre, Faculty of Dentistry, University of Toronto, which was supported by funds provided by Grant (1)

(No. 605-7-299) National Health Grant (Canada), (data collection); (2) Province of Ontario Grant PR 33 (duplicating) and (3) the Varsity Fund (for housing and collection).

REFERENCES

1. Geran RG, McNamara JA Jr, Baccetti T, Franchi L, Shapiro LM. A prospective long-term study on the effects of rapid maxillary expansion in the early mixed dentition. *Am J Orthod Dentofacial Orthop*. 2006;129:631–640.
2. O'Grady PW, McNamara JA Jr, Baccetti T, Franchi L. A long-term evaluation of the mandibular Schwarz appliance and the acrylic splint expander in early mixed dentition patients. *Am J Orthod Dentofacial Orthop*. 2006;130:202–213.
3. Konstantonis D, Anthopoulou C, Makou M. Extraction decision and identification of treatment predictors in Class I malocclusions. *Prog Orthod*. 2013;19:14–47.
4. Holdaway RA. A soft-tissue cephalometric analysis and its use in orthodontic treatment planning. Part I. *Am J Orthod*. 1983;184:1–28.
5. Walter DC. Changes in the form and dimensions of dental arches resulting from orthodontic treatment. *Angle Orthod*. 1953;23:3–18.
6. Berlocher WC, Muller BH, Tinanoff N. The effect of maxillary palatal expansion on the primary dental arch circumference. *Pediatr Dent*. 1980;2:27–30.
7. Ormiston JP, Huang GJ, Little RM, Decker JD, Seuk GD. Retrospective analysis of long-term stable and unstable orthodontic treatment outcomes. *Am J Orthod Dentofacial Orthop*. 2005;128:568–574.
8. Little RM, Wallen TR, Riedel RA. Stability and relapse of mandibular anterior alignment-first premolar extraction cases treated by edgewise orthodontics. *Am J Orthod*. 1981;80:349–363.
9. De La Cruz AR, Sampson P, Little RM, Ártun J, Shapiro PA. Long-term changes in arch form after orthodontic treatment and retention. *Am J Orthod Dentofacial Orthop*. 1995;107:518–530.
10. BeGole EA, Sadowsky C. Methodologies for evaluating long-term stability of dental relationships after orthodontic treatment. *Semin Orthod*. 1999;5:142–150.
11. Little RM, Riedel RA, Stein A. Mandibular arch length increase during the mixed dentition: postretention evaluation of stability and relapse. *Am J Orthod Dentofacial Orthop*. 1990;97:393–404.
12. Germane N, Lindauer SJ, Rubenstein LK, Revere JH, Isaacson RJ. Increase in arch perimeter due to orthodontic expansion. *Am J Orthod Dentofacial Orthop*. 1991;100:421–427.
13. Cetlin NM, Ten Hoeve A. Nonextraction treatment. *J Clin Orthod*. 1983;17:396–413.
14. Dahlquist A, Gebauer U, Ingervall B. The effect of a transpalatal arch for the correction of first molar rotation. *Eur J Orthod*. 1996;18:257–267.
15. Burstone CJ, Koenig HA. Precision adjustment of the transpalatal lingual arch: computer arch form predetermination. *Am J Orthod*. 1981;79:115–133.
16. Rebellato J. Two-couple orthodontic appliance systems: transpalatal arches. *Semin Orthod*. 1995;1:44–54.
17. Ingervall B, Hönig KD, Bantleon HP. Moments and forces delivered by transpalatal arches for symmetrical first molar rotation. *Eur J Orthod*. 1996;18:131–139.
18. Braun S, Kusnoto B, Evans CA. The effect of maxillary first molar derotation on arch length. *Am J Orthod Dentofacial Orthop*. 1997;112:538–544.

19. Hoederath H, Bourauel C, Drescher D. Differences between two transpalatal arch systems upon first-, second-, and third-order bending activation. *J Orofac Orthop*. 2001;62:58–73.
20. Gündüz E, Zachrisson BU, Hönigl KD, Crismani AG, Bantleon HP. An improved transpalatal bar design. Part I. Comparison of moments and forces delivered by two bar designs for symmetrical molar derotation. *Angle Orthod*. 2003;73:239–243.
21. Baccetti T, Franchi L, McNamara JA Jr. The cervical vertebral maturation (CVM) method for the assessment of optimal treatment timing in dentofacial orthopedics. *Semin Orthod*. 2005;11:119–129.
22. Adkins MD, Nanda RS, Currier GF. Arch perimeter changes on rapid palatal expansion. *Am J Orthod Dentofacial Orthop*. 1990;97:194–199.
23. Proffit WR. Equilibrium theory revisited: factors influencing position of the teeth. *Angle Orthod*. 1978;48:175–186.
24. Ingervall B, Göllner P, Gebauer U, Fröhlich K. A clinical investigation of the correction of unilateral first molar crossbite with a transpalatal arch. *Am J Orthod Dentofacial Orthop*. 1995;107:418–425.
25. Little RM. The irregularity index: a quantitative score of mandibular anterior alignment. *Am J Orthod*. 1975;68:554–563.