

Morphometric analysis of long-term dentoskeletal effects induced by treatment with Balters bionator

Renato Bigliuzzi^a; Lorenzo Franchi^b; André Pinheiro de Magalhães Bertoz^c;
James A. McNamara Jr^d; Kurt Faltin Jr^e; Francisco Antonio Bertoz^f

ABSTRACT

Objective: To evaluate the long-term effects of the standard (Class II) Balters bionator in growing patients with Class II malocclusion with mandibular retrusion by using morphometrics (thin-plate spline [TPS] analysis).

Materials and Methods: Twenty-three Class II patients (8 male, 15 female) were treated consecutively with the Balters bionator (bionator group). The sample was evaluated at T0, start of treatment; T1, end of bionator therapy; and T2, long-term observation (including fixed appliances). Mean age at the start of treatment was 10 years 2 months (T0); at posttreatment, 12 years 3 months (T1); and at long-term follow-up, 18 years 2 months (T2). The control group consisted of 22 subjects (11 male, 11 female) with untreated Class II malocclusion. Lateral cephalograms were analyzed at the three time points for all groups. TPS analysis evaluated statistical differences (permutation tests) in the craniofacial shape and size between the bionator and control groups.

Results: TPS analysis showed that treatment with the bionator is able to produce favorable mandibular shape changes (forward and downward displacement) that contribute significantly to the correction of the Class II dentoskeletal imbalance. These results are maintained at a long-term observation after completion of growth. The control group showed no statistically significant differences in the correction of Class II malocclusion.

Conclusions: This study suggests that bionator treatment of Class II malocclusion produces favorable results over the long term with a combination of skeletal and dentoalveolar shape changes. (*Angle Orthod.* 2015;85:790–798.)

KEY WORDS: Functional jaw orthopedics; Class II malocclusion; Morphometric analysis; Thin-plate spline analysis

^a PhD Candidate in Orthodontics, Department of Pediatric and Social Dentistry, Dental School of Araçatuba, Universidade Estadual Paulista, São Paulo, Brazil, and Adjunct Professor, Department of Orthodontics, School of Dentistry, University Paulista, Araçatuba, São Paulo, Brazil.

^b Assistant Professor, Department of Surgery and Translational Medicine, University of Florence, Florence, Italy, and Thomas M. Graber Visiting Scholar, Department of Orthodontics and Pediatric Dentistry, School of Dentistry, The University of Michigan, Ann Arbor, Mich.

^c Assistant Professor, Department of Pediatric and Social Dentistry, Dental School of Araçatuba, Universidade Estadual Paulista, São Paulo, Brazil.

^d Thomas M. and Doris Graber Endowed Professor of Dentistry, Department of Orthodontics and Pediatric Dentistry, School of Dentistry; Professor of Cell and Developmental Biology, School of Medicine; Research Professor, Center for Human Growth and Development, The University of Michigan, Ann Arbor, and private practice, Ann Arbor, Mich.

^e Professor and Department Chair, Department of Orthodontics, School of Dentistry, University Paulista, Araçatuba, São Paulo, Brazil.

^f Professor, Department of Pediatric and Social Dentistry, Dental School of Araçatuba, Universidade Estadual Paulista, São Paulo, Brazil.

INTRODUCTION

Functional jaw orthopedics (FJO) at the pubertal spurt followed by fixed appliances is a viable therapeutic option in patients with Class II malocclusion associated with mandibular retrusion.¹ Among different FJO available to treat Class II malocclusion, the Balters bionator is a tooth-borne (passive) functional appliance designed and introduced by Balters in the 1960s.² The bionator moves the mandible anteriorly so that over time a new postural position of the lower arch

Corresponding author: Dr Renato Bigliuzzi, Faculdade de Odontologia de Araçatuba, UNESP Universidade Estadual Paulista, Rua José Bonifácio, 1193 Araçatuba, São Paulo, 16015-050, Brasil
(e-mail: bigliazzir@hotmail.com)

Accepted: October 2014. Submitted: August 2014.

Published Online: December 3, 2014

© 2015 by The EH Angle Education and Research Foundation, Inc.

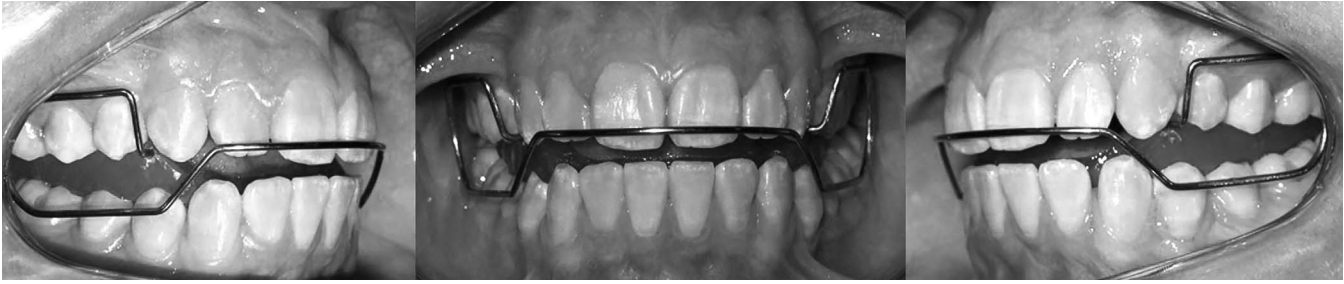

Figure 1. Balters bionator in the oral cavity.

is achieved, producing significant dentoskeletal changes²⁻⁵ and improvement of the facial profile.^{5,6}

In the literature,^{5,7,8} the bionator has shown moderate efficacy and efficiency in inducing supplementary growth of the mandible in treated subjects vs untreated Class II controls. However, there are still controversies concerning the long-term effects of FJO on the maxilla and the mandible.⁹⁻¹³ All of the conflicting findings could be due to discrepancies in age selection, skeletal maturity, matching with control groups, treatment duration, and great variability in the cephalometric variables adopted by the different investigators. Furthermore, conventional cephalometric analysis (CCA), despite being individualized, does not always prove effective in determining accurately the location and mode in which changes in shape and size occur within the craniofacial complex.¹⁴ Thus, CCA is governed rather by conventions involving points and planes, which fail to capture curvilinear forms and changes in these forms.¹⁵

Bookstein¹⁶ introduced thin-plate spline (TPS) analysis as a morphometric tool for the comparison of configuration landmarks. It is a descriptive method of shape (or shape change) independent from size that has been developed and implemented as a major improvement when compared with conventional cephalometrics.^{16,17} It also allows the construction of transformation grids that capture differences in form, enabling a more effective visual interpretation and mathematical representations of treatment effects.¹⁶

Antunes et al.¹⁸ analyzed by means TPS analysis the short-term effects of the standard Balters bionator in growing patients with Class II malocclusion with mandibular retrusion. TPS analysis showed that treatment with the bionator is able to produce favorable mandibular shape changes that contributed significantly to the correction of the Class II dentoskeletal imbalance. No data are available in the literature assessing the long-term dentoskeletal changes produced by orthopedic treatment of Class II malocclusion by means of geometric morphometric analysis. The aim of this study, therefore, was to analyze the long-term effects of the standard (Class II) Balters bionator

in the treatment of patients with Class II malocclusion with mandibular retrusion by using TPS analysis.

MATERIALS AND METHODS

Institutional review board approval was obtained before the study (418/10/CEP/ICS/UNIP). Cephalometric records of 23 white patients (8 male, 15 female) with Class II division 1 malocclusion with mandibular retrusion determined by cephalometric analysis of Ricketts et al.¹⁹ and Schwarz, modified by Faltin et al.,²⁰ consecutively treated with the Balters bionator (BG group; Figure 1) were collected from a single orthodontic practice (Table 1). The nonextraction treatment protocol consisted of a bionator, constructed without coverage of the lower incisors, to be worn 16–18 hours a day and followed by approximately 1 year of fixed appliance therapy to refine occlusion. Those patients still in the mixed dentition phase by the end of bionator treatment were instructed to wear the appliance only at night until complete eruption of the premolars and permanent canines. After the comprehensive treatment, each patient was given a lower incisor fixed retainer. Lateral cephalograms were obtained at three time periods: T0, at the start of treatment; T1, at the end of bionator therapy; and T2, at long-term observation after completion of growth,²¹ including the phase with fixed appliances. Patient compliance and treatment success were not considered as inclusion criteria so that sample selection was conducted irrespective of clinical results.

The control group (CG group) consisted of 22 white subjects (11 male, 11 female) with untreated Class II division 1 malocclusion. Cephalograms of the untreated subjects were obtained from the University of Michigan Growth Study and the Denver Child Growth Study. Significant effort was directed toward matching the CG to the BG as closely as possible with respect to dentoskeletal features (Class II with mandibular retrusion) at T0, gender distribution (for the effect this variable would have on head size), age at all observation periods, duration of observation intervals (T0–T1, T1–T2, and T0–T2), and skeletal maturity²¹ at all time points (Table 1). The two groups (BG and CG)

Table 1. Demographics for the Treatment and Control Groups^{a,b}

Groups	Age at T0, y		Age at T1, y		Age at T2, y		T0–T1 Interval, y		T1–T2 Interval, y		T0–T2 Interval, y	
	Mean	SD	Mean	SD	Mean	SD	Mean	SD	Mean	SD	Mean	SD
Bionator group (n = 23; 8 male, 15 female) CS at T0: CS1 = 9; CS2 = 6; CS3 = 8 CS at T1: CS3 = 10; CS4 = 7; CS5 = 6 CS at T2: CS6 = 23	10.2	1.5	12.3	1.8	18.2	2.1	2.1	1.0	5.11	1.7	7.1	2.1
Control group (n = 22; 11 male, 11 female) CS at T0: CS1 = 7; CS2 = 8; CS3 = 7 CS at T1: CS3 = 11; CS4 = 7; CS5 = 4 CS at T2: CS6 = 22	10.3	1.4	12.1	1.6	16.8	1.5	2.0	0.8	4.6	2.0	6.5	1.8

^a T0 indicates at the start of treatment; T1, at posttreatment; and T2, at long-term follow-up.

^b CS indicates the Cervical Stages.

showed a full cusp Class II molar relationship and an average overjet greater than 6 millimeters.

The homologous landmarks illustrated in Figure 2 were digitized on the lateral films using TPS software (tpsDig2 version 2.16, Ecology & Evolution, SUNY, Stonybrook, NY). TPS software (tpsRegr version 1.38, Ecology & Evolution) computed the orthogonal least-

squares Procrustes average configuration of craniofacial landmarks in both BG and CG at T0, T1, and T2, using the generalized orthogonal least squares procedures described by Rohlf and Slice.²² The average craniofacial configurations were subjected to TPS analysis to compare the longitudinal differences in shape within the treated and control groups. The

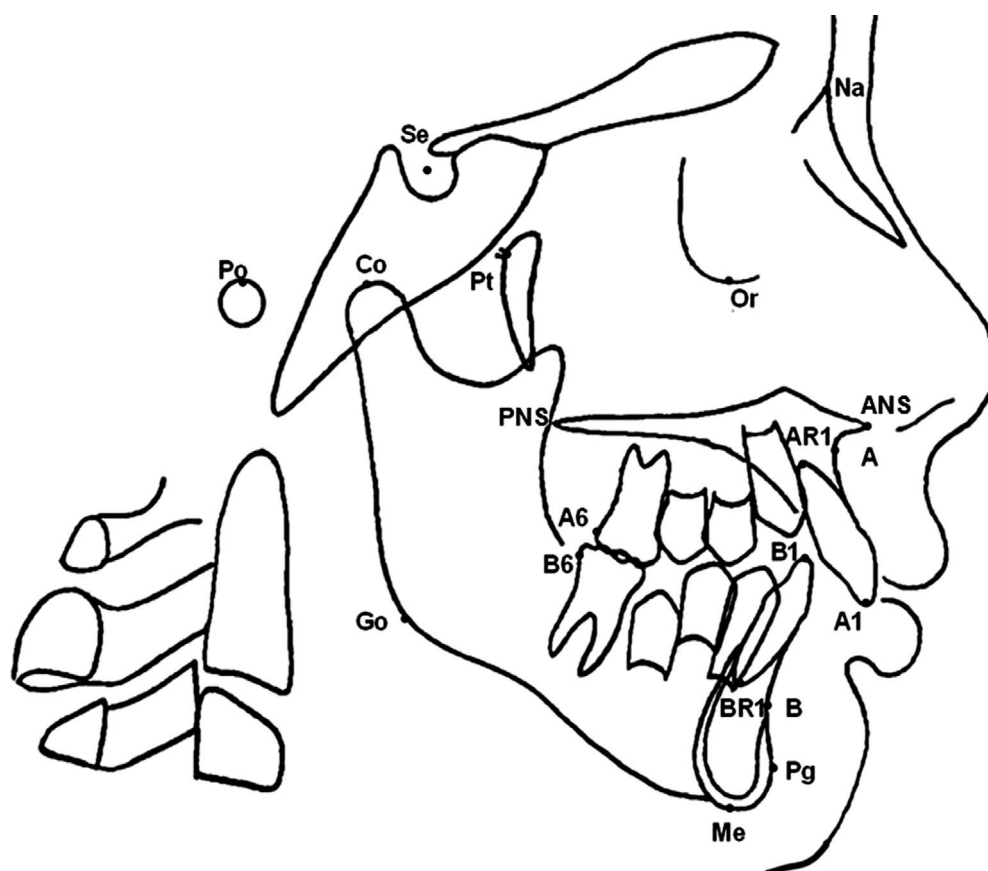


Figure 2. Landmarks used for morphometric analysis. Se (sella), Na (nasion), Po (porion), Co (condyion), Pt (superior pterygoid point), Or (orbitale), ANS (anterior nasal spine), PNS (posterior nasal spine), A (point A), A1 (incisal of upper central incisor), point B1 (incisal of lower central incisor), AR1 (apex of the root of the upper central incisor), BR1 (apex of the root of the lower central incisor), B (point B), Pg (pogonion), point Go (gonion), point A6 (distal upper first molar superior), point B6 (distal lower first molar), and point Me (menton).

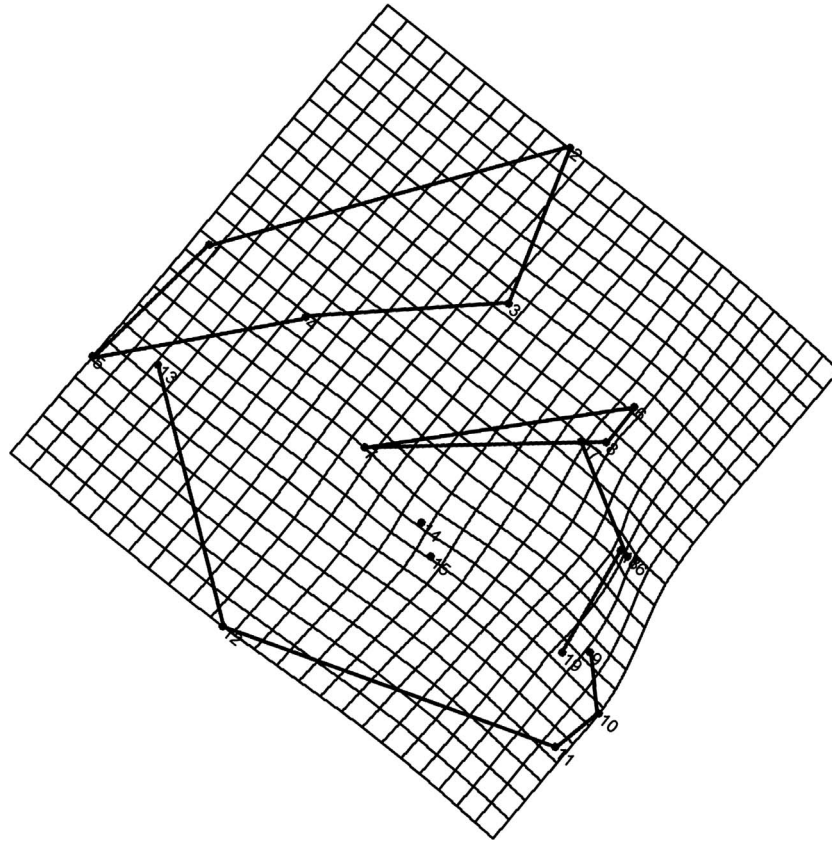


Figure 3. TPS graphical display of shape differences between T0 and T1 in the bionator group (magnification factor 3 \times).

smoothing effect of the TPS also gives some idea of shape changes in regions between landmarks. The matrix of Procrustes residuals can be used for any statistical procedure.^{18,22}

Sample size calculation for both groups was determined in order to have more specimens than the number of partial warps plus the number of independent variables. In order to perform multivariate tests of significance, the sample sizes must be large enough so that the error degrees of freedom are equal to or larger than the number of dependent variables.²²

Statistical analysis of shape differences was performed by means of permutation tests with 1000 random permutations on Goodall F statistics (tpsRegr version 1.38, Ecology & Evolution). Differences in size (centroid size analysis) at the three developmental phases (T0–T1, T1–T2, and T0–T2) were tested by means of Mann-Whitney *U*-test for the cross-sectional comparisons and by means of Wilcoxon tests for the longitudinal comparisons. For those comparisons showing significant shape differences, a test for allometry, checking for shape depending on size, was carried out (tpsRegr version 1.38, Ecology & Evolution).

To estimate operator reliability, 30 randomly selected records were reevaluated after a week of prelim-

inary data collection. Intraobserver precision was calculated on distances between landmark positions between the first tracing and the second tracing cephalograms in both groups by the same operator, using Dahlberg formula.²³ The average method error for landmark identification was 0.9 mm (SD = 0.4).

RESULTS

No significant shape differences were found between BG and CG at T0 ($P = .431$). The results from centroid size analysis did not reveal any significant difference in size between the BG and CG at T0 ($P = .125$). At T1 and T2, significant shape ($P = .001$) and size differences ($P = .0004$ and $P = .000$) were found between the BG and CG.

The analysis of longitudinal dentoskeletal shape changes in the BG showed significant T0–T1 differences ($P = .000$; Figure 3). These differences could be described by an extension in the horizontal axis in the region of the mandibular symphysis and in the middle portion of the mandible between the condyle and the symphysis. A slight extension on both the horizontal and vertical axes could be recorded at the gonial angle. A marked constriction on the horizontal axis in the region of the upper incisors was also

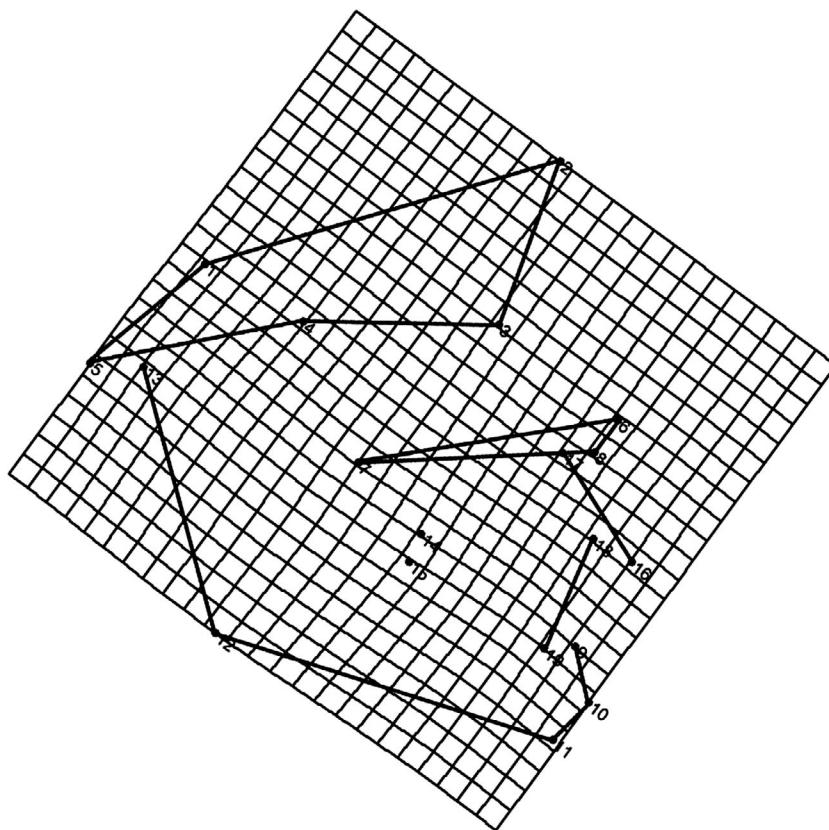


Figure 4. TPS graphical display of shape differences between T0 and T1 in the control group (magnification factor 3 \times).

evident, reflecting dental changes. The results from centroid size analysis showed significant size changes from T0 to T1 in the BG ($P = .0001$). Allometry was significant for the BG ($F = 3.526$; $P = .015$), thus indicating dependency of size differences on shape differences. No significant shape differences were observed for the same interval in the control group ($P = .293$; Figure 4). Longitudinal analysis of centroid size showed statistically significant T0–T1 changes in the CG ($P = .017$).

Posttreatment shape changes could be detected in the BG ($P = .000$; Figure 5). These longitudinal T1–T2 shape differences could be described by a slight extension in the horizontal axis in the region of the mandibular symphysis and an extension in the middle portion of the mandible between the condyle and the symphysis. Marked vertical and horizontal extensions could be visualized also in the mandibular ramus. The results from centroid size analysis showed significant size changes from T1–T2 in the BG ($P = .000$). The influence of size on shape changes (allometry) was detected for the BG ($F = 2.543$; $P = .05$). In the CG, no significant shape differences could be detected ($P = .923$; Figure 6). Longitudinal analysis of centroid size showed statistically significant T1–T2 changes in the CG ($P = .020$).

The treatment and posttreatment (long-term) T0–T2 changes in BG revealed a significant ($P = .000$; Figure 7) extension in horizontal and vertical directions of the mandible with a constriction in the horizontal axis in the region of the upper incisors. Centroid size analysis showed significant size differences from T0 to T2 in the BG ($P < .0001$). Allometry was significant ($F = 1.728$; $P = .013$), thus indicating dependence of size differences on shape differences in the treated group. No significant long-term shape differences could be detected in the CG ($P = .999$; Figure 8). Longitudinal analysis of centroid size showed statistically significant T0–T2 changes in the CG ($P = .0007$).

DISCUSSION

Most of the investigations concerning the treatment of Class II malocclusion with functional appliances, especially with the bionator, are short term in nature. The studies that analyzed the long-term effects of bionator treatment^{4,5,9,10} were conducted by using CCA. The CCA methods used in those studies do not allow an understanding of the changes in mandibular morphology (shape) that occur with bionator therapy. New methods of geometric morphometrics, based on the analysis of landmark configurations, permit further in-depth investigation of morphologic processes pro-

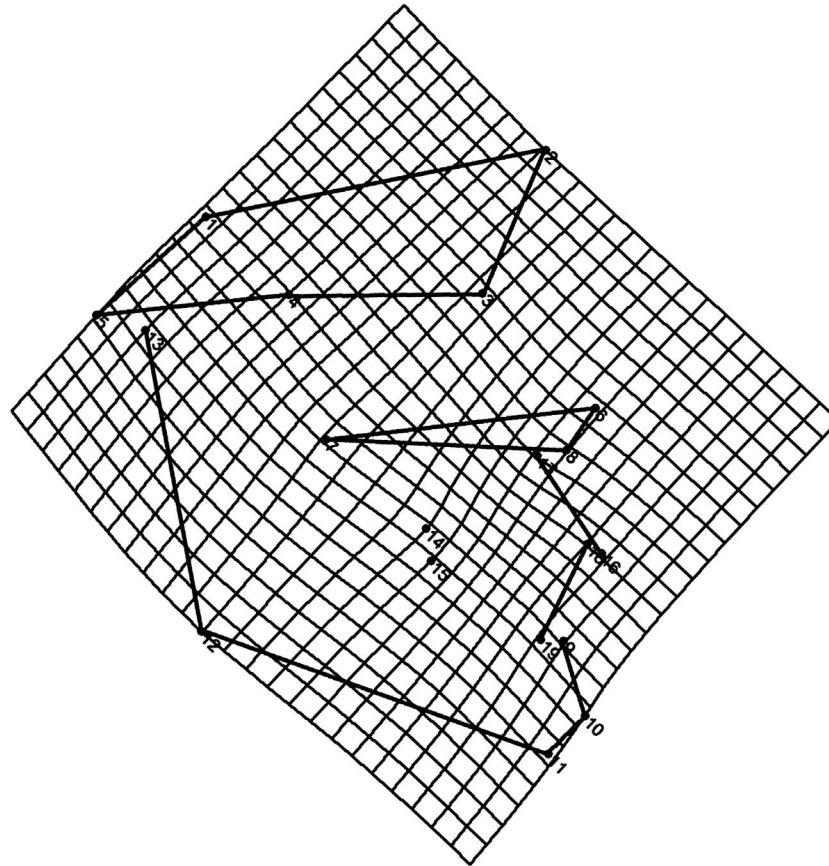


Figure 5. TPS graphical display of shape differences between T1 and T2 in the bionator group (magnification factor 3 \times).

duced by FJO.¹⁸ Among these new alternatives, TPS analysis allows the possibility of analyzing size and shape changes in a “size-free” shape space.^{16,17} It enables easy, comprehensible graphical representation of changes in shape, while clearly highlighting the regions where these changes occur. TPS analysis expresses the difference between two average configurations of homologous landmarks through transformation grids, and it continuously models the deformation of a given shape into another using a regression function.¹⁸ Projected into a linear tangent space, the shape variables can then be used in further conventional statistical procedures.²²

The present study compared the long-term effects of the standard (Class II) Balters bionator in the treatment of patients with Class II malocclusion with mandibular retrusion vs an untreated Class II control group by using TPS and centroid size analyses. As in Antunes et al.,¹⁸ a constriction in the region of the upper incisors indicating a retroclination of these teeth were found in the short term. On the other hand, no significant changes could be detected in the dentoalveolar component during the T1–T2 posttreatment period. The vestibular wire is a basic feature of the Balters bionator. It stimulates the lip closure with favorable

negative pressure, thereby helping the mandible find its anterior position in the appliance with a concomitant effect on lip and cheek musculature.¹⁰ The dentoalveolar compensation in the BG was probably related to lip closure and improvement of tongue position (a new neuromuscular pattern) induced by the appliance.¹⁸ In the standard Balters bionator used in our study, the buccal shield does not touch the upper incisors and does not have inferior incisal coverage, which can play a role in dental compensation rather than orthopedic correction.^{9,18} Consequently, the absence of the coverage of the lower incisors did not affect significantly their inclination.^{5,9} The bionator induced significant short- and long-term shape changes in the mandible that could be described as a mandibular forward and downward displacement. This mandibular displacement was more evident at the mandibular symphysis, and it was associated with a mandibular elongation that was depicted by a horizontal extension of the grid in the middle portion of the mandible between the condyle and the symphysis. In agreement with the findings by Antunes et al.,¹⁸ these changes contributed significantly to the sagittal and vertical correction of the dentoskeletal Class II imbalance during the treatment period with the bionator (T0–T1).

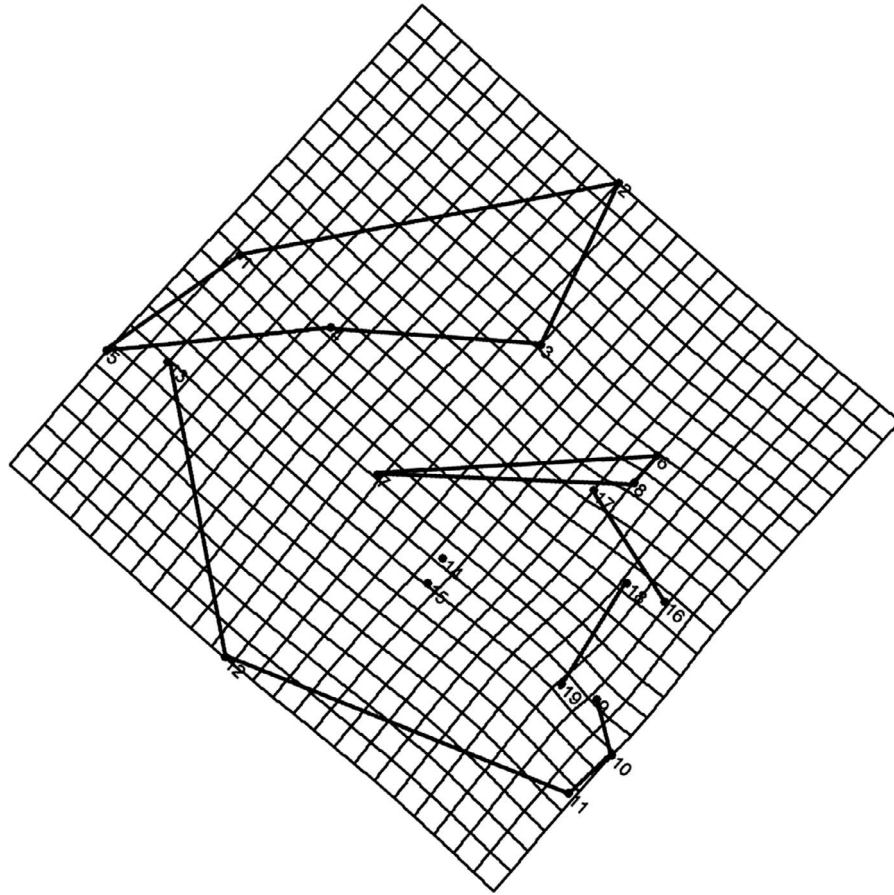


Figure 6. TPS graphical display of shape differences between T1 and T2 in the control group (magnification factor 3 \times).

Favorable mandibular shape changes occurred also during the T1–T2 posttreatment period. These changes were characterized by a vertical elongation of the ramus and by a stretching in the direction of total mandibular length Co-Pg.

The second part of this study analyzed the long-term overall effects (T0–T2) of bionator therapy. The bionator induced a significant supplementary elongation of the mandible that was associated with vertical displacement of the gonial angle and a change in the direction of condylar growth (more posterior) during the treatment and posttreatment period (T0–T2). The results of the current study differ from those reported by Malta et al.⁵ and Franchi et al.,⁹ who, by using CCA, found that the significant elongation of the mandible was not associated with a significant advancement of the chin (Pg to nasion perpendicular) both in the short and in the long term. These differences are probably due to the fact that CCA measures linear distances or angles but does not relate distance or angle changes to whole form changes, leading to limitations in shape assessment.^{14,17} No significant shape change could be recorded in the CG at any of the observation intervals. Consequently, no significant improvement in the den-

toskeletal Class II relationships was evident in the CG. The present investigation showed that the favorable mandibular modifications induced by prepubertal and pubertal treatment are stable in the long term.

The transformation grids corresponding to the deformations induced by treatment in the average configuration of the treated sample clearly illustrated the absence of shape changes of all skeletal maxillary and cranial base structures at all observation periods.

TPS analysis showed that treatment with the bionator is able to produce favorable mandibular shape changes that contribute significantly to the correction of the Class II dentoskeletal imbalance as reported in previous studies.^{4,5,9,18} These favorable shape changes are maintained in the long term after completion of growth. A limitation of the present study was that the role of individual skeletal maturity (prepubertal vs pubertal patients) could not be investigated due to the relatively small sample size. More studies are needed to determine the possible role of treatment timing on treatment outcomes and the impact of mandibular dentoskeletal shape changes on facial esthetics evaluated with geometric morphometrics.

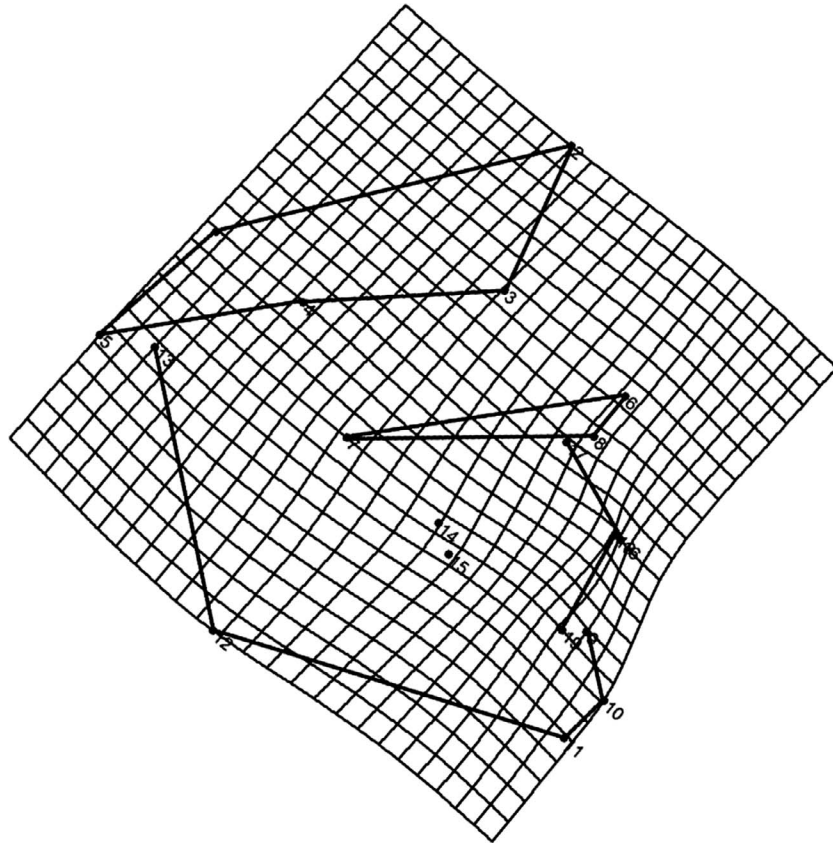


Figure 7. TPS graphical display of shape differences between T0 and T2 in the bionator group (magnification factor 3×).

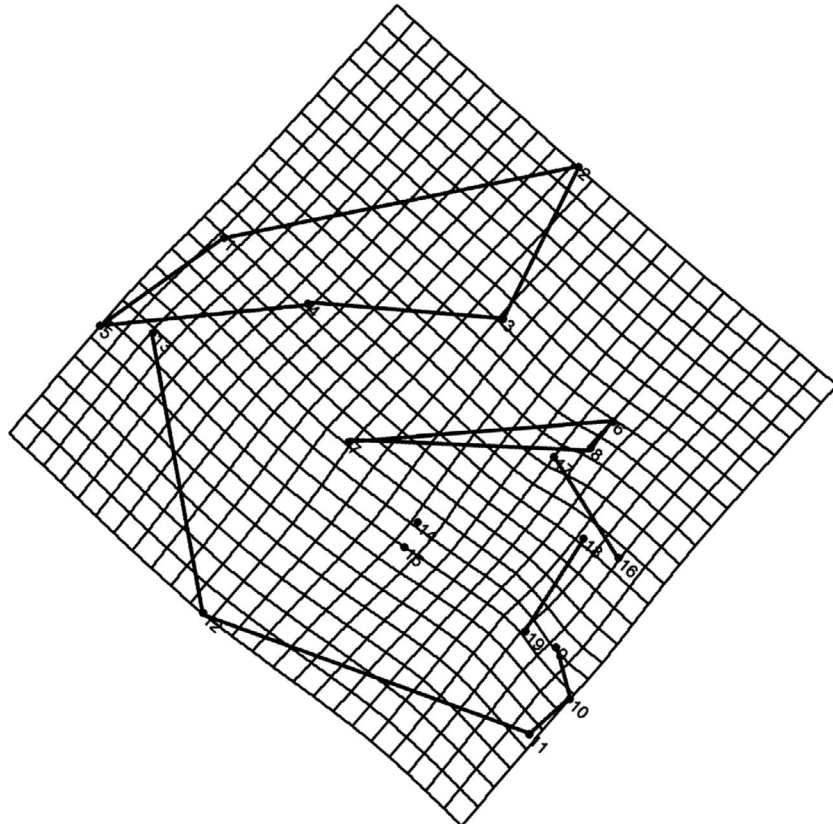


Figure 8. TPS graphical display of shape differences between T0 and T2 in the control group (magnification factor 3×).

CONCLUSIONS

- The bionator appliance did not induce a restraining shape effect on the maxilla, while it was able to produce significant mandibular shape changes characterized by a forward and downward displacement associated with mandibular elongation. These shape changes contributed significantly to the dentoskeletal correction of the Class II dentoskeletal imbalance, and these results were maintained in the long term after completion of growth.
- These short- and long-term findings confirm that functional jaw orthopedics is an effective therapeutic approach to Class II malocclusion associated with mandibular deficiency.

REFERENCES

1. Baccetti T, McNamara JA Jr. The impact of functional jaw orthopedics in subjects with unfavorable Class II skeletal patterns. *Prog Orthod*. 2010;11:118–126.
2. Balters W. Extrait de technique du Bionator. *Rev Franc Odontostomat*. 1964;11:191–212.
3. Carels C, Reychler A, Van Der Linden FP. Cephalometric evaluation of dento-skeletal changes during treatment with the Bionator type 1. *J Oral Rehabil*. 1997;24:841–848.
4. Faltin K Jr, Faltin RM, Baccetti T, Franchi L, Ghiozzi B, McNamara JA Jr. Long-term effectiveness and treatment timing for Bionator therapy. *Angle Orthod*. 2003;73:221–230.
5. Malta LA, Baccetti T, Franchi L, Faltin K Jr, McNamara JA Jr. Long-term dentoskeletal effects and facial profile changes induced by bionator therapy. *Angle Orthod*. 2010;80:10–17.
6. Lange DW, Kalra V, Broadbent BH Jr, Powers M, Nelson S. Changes in soft tissue profile following treatment with the bionator. *Angle Orthod*. 1995;65:423–430.
7. Jacobs T, Sawaengkit P. National Institute of Dental and Craniofacial Research efficacy trials of bionator class II treatment: a review. *Angle Orthod*. 2002;72:571–575.
8. Cozza P, Baccetti T, Franchi L, De Toffol L, McNamara JA Jr. Mandibular changes produced by functional appliances in Class II malocclusion: a systematic review. *Am J Orthod Dentofacial Orthop*. 2006;129:599.e1–599.e12.
9. Franchi L, Pavoni C, Faltin K Jr, McNamara JA Jr, Cozza P. Long-term skeletal and dental effects and treatment timing for functional appliances in Class II malocclusion. *Angle Orthod*. 2013;83:334–340.
10. Rudzki-Janson I, Noachtar R. Functional appliance therapy with the Bionator. *Semin Orthod*. 1998;4:33–45.
11. DeVincenzo JP. Changes in mandibular length before, during, and after successful orthopedic correction of Class II malocclusions, using a functional appliance. *Am J Orthod Dentofacial Orthop*. 1991;99:241–257.
12. Hansen K, Pancherz H. Long-term effects of Herbst treatment in relation to normal growth development: a cephalometric study. *Eur J Orthod*. 1992;14:285–295.
13. Angelieri F, Franchi L, Cevidanes LH, Scanavini MA, McNamara JA Jr. Long-term treatment effects of the FR-2 appliance: a prospective evaluation 7 years post-treatment. *Eur J Orthod*. 2014;36:192–199.
14. Moyers RE, Bookstein FL. The inappropriateness of conventional cephalometrics. *Am J Orthod*. 1979;75:599–617.
15. Bookstein FL. On the cephalometrics of skeletal change. *Am J Orthod*. 1982;82:177–182.
16. Bookstein FL. *Morphometrics Tools for Landmark Data*. New York, NY:Cambridge University Press; 1991.
17. McIntyre GT, Mossey PA. Size and shape measurement in contemporary cephalometrics. *Eur J Orthod*. 2003;25:231–242.
18. Antunes CF, Bigliazzi R, Bertoz FA, Ortolani CL, Franchi L, Faltin K Jr. Morphometric analysis of treatment effects of the Balters bionator in growing Class II patients. *Angle Orthod*. 2013;83:455–459.
19. Ricketts RM, Roth RH, Chaconas SJ. *Orthodontic Diagnosis and Planning: Their Roles in Preventive and Rehabilitative Dentistry*. Vol 1. Denver, Colo:Rocky Mountain Data Systems; 1982.
20. Faltin K Jr, Machado CR, Rebecchi MCV. Valores médios da análise cefalométrica de Schwarz-Faltin para jovens brasileiros, leucodermas com oclusão normal. *Rev Soc Paran Ortodon*. 1997;1:31–42.
21. Baccetti T, Franchi L, McNamara JA Jr. The cervical vertebral maturation (CVM) method for the assessment of optimal treatment timing in dentofacial orthopedics. *Semin Orthod*. 2005;11:119–129.
22. Rohlf FJ, Slice DE. Extensions of the Procrustes method for the optimal superimposition of landmarks. *Systematic Biology*. 1990;39:40–59.
23. Dahlberg AG. *Statistical Methods for Medical and Biological Students*. London, UK:Bradford and Dickens; 1940.