

Comparison between direct vs indirect anchorage in two miniscrew-supported distalizing devices

Mauro Cozzani^a; Mattia Fontana^b; Giuliano Maino^c; Giovanna Maino^d; Lucia Palpacelli^e; Alberto Caprioglio^f

ABSTRACT

Objective: To compare two distalizing devices supported by palatal miniscrews, the MGBM System (MGBM) and the Distal Screw appliance (DS), in dental Class II patients.

Materials and Methods: Pretreatment (T1) and postdistalization (T2) lateral cephalograms of 53 Class II malocclusion subjects were examined. MGBM consisted of 29 patients (16 males, 13 females) with a mean pretreatment age of 12.3 ± 1.5 years; DS consisted of 24 patients (11 males, 13 females) with a mean pretreatment age of 11.3 ± 1.2 years. The mean distalization time was 6 ± 2 months for MGBM and 9 ± 2 months for DS. Initial and final measurements and treatment changes were compared by means of a Student's *t*-test.

Results: Maxillary superimpositions showed that the maxillary first molar distalized an average of 5.5 mm in the MGBM and 3.2 mm in the DS between T1 and T2; distal molar tipping was greater in the MGBM (10.3°) than in the DS (3.0°). First premolar showed a mean mesial movement of 1.4 mm, with a mesial tipping of 4.4° in the MGBM; on the contrary, first premolar showed a distal movement of 2.2 mm, with a distal tipping of 6.2° , in the DS.

Conclusions: The MGBM system resulted in greater distal molar movement and less treatment time, resulting in more efficient movement than was associated with the DS; DS showed less molar tipping during distalization. (*Angle Orthod.* 2016;86:399–406.)

KEY WORDS: Class II malocclusion; Molar distalization; Miniscrews; Skeletal anchorage; Intraoral distalizing appliances

INTRODUCTION

The use of noncompliance distalizing devices had become increasingly popular for correcting dental Class II malocclusion.¹ These appliances, which in-

clude the Hilgers Pendulum,² the Distal Jet,³ and superelastic nickel-titanium wires,⁴ were introduced in the 1980s. However, they presented two main negative effects: (1) anchorage loss in reaction to the molar distalization,¹ such as premolar mesial movement and flaring of the maxillary incisor, which could require additional time to be corrected during the fixed appliances therapy, and (2) the use of distalized molars as anchorage to retract anterior teeth, with the consequent high risk of relapse to the Class II molar relationship.⁵

In order to increase anchorage resistance and avoid undesirable side effects on anchoring teeth, the use of mini-implants or miniscrews was introduced.⁶ Based on their reduced invasiveness, ease of insertion and removal, the possibility of immediate loading, and their versatility, these devices were increasingly used, even in combination with distalizing devices. Paramedian and midpalatal insertion sites seem to be the most suitable for this purpose^{7,8} since they do not interfere with dental movement in the maxillary arch, even if they cannot be recommended in the presence of unerupted palatal canines. On the contrary, buccal interradicular sites

^a Professor of Orthodontics, School of Dental Medicine, University of Cagliari, La Spezia, Italy.

^b Research Fellow in Orthodontics, University of Insubria, Varese, Italy.

^c Visiting Professor, Post-Graduate Program in Orthodontics, University of Insubria, Varese, Italy.

^d Graduate in Orthodontics, Private Practice, Basso del Grappa, Italy.

^e Graduate in Orthodontics, Private Practice, Macerata, Italy.

^f Chairman, Post-Graduate Program in Orthodontics, School of Dental Medicine, Department of Surgical and Morphological Science, University of Insubria, Varese, Italy.

Corresponding author: Dr Mattia Fontana, Research Fellow in Orthodontics, University of Insubria, Via G. Piatti, 11 Varese (VA), Italy
(e-mail: mattiafontana16@gmail.com)

Accepted: June 2015. Submitted: April 2015.

Published Online: July 29, 2015

© 2016 by The EH Angle Education and Research Foundation, Inc.

may sometimes involve a specific surgical protocol to avoid root damage, require additional radiographic examinations,⁹ and represent an obstacle to spontaneous retraction of premolars during distalization of the first molar until screws are inserted.¹⁰

A recent meta-analysis¹⁰ revealed that indirect skeletal anchorage showed a certain amount of anchorage loss at the premolar and incisor, whereas these side effects were avoided by those who used direct skeletal anchorage. For this reason, during recent years we have seen various modifications of distalizing appliances used in combination with paramedian miniscrews.

Dentoskeletal changes associated with temporary anchorage device (TAD)-anchored distalizing appliances have been described in the literature. However, comparisons between interradicular vs paramedian miniscrew insertion techniques are still lacking. Therefore, the aim of this study was to compare the dentoalveolar and skeletal changes between the MGBM System (MGBM)^{11,12} (interradicular miniscrews placement) and the Distal Screw appliance (DS)^{13,14} (paramedian miniscrews) in dental Class II patients. The null hypothesis was that both appliances would result in similar dental and skeletal changes.

MATERIALS AND METHODS

Sample Selection

A sample of 77 patients was retrospectively obtained by two board-certified orthodontists. All patients were selected according to the following criteria:

- Skeletal Class I or mild Class II malocclusion and a bilateral full cusp or end-to-end Class II molar relationship;
- Absence of protrusive profile or mandibular retrusion;¹⁵
- Nonextraction treatment, with mandibular crowding of less than 3 mm;
- Mandibular inclination (SN/Go-Gn angle) of less than 37°;
- Use of MGBM (Figure 1a,b) or DS appliance (Figure 2) during the distalization phase; and
- Good-quality radiographs with adequate landmark visualization.

From the initial sample, 14 patients in the MGBM group and 10 patients in the DS group were excluded according to the defined criteria. The final sample consisted of 53 white subjects who were divided in two groups: 29 patients (16 males, 13 females) with a mean age of 12.3 ± 1.5 years were treated with the MGBM, and 24 patients (11 males, 13 females) with a mean age of 11.3 ± 1.2 years were treated with the DS appliance. Demographics of observation periods and observation

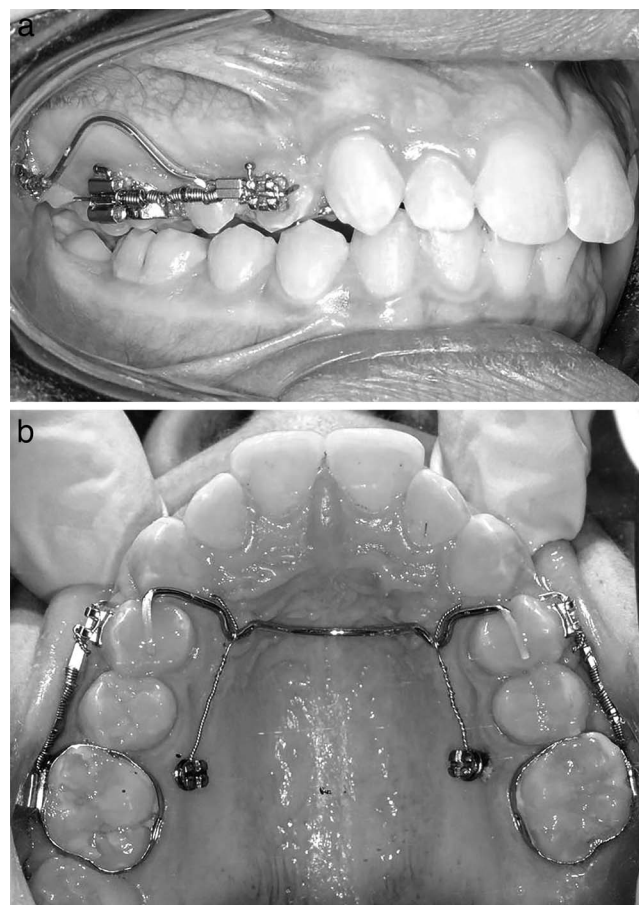


Figure 1. a-b. MGBM System.

interval are reported in Table 1. Initial traits of the subjects in both groups were considered comparable (Table 2). The average amounts of Class II molar relationship were 3.8 ± 1.2 mm in the MGBM group and 3.0 ± 0.4 mm in the DS group, with a mean overjet of 5.1 ± 1.8 mm and 4.8 ± 1.5 mm, respectively, at the

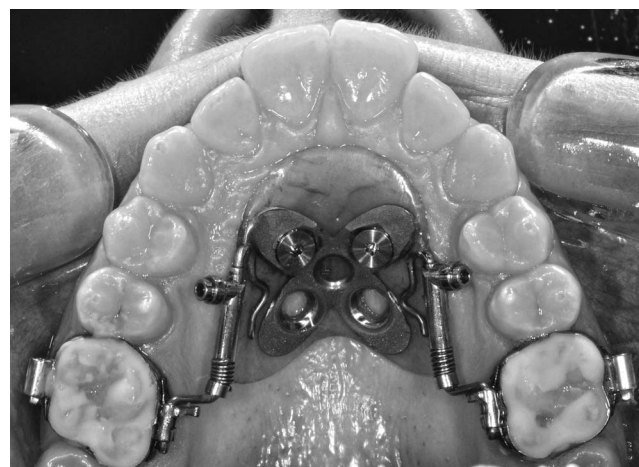

Figure 2. Distal Screw appliance.

Table 1. Demographics of Observation Periods and Observation Intervals^a

| Observation Period/Interval | MGBM Group (n = 29) | | | | Distal Screw Group (n = 24) | | | |
|-----------------------------|---------------------|----------|-----------|-----------|-----------------------------|----------|-----------|-----------|
| | Mean | SD | Min | Max | Mean | SD | Min | Max |
| T1 | 12 y 3 mo | 1 y 5 mo | 10 y 1 mo | 14 y 8 mo | 11 y 3 mo | 1 y 9 mo | 10 y 4 mo | 13 y 1 mo |
| T2 | 12 y 9 mo | 1 y 6 mo | 10 y 6 mo | 15 y 6 mo | 12 y 2 mo | 1 y 2 mo | 11 y 2 mo | 14 y 2 mo |
| T1-T2 | 6 mo | 3 mo | 4 mo | 10 mo | 9 mo | 2 mo | 4 mo | 11 mo |

^a SD indicates standard deviation; T1, pretreatment; and T2, postdistalization.

beginning of treatment. Lateral cephalograms for all patients were available at two observation times: before treatment (T1) and after the distalization phase (T2). Demographics of the observation period and observation interval are reported in Table 1.

Clinical Management

All patients underwent maxillary molar distalization therapy with two different appliances, the MGBM[™] and the DS appliance.¹³ The mean treatment time was 6 ± 2 months for MGBM and 9 ± 2 months for DS (Table 1). The end of distalization was signified by a slightly overcorrected Class I molar relationship in both groups. Dental and skeletal changes during fixed appliance therapy were not taken into consideration in order to highlight the differences between the two appliances during the distalizing phase.

Cephalometric Analysis

Lateral cephalograms for each patient at T1 and T2 in both treatment groups were standardized as the same magnification factor (6% enlargement). Cephalograms were hand-traced in random order by one investigator, with verification of anatomic outlines and landmark position by a second investigator. In case of disagreement, the structures in question were retraced

to the mutual satisfaction of both. In instances of bilateral structures (eg, gonial angle, teeth), a single averaged tracing was made. A modified Gosh and Nanda cephalometric analysis, as described in a previous article,¹⁶ was used. Cranial base superimpositions (CBS) were used to evaluate dentoalveolar, craniofacial, and soft tissue changes according to Bjork and Skieller.¹⁷ The cephalometric analysis consisted of 26 landmarks, 11 angular and 16 linear variables for each tracing (Figure 3a,b).

Maxillary superimposition (MS)¹⁷ was needed in order to assess dentoalveolar changes, since they could be influenced by the forward growth of the maxilla (Figure 3c). The palatal plane and a perpendicular line were used as horizontal and vertical reference planes, respectively, for measurements.

Statistical Analysis

Normal distribution of the data was determined by exploratory tests (Shapiro-Wilk). In order to compare pretreatment cephalometric data, an independent-samples Student's *t*-test was used before treatment. No significant difference between the two groups was found. Mean differences and confidence intervals were also calculated for the treatment changes between T1 and T2. A Student's *t*-test was used to identify

Table 2. Mean and Standard Deviation for Pretreatment Cephalometric Values in MGBM Group and DS Group^a

| Cephalometric Measurements | MGBM Group | Distal Screw Group | P-Value |
|---|-----------------|--------------------|---------|
| Sagittal skeletal relations | | | |
| Maxillary position S-N-A | 80.6 \pm 2.8 | 81.5 \pm 3.8 | .32 |
| Mandibular position S-N-Pg | 76.5 \pm 2.4 | 77 \pm 3.2 | .28 |
| Sagittal jaw relation A-N-Pg | 4.2 \pm 2.1 | 4.7 \pm 1.4 | .35 |
| Vertical skeletal relations | | | |
| Maxillary inclination S-N/ANS-PNS | 7.3 \pm 2.9 | 8.2 \pm 2.6 | .24 |
| Mandibular inclination S-N/Go-Gn | 31.2 \pm 3.8 | 31.6 \pm 6.3 | .78 |
| Vertical jaw relation ANS-PNS/Go-Gn | 24 \pm 2.6 | 23.5 \pm 3.6 | .63 |
| Dentobasal relations | | | |
| Maxillary incisor inclination | 114 \pm 6.4 | 112.7 \pm 7.3 | .25 |
| Mandibular incisor inclination L1-Go-Gn | 97.4 \pm 5.4 | 95.5 \pm 5.9 | .25 |
| Dental relations | | | |
| Overjet, mm | 5.1 \pm 1.8 | 4.8 \pm 1.5 | .85 |
| Overbite, mm | 4.8 \pm 2.2 | 4.1 \pm 2.1 | .25 |
| Interincisal angle U1-L1, ° | 127.5 \pm 3.4 | 130.3 \pm 4.2 | .02 |
| Molar relationship | 3.8 \pm 1.2 | 3.0 \pm 0.4 | .30 |
| Soft tissue | | | |
| Upper lip to E-plane, mm | -1.7 \pm 2.44 | -1.2 \pm 2.40 | .47 |
| Lower lip to E-plane, mm | 0.2 \pm 2.75 | 0.1 \pm 2.64 | .92 |

^a Student's *t*-test for independent samples at pretreatment (T1).

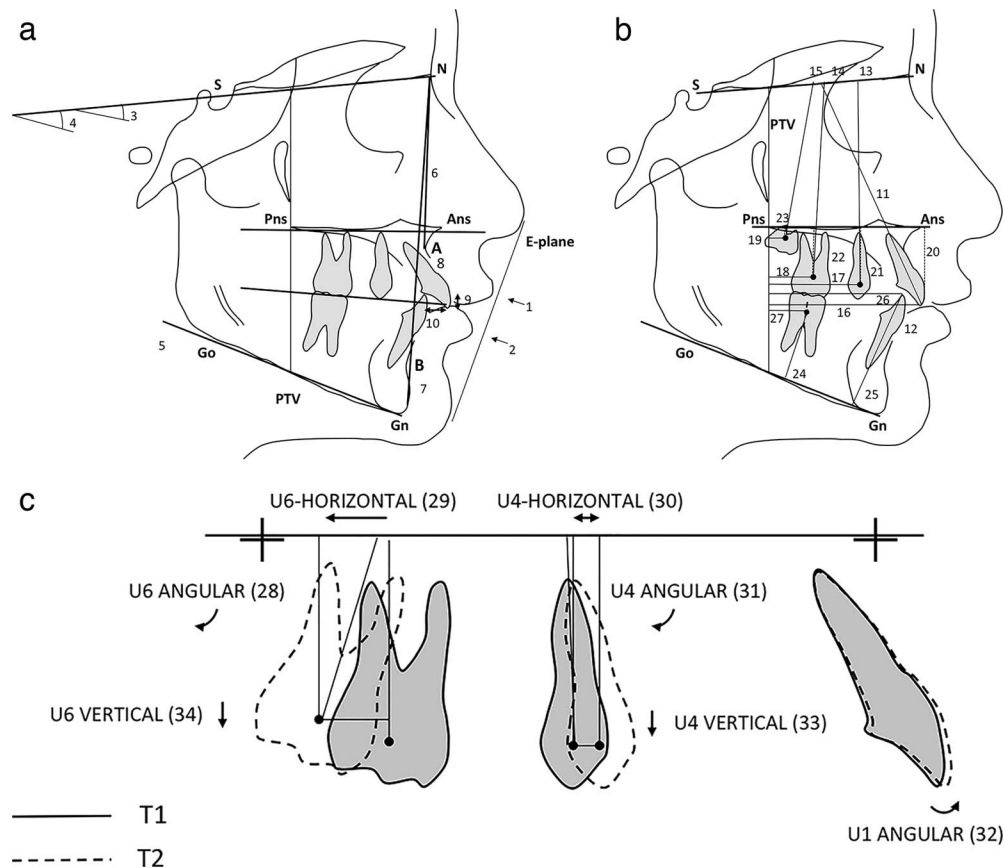


Figure 3. a. Cephalometric soft tissue and skeletal measurements used in the study: (1) upper lip to E-plane; (2) lower lip to E-plane; (3) SN–palatal plane angle; (4) SN–anatomic occlusal plane; (5) SN–mandibular plane angle; (6) SNA; (7) SNB; (8) ANB; (9) OVB; (10) OVJ. b. Cephalometric dental angular and linear measurements: (11) SN–maxillary incisor; (12) IMPA; (13) SN–maxillary first premolar; (14) SN–maxillary first molar; (15) SN–maxillary second molar; (16) PtV–maxillary incisor; (17) PtV–maxillary first premolar; (18) PtV–maxillary first molar; (19) PtV–maxillary second molar; (20) PP-U1; (21) PP-U4; (22) PP-U6; (23) PP-U7; (24) Mandibular plane–mandibular first molar; (25) Mandibular plane–mandibular incisor; (26) PtV–mandibular incisor; (27) PtV–mandibular first molar. PtV: pterygoid vertical plane. c. Linear and angular measurements on maxillary local tracing: (28) U6 angular (angle between long axis and a line passing through maxillary fiducial markers); (29) U6 horizontal; (30) U4 horizontal; (31) U4 angular; (32) U1 angular; (33) U4 vertical (perpendicular to a line passing through maxillary fiducial markers); (34) U6 vertical.

significant between-groups differences for each cephalometric variable between T1 and T2 using a statistical software package (MedCalc® Version 11.1.1.0, Mariakerke, Gent, Belgium). A Pearson correlation coefficient was also calculated to identify the statistical correlation between the two groups comparing dental measurements on cranial base superimposition and maxillary superimposition. Statistical significance was tested at $P < .05$, $P < .01$, and $P < .001$.

Method Error

Fifteen randomly selected cephalograms were re-traced by the same author after a period of 2 months. No significant mean differences between the two series of records were found using the paired t -test. Dahlberg's Formula¹⁸ was used to establish the method error. Ranges from 0.4 to 0.7 mm for linear measurements and from 0.5° to 0.8° for angular

measurements were found. The reliability coefficients (r)¹⁹ ranged from 0.94 to 0.98 and from 0.92 to 0.97, respectively.

RESULTS

Descriptive statistics comparing MGBM and DS groups before treatment (Table 2) did not show statistically significant differences in soft tissue, skeletal, and dental measurements.

Pretreatment to Postdistalization (T1-T2)

No significant sagittal or vertical skeletal change was detected between the two groups during the distalization phase (T1-T2). There was a slight opening of the mandibular plane angle in both groups, 1° (95% confidence interval [CI] = 0.4, 1.6) in MGBM and 1.5° (95% CI = 0.8, 2.3) in DS, but these differences were not statistically significant.

Table 3. Mean and Confidence Interval (CI) for Soft Tissue and Skeletal Changes of Cephalometric Values During Distalization Period (T1 to T2) Relative to Cranial Base Superimposition (CBS)^a

| | MGBM Group | | Distal Screw Group | | P-Value |
|-----------------------------------|------------|-----------|--------------------|-----------|---------|
| | Mean | 95% CI | Mean | 95% CI | |
| Soft tissue | | | | | |
| Upper lip to E-plane, mm | 0.4 | -0.1, 0.9 | 0.1 | -0.7, 0.9 | .43 |
| Lower lip to E-plane, mm | -0.1 | -0.9, 0.7 | -0.1 | -0.7, 0.5 | .95 |
| Sagittal skeletal relations | | | | | |
| Maxillary position S-N-A | 0.4 | 0.0, 2.0 | 0.4 | 0.0, 2.0 | .65 |
| Mandibular position S-N-B | -0.5 | -2.0, 0.0 | 0.2 | -1.0, 2.0 | .20 |
| Sagittal jaw relation A-N-B | 0.8 | -1.0, 2.0 | 0.7 | -2.0, 1.3 | .58 |
| Vertical skeletal relations | | | | | |
| Maxillary inclination S-N/ANS-PNS | 0.5 | -0.1, 1.0 | 0.2 | -0.3, 0.7 | .31 |
| Occlusal plane inclination SN-OCL | 0.7 | 0.1, 1.3 | 0.5 | -0.1, 1.3 | .86 |
| Mandibular inclination S-N/Go-Gn | 1.0 | 0.4, 1.6 | 1.5 | 0.8, 2.3 | .48 |

^a Student's *t*-test for independent samples at pretreatment (T1)-postdistalization (T2).

The maxillary first molar showed greater distal movement in MGBM (5.2 mm; 95% CI = -6.2, -4.3) than in DS (2.6 mm; 95% CI = -3.2, -2.0) ($P < .001$); however, a greater amount of distal tipping was noted in MGBM (10.4°; 95% CI = -12.5, -8.3) than in DS (3.1°; 95% CI = -6.3, -1.6) ($P < .001$). Moreover, MGBM resulted in molar intrusion (-1.2 mm; 95% CI = -1.5, -0.9), whereas DS resulted in a slight extrusion (0.3 mm; 95% CI = -0.1, 0.7) of maxillary first molar ($P < .0001$).

The maxillary first premolar showed a mean mesial movement of 1.8 mm (95% CI = 1.1, 2.7), with a concomitant mesial tipping of 4.3° (95% CI = 1.6,

7.0) in MGBM, whereas distal premolar movement of 1.9 mm (95% CI = -2.7, -1.1) and distal tipping of 8.1° (95% CI = -10.6, -5.5) were noted in DS ($P < .001$). Accordingly, the maxillary incisor proclined 1.8° (95% CI = -0.1, 3.6) in MGBM, whereas it did not significantly change in DS (-0.3°; 95% CI = -1.2, 1.7) during the distalization phase.

Overjet increased both in MGBM (0.8 mm; 95% CI = 0.3, 1.4) and in DS (0.7 mm; 95% CI = 0.2, 1.2), as did the overbite, which decreased both in the MGBM (-1.0 mm; 95% CI = -1.7, -0.3) and in the DS (-0.8 mm; 95% CI = -1.4, 0.7), but these changes were not statistically significant.

Table 4. Mean and Confidence Interval (CI) for Dentoalveolar Changes of Cephalometric Values During Distalization Period (T1 to T2) Relative to Cranial Base Superimposition (CBS)^a

| | MGBM Group | | Distal Screw Group | | P-Value |
|-------------------------------------|------------|-------------|--------------------|-------------|---------|
| | Mean | 95% CI | Mean | 95% CI | |
| Dentobasal relations | | | | | |
| Maxillary incisor inclination SN-U1 | 1.8 | -0.1, 3.6 | -0.3 | -1.2, 1.7 | .16 |
| Mandibular incisor inclination IMPA | 1.4 | -0.4, 3.3 | 0.9 | 1.6, 0.7 | .12 |
| Dental relations | | | | | |
| Overjet, mm | 0.8 | 0.3, 1.4 | 0.7 | 0.2, 1.2 | .86 |
| Overbite, mm | -1.0 | -1.7, -0.3 | -0.8 | -1.4, 0.7 | .75 |
| Maxillary dentoalveolar | | | | | |
| SN-U4, ° | 4.3 | 1.6, 7.0 | -8.1 | -10.6, -5.5 | <.001 |
| SN-U6, ° | -10.4 | -12.5, -8.3 | -3.1 | -6.3, -1.6 | <.001 |
| SN-U7, ° | -11.2 | -13.7, -8.7 | -4.2 | -6.4, -1.9 | .002 |
| PtV-U1, mm | 1.7 | 0.9, 2.4 | 0.2 | -0.5, 1.4 | .08 |
| PtV-U4, mm | 1.8 | 1.1, 2.7 | -1.9 | -2.7, -1.1 | <.001 |
| PtV-U6, mm | -5.2 | -6.2, -4.3 | -2.6 | -3.2, -2.0 | <.001 |
| PtV-U7, mm | -5.1 | -6.0, -4.2 | -2.9 | -3.8, -2.1 | .002 |
| PP-U1, mm | 0.2 | -0.3, 0.7 | 0.5 | 0.2, 0.8 | .31 |
| PP-U4, mm | 1.5 | 0.8, 2.2 | 1.3 | 0.4, 2.3 | .72 |
| PP-U6, mm | -1.2 | -1.5, -0.9 | 0.3 | -0.1, 0.7 | <.001 |
| PP-U7, mm | -1.2 | -2.3, -0.1 | 1.5 | 0.5, 0.9 | .001 |
| Mandibular dentoalveolar | | | | | |
| PtV-L1, mm | 0.7 | -0.2, 1.6 | 0.1 | -0.8, 0.9 | .29 |
| PtV-L6, mm | 0.8 | 0.1, 1.6 | 0.7 | 0.1, 1.4 | .82 |
| MANDPLANE-L6, mm | 1.4 | 0.9, 1.9 | 0.7 | 0.1, 1.3 | .06 |
| MANDPLANE-L1, mm | 0.9 | 0.5, 1.4 | 1.1 | 0.6, 1.5 | .71 |

^a Student's *t*-test for independent samples at pretreatment (T1)-postdistalization (T2).

Table 5. Mean and Confidence Interval (CI) for Changes of Cephalometric Dental Values During Distalization Period (T1 to T2) Relative to Maxillary Superimposition (MS)^a

| | MGBM Group | | Distal Screw Group | | P-Value |
|---------------|------------|-------------|--------------------|-------------|---------|
| | Mean | 95% CI | Mean | 95% CI | |
| U4-HORIZONTAL | 1.4 | 0.7, 2.1 | -2.2 | -2.9, -1.6 | <.001 |
| U6-HORIZONTAL | -5.5 | -6.4, -2.7 | -3.2 | -3.9, -2.4 | .001 |
| PP-U4 ANGULAR | 4.4 | 1.9, 6.8 | -6.2 | -10.8, -3.8 | <.001 |
| PP-U6 ANGULAR | -10.3 | -13.4, -7.6 | -3.0 | -4.8, -1.9 | <.001 |
| PP-U1 ANGULAR | 1.6 | 0.03, 3.2 | -0.3 | -1.1, 1.8 | .27 |
| U4-VERTICAL | 1.4 | 0.7, 2.1 | 1.1 | 0.3, 2.0 | .76 |
| U6-VERTICAL | -1.0 | -1.3, -0.7 | 0.2 | -0.1, 0.5 | <.001 |

^a Student's *t*-test for independent samples at pretreatment (T1)-postdistalization (T2).

Soft tissues did not show any significant change in both groups. The upper lip moved slightly forward relative to the E-plane in both MGBM and DS, whereas the lower lip was insignificantly retroclined in both groups (Tables 3 and 4).

Comparison Between CBS and MS Relative to Maxillary Dentoalveolar Changes During Distalization-Phase (T1-T2)

No significant difference in vertical and angular measurements was detected in the maxillary molar, premolar, and incisor between CBS and MS. Only a slight difference in horizontal movements relative to the molar (CBS: -5.2 mm MGBM; -2.6 mm DS; MS: -5.5 mm MGBM; -3.2 mm DS) and premolar (CBS: 1.8 mm MGBM; -1.9 mm DS; MS: 1.4 mm MGBM; -2.2 mm DS) was noted, but these changes were not clinically significant (Tables 5 and 6).

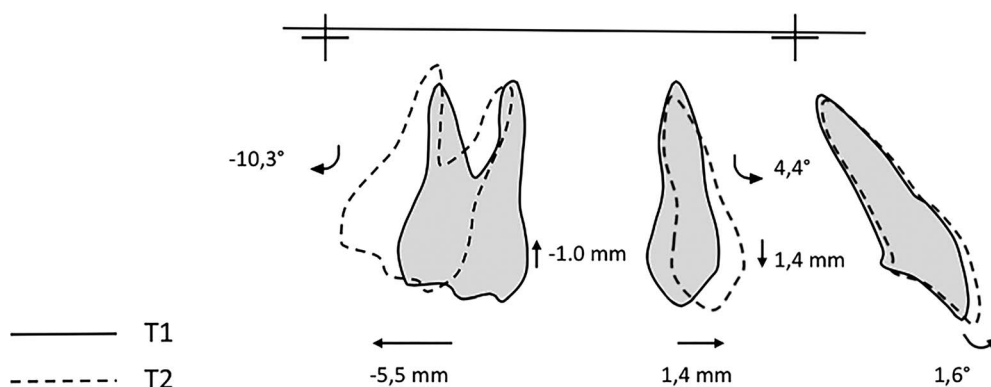
DISCUSSION

Initial cephalograms revealed that patients in both groups were in general not substantially different, confirming that this study had a low susceptibility bias (Table 2). Both the MGBM and DS successfully distalized maxillary molar to a Class I molar relationship; however, the different designs of the appliances

could lead to different dental movements. MGBM showed a greater amount of molar distalization (-5.5 mm; 95% CI = -6.4, -2.7) and less distalization time (6 ± 2 months), which resulted in a higher efficiency of the MGBM compared with the DS (0.91 mm/mo vs 0.35 mm/mo); however, it should be underlined that a distalization with crown tipping can have less resistance to the movement, resulting in less treatment time, but can also be heading for greater anchorage requirements during the subsequent phase of fixed appliances therapy and major risk of relapse.

In fact, a significant distal crown tipping (-10.3° ; 95% CI = -13.4, -7.6) also occurred, even if the subsequent use of buccal miniscrews during fixed appliance therapy in the MGBM group could lead to avoidance of the risk of relapse toward a Class II or anchorage loss.²⁰

On the contrary, DS showed greater distalization time²¹ (9 ± 2 months) and a smaller amount of molar distalization (3.2 mm), but a more bodily distalization (-3° ; 95% CI = -4.8, -1.9), possibly as a result of the rigidity of the appliance, which, acting as the Distal Jet,³ was able to direct the force in proximity to the center of resistance of the first molar exploiting the bayonet bend and telescopic rigid arms (Figure 2).

**Figure 4.** Graphic representation of maxillary superimposition for MGBM group showing dentoalveolar changes during the distalization phase (T1-T2).

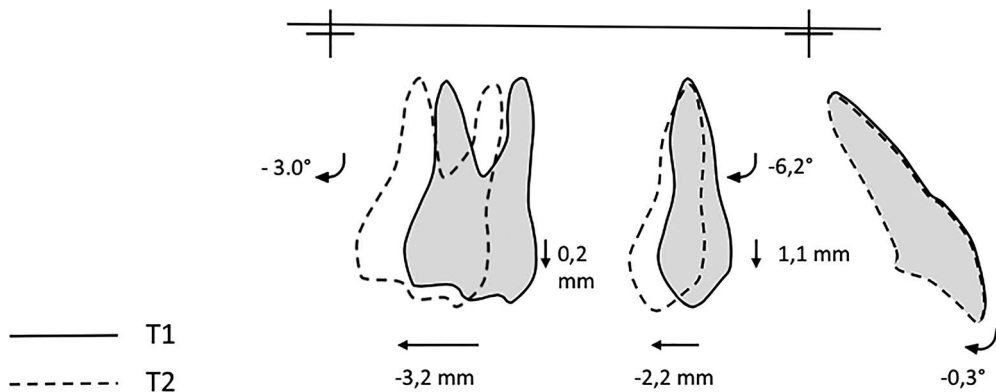


Figure 5. Graphic representation of maxillary superimposition for Distal Screw group showing dentoalveolar changes during the distalization phase (T1-T2).

However, the main difference between MGBM and DS was represented by the premolar movement (Figures 4 and 5). MGBM, using an indirect skeletal anchorage,¹⁰ could not provide absolute anchorage because of the low rigidity of the metallic ligatures, so that the premolar showed a small mesial movement of 1.4 mm (95% CI = 0.7, 2.1) and the incisors showed a slight proclination of 1.6° (95% CI = 0.3, 3.2) after the distalization phase. Moreover, Liou et al.²² reported that the absence of osseointegration and the bone elasticity could lead to a certain mobility of the miniscrews, which, while not necessarily compromising the final outcome,²³ could result in anchorage loss regardless of whether the screws are indirectly connected to the anchorage unit. Similar findings were reported by Gelgor et al.,²⁴ who showed 3.2 ± 3.3 mm premolar mesial movement using a transpalatal bar on the premolar connected to a midpalatal miniscrew.

As stated by Grec et al.,¹⁰ only direct skeletal anchorage can provide absolute anchorage, and spontaneous distal premolar movement could also be observed. Accordingly, our study showed that premolars were distally pulled by the transseptal fibers during distalization of the first molar (−2.2 mm; 95% CI = −2.9, −1.6). However, unlike the first molar, the premolar showed a consistent distal tipping (−6.2°; 95% CI = −9.1, −3.4), likely because the transseptal fibers acted mainly on the dental crowns, leaving the root apex position substantially unchanged before and after distalization. Our findings confirmed the results

previously described by Cozzani et al.¹³ using DS (premolar distal tipping of −3.0°) and Sar et al.²⁵ (−4.9°) and Polat-Oszozy²⁶ (−6.8°) using the Bone Anchored Pendulum Appliance. Although only the premolar crown spontaneously distalized, this might facilitate the retraction of the premolar and canine during fixed appliance therapy. However, the use of direct anchorage in the DS group resulted in a major bulk of the appliance being placed in the palatal vault, and this could possibly result in speech- and oral hygiene–related problems.

Most of the articles dealing with molar distalization used CBS and the pterygoid vertical plane (PtV) line for measurements. Dentoalveolar effects of a distalizing device could be wrongly assessed by CBS in growing subjects; in addition, forward growth of the maxilla could lead to misleading results and represent a measurement bias.²⁷ For this reason, in our study dentoalveolar maxillary measurements traced by the CBS were compared to MS. No significant differences in vertical and angular measurements were detected (Table 6). Only a slight difference in horizontal movements relative to the molar and premolar was noted, so that CBS could underestimate the amount of molar distalization and overestimate the premolar anchorage loss, but these changes were not clinically significant.

The retrospective study and the analysis focusing primarily on the changes before and after the distalization phase can be considered weaknesses of this study. However, all patients treated with these

Table 6. Comparison Between Data Obtained from Cranial Base Superimposition (CBS) and Maxillary Superimposition (MS)^a

| | MGBM Group | | Distal Screw Group | |
|------------------------|-------------|---------|--------------------|---------|
| | Correlation | P-Value | Correlation | P-Value |
| ΔSN-U4–ΔPP-U4 | 0.92 | <.001 | 0.94 | <.001 |
| ΔSN-U6–ΔPP-U6 | 0.94 | <.001 | 0.92 | <.001 |
| ΔPtV-U4–ΔU4-HORIZONTAL | 0.82 | <.001 | 0.84 | <.001 |
| ΔPtV-U6–ΔU6-HORIZONTAL | 0.93 | <.001 | 0.80 | .001 |

^a Pearson correlation test.

mechanics were included in the study in order to avoid selection bias and the possibility of choosing some patients and screening out others, reducing the risk of influencing the final outcomes.

Further long-term prospective studies should be conducted in order to confirm our results and to report data at the end of orthodontic treatment or long-term follow-up. Moreover, since mesial molar rotation is often present before treatment in Class II patients, another interesting topic to investigate might be the effect of buccal or palatal mechanics on molar rotation during the distalization phase based on analysis of data measured on plaster casts.

CONCLUSIONS

- The null hypothesis was rejected.
- MGBM resulted in less distalization time and a greater amount of molar distalization than did DS.
- MGBM resulted in more efficient movement than did DS during the distalization phase, but it also presented greater molar distal tipping, premolar mesial movement, and a slight incisor proclination.
- Spontaneous distal drifting of the premolar and no substantial changes at the maxillary incisor were noted in the DS group.
- No significant vertical changes were observed during distalization in either group.

REFERENCES

1. Fontana M, Cozzani M, Caprioglio A. Non compliance maxillary molar distalizing appliances: an overview of the last decade. *Prog Orthod.* 2012;13:173–184.
2. Hilgers JJ. The pendulum appliance for Class II non-compliance therapy. *J Clin Orthod.* 1992;26:700–713.
3. Carano A, Testa M. The distal jet for upper molar distalization. *J Clin Orthod.* 1996;30:374–380.
4. Locatelli R, Bednar J, Dietz VS, Gianelly A. Molar distalization with superelastic NiTi wire. *J Clin Orthod.* 1992;26:277–279.
5. Caprioglio A, Fontana M, Longoni E, Cozzani M. Long-term evaluation of the molar movements following Pendulum and fixed appliances. *Angle Orthod.* 2013;83:447–454.
6. Costa A, Raffaini M, Melsen B. Miniscrews as orthodontic anchorage: a preliminary report. *Int J Orthod Orthognath Surg.* 1998;13:201–209.
7. Ludwig B, Glasl B, Bowman SJ, Wilmes B, Kinzinger GS, Lisson JA. Anatomical guidelines for miniscrew insertion: palatal sites. *J Clin Orthod.* 2011;45:433–441.
8. Gracco A, Lombardo L, Cozzani M, Siciliani G. Quantitative cone-beam computed tomography evaluation of palatal bone thickness for orthodontic miniscrew placement. *Am J Orthod Dentofacial Orthop.* 2008;134:361–369.
9. Poggio PM, Incorvati C, Velo S, Carano A. Safe zone: a guide for miniscrew positioning in the maxillary and mandibular arch. *Angle Orthod.* 2006;76:191–197.
10. Grec RH, Janson G, Branco NC, Moura-Grec PG, Patel MP, Castanha Henriques JF. Intraoral distalizer effects with conventional and skeletal anchorage: a meta-analysis. *Am J Orthod Dentofacial Orthop.* 2013;143:602–615.
11. Maino BG, Gianelly A, Bednar J, Mura P, Maino G. MGBM system: new protocol for Class II non extraction treatment without cooperation. *Prog Orthod.* 2007;8:130–143.
12. Maino G, Mariani L, Bozzo I, Maino G, Caprioglio A. Maxillary molar distalization with MGBM-system in Class II malocclusion. *J Orthod Sci.* 2013;2:101–108.
13. Cozzani M, Zallio F, Lombardo L, Gracco A. Efficiency of the distal screw in the distal movement of maxillary molars. *World J Orthod.* 2010;11:341–345.
14. Cozzani M, Pasini M, Zallio F, et al. Comparison of maxillary molar distalization with an implant-supported distal jet and a traditional tooth-supported distal jet appliance. *Int J Dent.* 2014;937059. doi:10.1155/2014/937059 [Epub 2014 Jun 11].
15. Arnett GW, Gunson MJ. Facial planning for orthodontists and oral surgeons. *Am J Orthod Dentofacial Orthop.* 2004;126:290–295.
16. Fontana M, Cozzani M, Caprioglio A. Soft tissue, skeletal and dentoalveolar changes following conventional anchorage molar distalization therapy in non-growing subjects: a multicentric study. *Prog Orthod.* 2012;13:30–41.
17. Bjork A, Skieller V. Normal and abnormal growth of the mandible: a synthesis of longitudinal cephalometric implant studies over a period of 25 years. *Eur J Orthod.* 1983;5:1–46.
18. Dahlberg G. *Statistical Methods for Medical and Biological Students.* London, UK: Allen and Unwin; 1940:122–132.
19. Houston WBJ. The analysis of errors in orthodontic measurements. *Am J Orthod.* 1983;83:382–390.
20. Mariani L, Maino G, Caprioglio A. Skeletal versus conventional intraoral anchorage for treatment of Class II malocclusion: dentoalveolar and skeletal effects. *Prog Orthod.* 2014;15:43 [Epub ahead of print].
21. Chiu P, McNamara J, Franchi L. A comparison of two intraoral molar distalization appliances: distal jet versus pendulum. *Am J Orthod Dentofacial Orthop.* 2005;128:353–365.
22. Liou EJ, Pai BC, Lin JC. Do miniscrews remain stationary under orthodontic forces? *Am J Orthod Dentofacial Orthop.* 2004;126:42–47.
23. Park HS, Jeong SH, Kwon OH. Factors affecting the clinical success of screw implants used as orthodontic anchorage. *Am J Orthod Dentofacial Orthop.* 2006;130:18–25.
24. Gelgor I, Karaman AI, Buyukyilmaz T. Comparison of 2 distalization systems supported by intraosseous screws. *Am J Orthod Dentofacial Orthop.* 2007;131:161.e1–161.e8.
25. Sar C, Kaya B, Ozsoy O, Ozcirpici AA. Comparison of two implant-supported molar distalization systems. *Angle Orthod.* 2013;83:460–467.
26. Polat-Ozsoy O, Kircelli BH, Arman-Ozcirpici A, Pektas ZO, Uckan S. Pendulum appliances with 2 anchorage designs: conventional anchorage vs bone anchorage. *Am J Orthod Dentofacial Orthop.* 2008;133:339.e9–339.e17.
27. Caprioglio A, Cozzani M, Fontana M. Comparative evaluation of molar distalization therapy with erupted second molars: Segmented versus Quad Pendulum appliance. *Prog Orthod.* 2014;15:49 [Epub ahead of print].