

Three-dimensional analyses of palatal morphology and its relation to upper airway area in obstructive sleep apnea

Defne Kecik^a

ABSTRACT

Objective: To evaluate the relationship between palatal morphology and pharyngeal airway morphology in patients who have obstructive sleep apnea (OSA) and compare with a nonsnoring and nonapneic control group.

Materials and Methods: Three-dimensional maxillary dental cast measurements from 25 OSA patients (6 women, 19 men) with a mean age of 41.5 (4.8) years, and 25 control group participants (14 women, 11 men) without any symptom of OSA with a mean age of 38.3 (3.7) were correlated with an analysis of pharyngeal area evaluated with lateral cephalograms. Intermolar and intercanine widths and palatal volumes were calculated on the dental casts, and the upper airway area measurements were performed on lateral cephalograms.

Results: OSA patients had smaller oropharyngeal volume and upper airway when compared with controls ($P < .001$). Palatal area measurements were significantly smaller in OSA ($P < .001$). OSA patients had significantly narrower maxilla with smaller intermolar and intercanine widths ($P < .001$). A positive correlation was found between the palatal morphology and pharyngeal dimensions.

Conclusions: A significant correlation exists between palatal morphology and pharyngeal airway. (*Angle Orthod.* 2017;87:300–306)

KEY WORDS: Obstructive sleep apnea; Palatal volume; Upper airway; 3D volumetric analysis

INTRODUCTION

Obstructive sleep apnea (OSA) is defined as a frequent and common respiratory disease characterized by repeated episodes of the obstruction of the upper airways that could be life threatening, associated with daytime dysfunction, excessive daytime sleepiness, reduced quality of life, accidents, stroke, and cardiovascular mortality and morbidity.^{1,2} OSA is characterized by the repetitive collapse and reopening of the upper airway during sleep, impairing oxygenation and resulting in intermittent hypoxemia and hypercapnia.³

Gender, age, and body mass index are directly related to OSA, which has a prevalence of 24% in men and 9% in women between 30 to 70 years of age.²

OSA pathogenesis is related to the characteristics of airway anatomy, morphology, and soft tissue structures; narrow upper airway space; reduced activity of the upper airway dilator muscles; ventilator control insufficiency; abnormalities of the facial skeleton; enlarged soft tissues; and neuromuscular factors.^{4–6}

Anatomical factors such as increased airway distance, wall thickness, and tongue volume are associated with OSA.⁷ Reduced maxillo-mandibular dimensions can result in reduced airway size, and the pharyngeal morphology shows a continuous change throughout adult life.⁸ Craniofacial characteristics associated with OSA include maxillo-mandibular skeletal morphology, cranial base, hyoid position, tongue volume, head position, and upper airway soft tissue size.^{5–9} The most common features are the differences in maxillo-mandibular morphology. A shorter, narrower, and tapered maxillary arch with a mandibular deficiency is associated with OSA.^{10–13} Electromyography and fiberoptic endoscopy evaluation show a loss of pharyngeal muscle tonus while

^a Associate Professor, Department of Orthodontics, Faculty of Dentistry, Baskent University, Istanbul, Turkey.

Corresponding author: Dr Defne Kecik, Department of Orthodontics, Faculty of Dentistry, Baskent University Mahir İzceddesi No:43 Altunizade, Istanbul, Turkey (e-mail: defnekecik@gmail.com)

Accepted: July 2016. Submitted: May 2016.

Published Online: September 13, 2016

© 2017 by The EH Angle Education and Research Foundation, Inc.

sleeping, resulting in the partial or complete obstruction of the oropharyngeal airway.¹⁴

The aim of this study is to investigate if a difference between the palatal morphologies of OSA and control patients and evaluate if a correlation exists among the palatal volume and upper airway morphology.

MATERIALS AND METHODS

This clinical retrospective study was approved by Institutional Review Board and Ethical Committee of Başkent University, assigned as D-KA16/11.

The sample consisted of 50 patients from the archives of the Başkent University Faculty of Dentistry Department of Orthodontics in Istanbul Hospital. A total of 25 nonobese patients (6 women, 19 men) with a mean age of 41.5 (4.8) years (minimum 29.8, maximum 57.3 years) who had OSA with no craniofacial deformity were evaluated by an ear, nose, and throat specialist and chest specialist, and those indicated with OSA were selected. The study group participants were selected from the patients who were admitted to the Sleep Disorder Clinic of Başkent University Istanbul Hospital with complaints of restlessness, fatigue, or insomnia symptoms and/or with reported breathing interruptions by the bed partner. Full-night polysomnography was conducted for all patients. Patients with an Apnea-Hypopnea Index of 5 or more per hour were diagnosed as having OSA.

The control group consisted of 25 participants (14 women, 11 men) without any history of respiratory problems or craniofacial deformity and with a class I skeletal relationship at a mean age of 38.3 (3.7) years (minimum 26.6, maximum 54 years). The control group participants had an Apnea-Hypopnea Index of <5 per hour.

Inclusion and exclusion criteria were the following: Participants older than 20 years of age with angle class I and full permanent teeth eruption including second molars were included; participants with cardiovascular disease, diabetes, chronic obstructive or restrictive lung diseases, a previous history of pharyngeal surgery or tonsillectomy, craniofacial deformity, or cleft lip and palate were excluded. Basic demographic information, medical comorbidities, and medication information were obtained from self-reported checklists for medical history and medical records.

All patients had maxillary dental casts and standardized lateral cephalometric radiographs. Nasopharyngeal, oropharyngeal, and soft palate areas were evaluated. The nasopharyngeal area is the area bordered at the top with the line connecting the adenoid tissue upper point and the posterior nasal spine. The lower border is the line passing through the Xi point parallel to the Frankfort horizontal plane. The

anterior border is the posterior border of the soft palate, and the posterior border is the posterior pharyngeal wall. The oropharyngeal area is outlined by the inferior border of nasopharyngeal area and the posterior surface of the soft palate, extending through the line passing through the tip of the epiglottis parallel to the Frankfort horizontal plane. The soft palate area is shown as the area confined by the outline of the soft palate that starts and ends at the posterior nasal spine on the lateral cephalograms (Figure 1). Area measurements are performed with the software Image J 1.38e (Image Processing and Analysis in Java; National Institutes of Health, Bethesda, Md.).

Plaster models of the maxillary arch were analyzed for intercanine and intermolar widths and palatal volume. Intercanine width was digitally measured by Orthomodel V2.0.206 (Orthomodel, Istanbul, Turkey) from the upper right cusp tips to the left canines. The intermolar width was measured with the same method from the mesiobuccal cusp tips of each side of the first molars (Figure 2).

Three-dimensional (3D) scanning of the models was performed by 3Shape Dental System D 640 (3Shape A/S, Copenhagen, Denmark), with an accuracy of 15 μ m; they were analyzed by Mimics 14 (Materialise, Leuven, Belgium).

As described by Primozic et al.,¹⁵ dental casts were precisely evaluated to avoid unwanted data. To define the borders of palatal volume, the digitizing process was based on the method of Lione et al.¹⁶

The gingival plane was constructed by connecting the line of the dento-gingival junction of all erupted teeth. The distal border was perpendicular to the dento-gingival plane, passing from the two most distal points corresponding to the distal surfaces of the second permanent molars. The palatal vault was the cranial border of the 3D image (Figure 3a–d).

Statistical Analysis

The statistical analysis was performed using the Statistical Package for Social Sciences version 22.0 software (IBM Corp., Armonk, N.Y.). Normal distribution of the variables was verified by the Shapiro–Wilks test. Descriptive analyses for normally distributed parameters are presented as means and standard deviations among the study groups. The homogeneity of variances was assessed with the Levene test.

To define the method reliability among the dental casts, 20 of them were redigitized by the same examiner after 2 weeks. A paired-sample *t*-test was performed to compare two measurements, indicating an insignificant error between two sets of casts within the limits of 0.90–0.93.

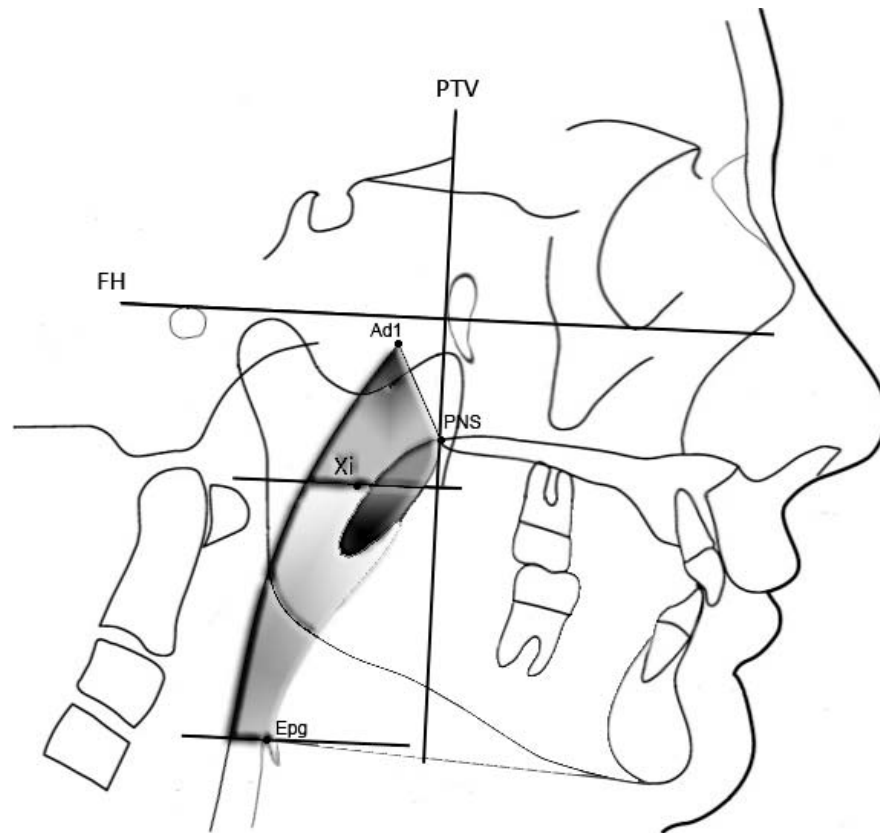


Figure 1. Diagrammatic representation of landmarks and tracings of the nasopharynx, oropharynx, and soft palate. Ad1 indicates upper point of adenoid tissue; PNS, posterior nasal spine; Epg, tip of epiglottis; Xi, geographic center of ramus; PTV, pterygoid vertical plane; FH, Frankfort horizontal plane; soft palate area, soft palate that starts and ends at PNS; nasopharynx, area outlined between the line passing through Ad1 point to the PNS, extension of the palatal plane to posterior pharyngeal wall and posterior pharyngeal wall; oropharynx, area outlined by the inferior border of nasopharynx, the posterior and inferior surface of soft palate, the line parallel to the FH plane through point Epg.

Airway measurements on the lateral cephalograms were compared using Student's *t*-tests. Two weeks later, a paired-sample *t*-test was performed to remeasure 20 randomly selected head films. The difference

was insignificant (0.89–0.95) and within acceptable limits.

The estimates are based on the pilot study, including 10 patients in each group. A sample size of 21 patients was detected to allow for a type II error level of $\beta = .20$ (80% power) and a type I error level of $\alpha = .05$ (5% probability). To account for possible dropouts, 25 patients were included in each group. The power calculation yielded the power of variables as 99% to detect the differences in the two groups.

The correlation between the lateral cephalograms and the dental casts were performed with the Pearson correlation test.

RESULTS

There was no systematic error between repeated digital measurements. The mean random error for palatal volume was 83 mm³, within acceptable limits. A total of 20 randomly selected cephalograms were remeasured 2 weeks after the first digitization. Paired-sample *t*-tests were applied, and the difference was insignificant (0.83–0.94), within acceptable limits.

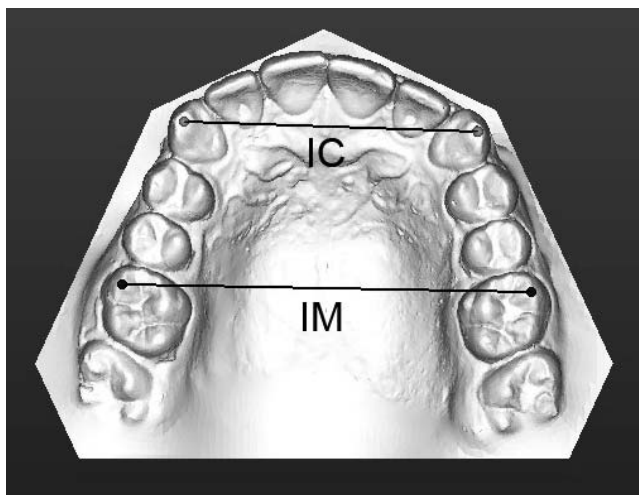


Figure 2. The intercanine (IC) and intermolar (IM) distances on the digital models.

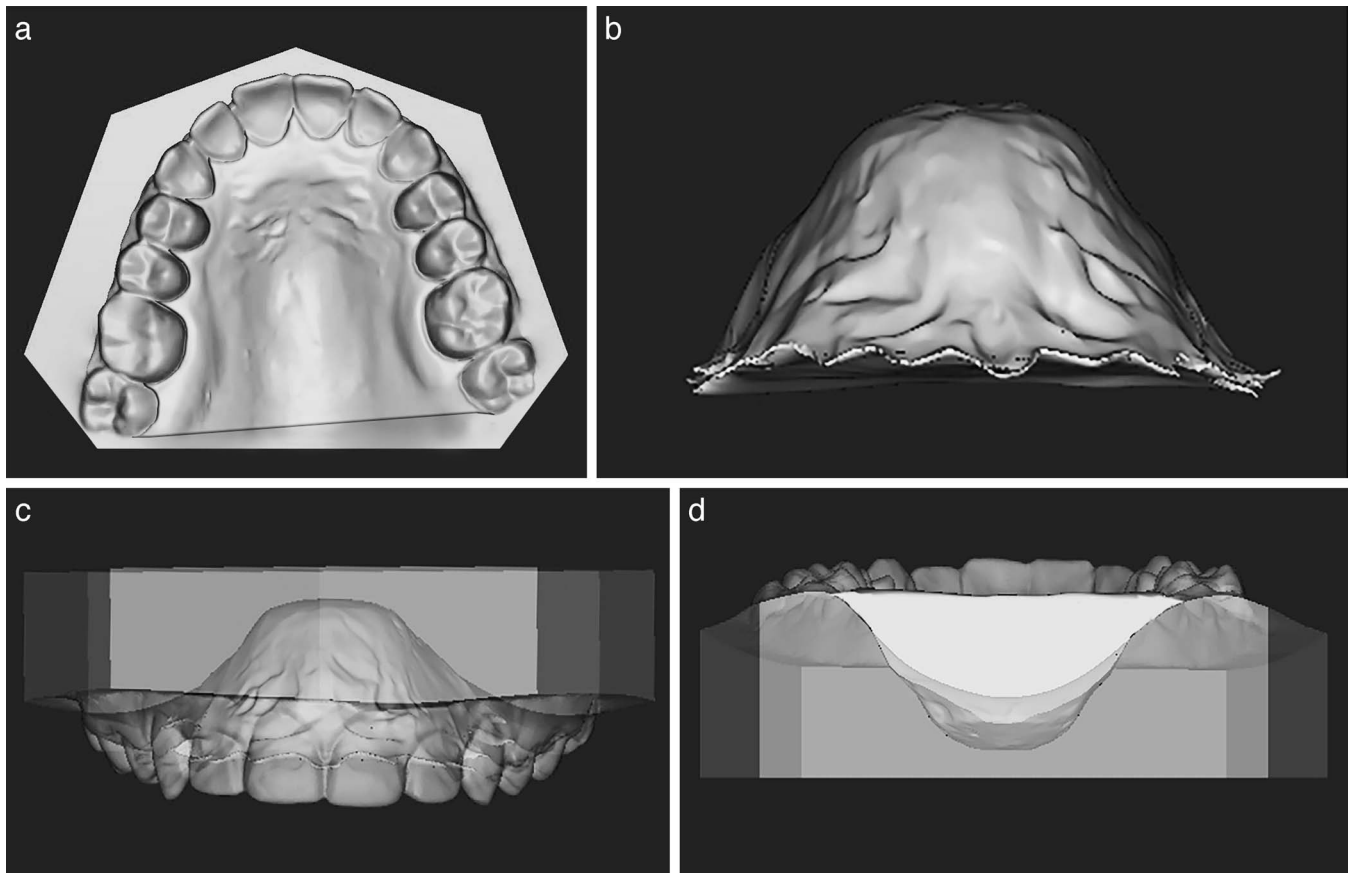


Figure 3. Palatal volume is defined as shown (a–d). Gingival plane was constructed by connecting the line of the dento-gingival junction of all erupted teeth. The distal plane is constructed perpendicular to the dento-gingival plane passing from two most distal points corresponding to the distal surface of the second molar teeth. The palatal vault is the cranial border of the three-dimensional image. (a) The palatal aspect. (b) The overall volumetric image distracted from the dental model image. (c) The facial aspect. (d) The posterior aspect of the palatal volumetric analysis.

Demographic data of the ages are shown in Table 1. Descriptive statistics and intergroup differences of palatal volume are given in Table 2.

The intercanine width between groups showed no statistical difference ($P > .05$). However, the intermolar width of the OSA group was significantly smaller than controls ($P < .001$). The palatal volume was significantly smaller in the OSA group ($P < .001$). The soft palate area of the OSA group was significantly larger

than the controls ($P < .01$). The nasopharyngeal and oropharyngeal areas were significantly smaller when compared with controls ($P < .001$).

There was a significant negative correlation between the soft palate area and palatal volume in the OSA group ($P = .000$; $r = -.943$; P , significance; r , Pearson correlation coefficient). The correlation between the nasopharyngeal area and the palatal volume was significantly positive ($P = .000$; $r = .874$). There was also a positive significant correlation between the oropharyngeal area and the palatal volume ($P = .000$; $r = .848$).

Table 1. Demographics of the Ages of the Patients of the Two Groups^a

	Min	Max	Mean	SD
OSA				
Females (n = 6)	29.2	58.1	42.2	3.8
Males (n = 19)	30.6	56.8	41.9	5.6
Total (n = 25)	29.8	57.3	41.5	4.8
Control				
Females (n = 14)	28.8	55.8	39.7	3.4
Males (n = 11)	24.5	53.5	37.3	4.5
Total (n = 25)	26.6	54.3	38.3	3.7

^a Min indicates minimum; Max, maximum; SD, standard deviation; OSA, obstructive sleep apnea.

DISCUSSION

This study aimed to evaluate the differences of the palatal and upper airway morphology between OSA patients and healthy participants and determine whether any correlation exists between the pharyngeal morphology and the palatal volume. Lowe et al.¹⁷ compared upper airway structures and craniofacial morphology, identifying the indicators of OSA and indicating the morphological differences between OSA

Table 2. Descriptive Statistics and Intergroup Differences of the Palatal Morphology, Palatal Volume, and Pharyngeal Structures^a

Variables	OSA Group (n = 25)		Control Group (n = 25)		Difference	P
	Mean	SD	Mean	SD		
Inter canine width, mm	33.01	1.36	33.68	0.78	0.67	NS
Inter molar width, mm	52.35	0.82	53.79	0.95	1.44	***
Palatal volume, mm ³	6755.63	103.85	7254.67	88.74	499.04	***
Soft palate area, mm ²	248.89	22.27	231.24	18.79	17.65	**
Nasopharyngeal area, mm ²	318.89	18.68	379.79	12.36	10.96	***
Oropharyngeal area, mm ²	601.98	12.63	667.56	11.85	25.58	***

^a OSA indicates obstructive sleep apnea; SD, standard deviation. NS: Not significant, * $p < 0.05$, ** $p < 0.01$, *** $p < 0.001$.

patients with different skeletal subtypes. Lowe et al.¹⁸ and deBerry-Borowiecki et al.¹⁹ stated that patients with OSA had a smaller maxilla and posteriorly positioned mandible.

Measuring the maxillary transverse dimensions and combining them with 3D volumetric measurements in the OSA participants resulted in skeletal adaptations of the palatal region that had smaller palatal volume and airway dimensions than the controls.

A change in the mode of breathing causes a corruption in the balance between tongue and cheek pressures. Harvold et al.²⁰ showed that the maxillary arch form is determined by tongue posture and function, especially during certain stages of dentition development. In this study, OSA patients showed a palatal morphology with a narrower maxillary and a smaller palatal volume when compared with controls, in agreement with previous research that shows that nasal deformities and maxillary growth modifications were in relation to increased nasal airway resistance.²¹

Bresolin et al.,²² Harari et al.,²³ and Berwig et al.²⁴ evaluated plaster models of nasal and mouth breathers, defining that a change in breathing pattern could lead to a change in the palatal morphology, such as a decrease in intercanine and intermolar widths, consistent with the current results.

According to Staley et al.,²⁵ the narrowing of the upper arch is for the compensatory mechanism to maintain the occlusion while the mandible is becoming retropositioned. Similar to the current findings, Seto et al.²⁶ found a maxillary dental arch constriction in OSA patients and stated that palatal height itself is not a reliable indicator of maxillary constriction and that the width must also be taken into consideration. In this study, palatal volume was significantly smaller when compared with healthy controls.

Concerning the soft tissue, studies have revealed that the soft palate is elongated and thickened in patients with OSA, and the anteroposterior pharyngeal space is reduced at the superior, middle, and inferior levels,^{27–32} in addition to the similar reductions in the oropharynx and the hypopharynx.³¹ Lowe et al.³² also stated that the size of the soft palate is a strong etiologic factor, such as

the mandible in patients with OSA. Rodenstein et al.³³ found that the soft palate area was larger in OSA patients versus controls. Mayer et al.³⁴ showed that the soft palate length and the hypopharyngeal area were significantly larger in OSA patients.

Although the pharynx is a 3D structure and the most precise method for evaluating anatomical structures is by 3D imaging systems, lateral cephalometry is commonly used in clinical practice because of its relative simplicity, accessibility, low cost, and minimal radiation, providing substantial insight to the pathology of OSA.³⁵ Patients with OSA mostly have a posteriorly displaced mandible, a narrow posterior airway space, an enlarged tongue and soft palate, and an inferiorly positioned hyoid bone.¹⁸

The majority of patients with OSA display obstruction of the respiratory tract caused by the displacement of the soft tissues during sleep and pose a greater risk for the narrowing of the upper airway.³⁶ Schwab et al.³⁷ suggested that examination of the soft tissue structures surrounding the upper airway can lead to an understanding of the airway changes and stated that the pharyngeal walls, soft palate, and tongue should be considered as important structures in determining the airway dimensions.

The anatomical abnormality of hard tissue structures is also related to the presence of OSA. As suggested by Watanabe et al.⁵ and Riley et al.,³⁸ maxillary and mandibular malformations are likely to have direct etiological roles in OSA, reducing the airway.

Abramson et al.³⁹ stated that OSA was associated with an increase in airway length and a narrowing of the dimensions. There are also other factors that could be used to identify the presence of upper airway obstruction in OSA patients, such as oropharyngeal compliance, nasopharyngeal size, and the relation between the soft palate and length and the upper airway dimensions.⁴⁰

CONCLUSION

- Small upper airway size may be the specific determinant of obstructive sleep apnea in relation

to smaller palatal volume when compared with a healthy population.

- A negative correlation between the palatal volume and soft palate area in OSA indicates that the interaction between the hard and soft tissues of the palate when breathing is restricted.

REFERENCES

1. Padma A, Ramakrisan N, Narayanan V. Management of obstructive sleep apnea: a dental perspective. *Indian J Dent Res.* 2007;18:201–209.
2. Young T, Peppard PE, Gottlieb DJ. Epidemiology of obstructive sleep apnea: a population health perspective. *Am J Respir Crit Care Med.* 2002;165:1217–1239.
3. Epstein LJ, Kristo D, Strollo PJ Jr, et al. Clinical guideline for the evaluation, management and long-term care of obstructive sleep apnea in adults. *J Clin Sleep Med.* 2009;5:263–276.
4. Younes M, Loewen AH, Ostrowski M, Laprairie J, Maturino F, Hanly PJ. Genioglossus activity available via non-arousal mechanisms vs that required for opening the airway in obstructive sleep apnea patients. *J Appl Physiol.* 2012;112:249–258.
5. Watanabe T, Isono S, Tanaka A, Tanzawa H, Nishino T. Contribution of body habitus and craniofacial characteristics to segmental closing pressures of the passive pharynx in patients with sleep-disordered breathing. *Am J Respir Crit Care Med.* 2002;165:260–265.
6. Lattimore JD, Celermajer DS, Wilcox I. Obstructive sleep apnea and cardiovascular disease. *J Am Coll Cardiol.* 2003;41:1429–1437.
7. Schwab RJ, Pasirstein M, Pierson R, Mackley A, Hachadorian R, Arens R, Maislin G, Rack AI. Identification of upper airway anatomic risk factors for obstructive sleep apnea with volumetric magnetic resonance imaging. *Am J Respir Crit Care Med.* 2003;168:522–530.
8. Johnson CD, Richardson A. Cephalometric changes in adult pharyngeal morphology. *Eur J Orthod.* 1999;21:357–362.
9. Ferguson KA, Ono T, Lowe AA, Ryan CF, Fleetham JA. The relationship between obesity and craniofacial structure in obstructive sleep apnea. *Chest.* 1995;108:375–381.
10. Sutherland K, Lee RW, Cistulli PA. Obesity and craniofacial structure as risk factors for obstructive sleep apnoea: Impact of ethnicity. *Respirology.* 2012;17:213–222.
11. Dempsey JA, Skatrud JB, Jacques AJ, Ewanowski SJ, Woodson BT, Hanson PR, Goodman B. Anatomic determinants of sleep-disordered breathing across the spectrum of clinical and non-clinical male subjects. *Chest.* 2002;122:840–851.
12. Lam B, Lam DC, Ip MS. Obstructive sleep apnoea in Asia. *Int J Tuberc Lung Dis.* 2007;11:932–933.
13. Ferguson KA, Cartwright R, Rogers R, Schmidt-Nowara W. Oral appliances for snoring and obstructive sleep apnea: a review. *Sleep.* 2006;29:244–262.
14. Guilleminault C, Hill MW, Simmons FB, Dement WC. Obstructive sleep apnea: electromyographic and fiberoptic studies. *Exp Neurol.* 1978;62:48–67.
15. Primožic J, Richmond S, Kau CH, Zhurov A, Ovsenik M. Three dimensional evaluation of early crossbite correction: a longitudinal study. *Eur J Orthod.* 2013;35:7–17.
16. Lione R, Franchi L, Huanca Ghislanzoni LT, Primožic J, Buongiorno M, Cozza P. Palatal surface and volume in mouth-breathing subjects evaluated with three-dimensional analysis of digital dental casts—a controlled study. *Eur J Orthod.* 2015;37:101–104.
17. Lowe AA, Ono T, Ferguson KA, Paek EK, Ryan CF, Fleetham JA. Cephalometric comparisons of craniofacial upper airway structure by skeletal subtype and gender in patients with obstructive sleep apnea. *Am J Orthod Dentofac Orthop.* 1996;110:653–664.
18. Lowe AA, Santamaria JD, Fleetham JA, Price C. Facial morphology and obstructive sleep apnea. *Am J Orthod Dentofac Orthop.* 1986;90:484–491.
19. deBerry-Borowiecki B, Kukwa A, Blanks RH. Cephalometric analysis for diagnosis and treatment of obstructive sleep apnea. *Laryngoscope.* 1988;98:226–234.
20. Harvold EP, Tomer BS, Vargervik K, Chierici G. Primate experiments on oral respiration. *Am J Orthod Dentofac Orthop.* 1981;79:359–372.
21. Warren DW, Duany LF, Fischer ND. Nasal pathway resistance in normal and cleft lip and palate subjects. *Cleft Palate J.* 1969;6:134–140.
22. Bresolin D, Shapiro PA, Shapiro GG, Dassel SW, Furukawa CT, Pierson WE, Chapko M, Bierman CW. Mouth breathing in allergic children: its relationship to dentofacial development. *Am J Orthod.* 1983;83:334–340.
23. Harari D, Redlich M, Miri S, Hamud T, Gross M. The effect of mouth breathing versus nasal breathing on dentofacial and craniofacial development in orthodontic patients. *Laryngoscope.* 2010;120:2089–2093.
24. Berwig LC, Silva AM, Correa EC, Moraes AB, Montenegro MM, Ritzel RA. Hard palate dimensions in nasal and mouth breathers from different etiologies. *J Societ Brasil Fono.* 2011;23:308–314.
25. Staley RN, Stuntz WR, Peterson LC. A comparison of arch widths in adults with normal occlusion and adults with class II Division 1 malocclusion. *Am J Orthod.* 1985;88:163–169.
26. Seto BH, Gotsopoulos H, Sims MR, Cistulli PA. Maxillary morphology in obstructive sleep apnoea syndrome. *Eur J Orthod.* 2001;23:703–714.
27. Jamieson A, Guilleminault C, Partinen M, Quera-Salva MA. Obstructive sleep apneic patients have craniomandibular abnormalities. *Sleep.* 1986;9:469–477.
28. Guilleminault C, Quera-Salva MA, Partinen M, Jamieson A. Women and the obstructive sleep apnea syndrome. *Chest.* 1988;93:104–109.
29. Kyberg T, Krogstad O, Djupesland G. Cephalometric analysis in patients with obstructive sleep apnoea syndrome: I. Skeletal morphology. *J Laryngol Otol.* 1989;103:287–292.
30. Zucconi M, Ferini-Stambi L, Palazzi S, Orena C, Zonta S, Smirne S. Habitual snoring with and without obstructive sleep apnoea: the importance of cephalometric variables. *Thorax.* 1992;47:157–161.
31. Pae EK, Lowe AA, Sasaki K, Price C, Tsuchiya M, Fleetham JA. A cephalometric and electromyographic study of upper airway structures in the upright and supine positions. *Am J Orthod Dentofac Orthop.* 1994;106:52–59.
32. Lowe AA, Fleetham JA, Adach S, Ryan CF. Cephalometric and computed tomographic predictors of obstructive sleep apnea severity. *Am J Orthod Dentofac Orthop.* 1995;107:589–595.

33. Rodenstein DO, Dooms G, Thomas Y, Liistro G, Stanescu DC, Culee C, Aubert-Tulkens G. Pharyngeal shape and dimensions in healthy subjects, snorers and patients with obstructive sleep apnoea. *Thorax*. 1990;45:722–727.
34. Mayer P, Pepin JL, Bettega G, Veale D, Ferretti G, Deschaux C, Levy P. Relationship between body mass index, age and upper airway measurements in snorers and sleep apnoea patients. *Eur Respir J*. 1996;9:1801–1809.
35. Fleetham JA. Upper airway imaging in relation to obstructive sleep apnea. *Clin Chest Med*. 1992;13:399–416.
36. Ryu HH, Kim CH, Cheon SM, Bae WY, Kim SH, Koo SK, Kim MS, Kim BJ. The usefulness of cephalometric measurement as a diagnostic tool for obstructive sleep apnea syndrome: a retrospective study. *Oral Surg Oral Med Oral Pathol Oral Radiol*. 2015;119:20–31.
37. Schwab RJ, Gupta KB, Gefter WB, Metzger LJ, Hoffman EA, Pack AI. Upper airway and soft tissue anatomy in normal subjects and patients with sleep-disordered breathing. Significance of the lateral pharyngeal walls. *Am J Respir Crit Care Med*. 1995;152:1673–1689.
38. Riley R, Guilleminault C, Herran J, Powell N. Cephalometric analyses and flow-volume loops in obstructive sleep apnea patients. *Sleep*. 1983;4:303–311.
39. Abramson Z, Susarla S, August M, Maria T, Kaban L. Three-dimensional computed tomographic analysis of airway anatomy in patients with obstructive sleep apnea. *J Oral Maxillofac Surg*. 2010;68:354–362.
40. Shigeta Y, Ogawa T, Tomoko I, Clark GT, Enciso R. Soft palate length and upper airway relationship in OSA and non-OSA subjects. *Sleep Breath*. 2010;14:353–358.