

Long-term stability of miniscrew anchored maxillary molar distalization in Class II treatment

Till Edward Bechtold^a; Young-Chel Park^b; Kyung-Ho Kim^c; Heekyu Jung^d; Ju-Young Kang^d; Yoon Jeong Choi^e

ABSTRACT

Objective: To investigate treatment stability of miniscrew-anchored maxillary distalization in Class II malocclusion.

Materials and Methods: This retrospective study included a distalization (n = 19) and a control (n = 19) group; a patient group with minor corrections served the control. Lateral cephalograms of 38 adult patients were taken before (T0), immediately after (T1), and 3–4 years after (T2) treatment. Horizontal and vertical movement and tipping of the maxillary first molars (U6) and central incisors (U1) were measured along with skeletal craniofacial parameters at three time points to compare the two groups regarding the achieved treatment effects and their stability.

Results: Total arch distalization therapy led to 4.2 mm of distal movement of U6 without distal crown tipping (0.6° of axis change) and 3.3° of occlusal plane steepening. Over an average retention period of 42 months, maxillary total arch distalization provided high stability of treatment results, showing the same amount of mesial movement (0.7 mm) as the control group.

Conclusions: In Class II treatment, miniscrew-anchored maxillary total arch distalization can provide stable distal movement of the maxillary first molars and central incisors. (*Angle Orthod.* 2020;90:362–368.)

KEY WORDS: Molar distalization; Class II malocclusion; Miniscrew anchorage; Total arch distalization; Stability; Relapse

INTRODUCTION

The stability of resolutions for dental crowding depends on the amount of space in the dental arch and the amount of space available through transverse and sagittal correction. Distalization can be indicated to regain space in a dental arch or to gain additional space when the transverse dimension and incisor inclination do not allow any further stable increase of space.^{1–3} Molar distalization is the objective of a sizable number of appliances relying either on dentoalveolar^{4–9} or extraoral¹⁰/labial¹¹ anchorage. Any dentoalveolar anchorage inevitably bears a somewhat self-defeating countermovement of the anchoring segment,¹² and devices like a headgear or lip-bumper largely depend on patient compliance. Hence, all these options put moderate amounts of distalization as a treatment goal in jeopardy and make large amounts of distalization improbable to achieve.

The amount and quality of distalization possible was enhanced tremendously by introduction of skeletal anchorage (noncompliance) methods¹³ to entirely eliminate unwanted countermovement during distalization.^{14,15} The introduction of miniscrew implants made

^a Attending Orthodontist, Department of Orthodontics, Dentofacial Orthopedics and Pedodontics, Center for Dental and Craniofacial Sciences, Charité-Universitätsmedizin Berlin, Berlin, Germany.

^b Professor Emeritus, Department of Orthodontics, The Institute of Craniofacial Deformity, Yonsei University College of Dentistry, Seoul, Korea.

^c Professor, Department of Orthodontics, Gangnam Severance Dental Hospital, The Institute of Craniofacial Deformity, Yonsei University College of Dentistry, Seoul, Korea.

^d Postgraduate student, Department of Orthodontics, The Institute of Craniofacial Deformity, Yonsei University College of Dentistry, Seoul, Korea.

^e Associate Professor, Department of Orthodontics, The Institute of Craniofacial Deformity, Yonsei University College of Dentistry, Seoul, Korea.

Corresponding author: Dr Yoon Jeong Choi, Department of Orthodontics, College of Dentistry, Yonsei University, 50-1 Yonsei-ro, Seodaemun-gu, Seoul 03722, Korea (e-mail: yoonjchoi@yuhs.ac)

Accepted: November 2019. Submitted: May 2019.

Published Online: January 20, 2020

© 2020 by The EH Angle Education and Research Foundation, Inc.

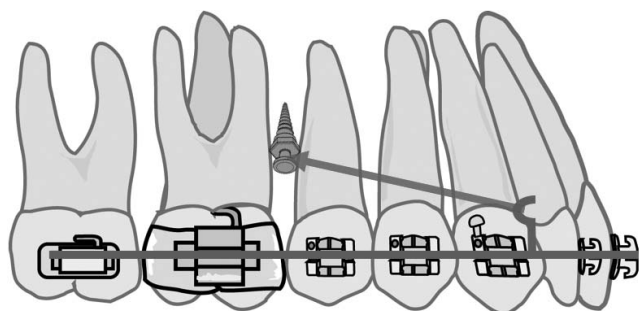


Figure 1. Illustration of intraoral mechanics used for the total arch distalization group.

skeletal anchorage more easily accessible for the orthodontist.¹⁶ Miniscrew implants can be loaded directly^{15,17} or through scaffolding^{18,19} and have been shown to enable distal movement of the molars and premolars at the same time,^{20,21} causing minimal distal tipping of the molars^{21,22} which suggests high stability. However, throughout a lifetime, permanent molars exhibit mesial migration,²³ attributed to the anterior component of force, which is explained to result from mesial inclination of teeth.^{24–26} Although mesial migration is regarded as a physiologic phenomenon, this context could mean reduced stability of molar distalization results.

Class II malocclusion combined with a lack of adequate space in the maxillary dental arch can be solved using miniscrew-anchored maxillary molar distalization.^{27,28} In this study, the hypothesis was that maxillary molar distalization, specifically total arch distalization, can achieve stable treatment results compared with minimally treated subjects in terms of anterior and posterior dental changes.

MATERIALS AND METHODS

This study was performed after approval of the institutional review board of Yonsei University Dental Hospital (IRB No. 2-2016-0017), which waived the requirement for written informed consent because of the retrospective nature of this study.

Subjects

This retrospective, cross-sectional cohort study was conducted on consecutive patients who had visited the Department of Orthodontics at Yonsei University Dental Hospital from January 2015 to February 2019 for retention follow-up. Subjects were selected who had lateral cephalograms before (T0), immediately after (T1), and at least 2 years after (T2) treatment. Subjects were included who had Class II malocclusion at T0 and whose amount of distalization of U6 was over 2 mm.

The experimental group had undergone maxillary total arch distalization using elastomeric chains between long crimpable hooks mesial to the maxillary canines and interradicular miniscrews positioned between the maxillary second premolar and first molar (U6) on each side (Figure 1, distalization group). Before and after distalization, the amount of distal alveolar bone was confirmed on a panoramic radiograph and lateral cephalogram. In cases of a large amount of total arch distalization, repositioning of the interradicular miniscrews was necessary toward the end of treatment since miniscrew tips were angled apically and the sagittal span of interradicular bone exceeded the space measured at the mid-root level.

The control group had minor tooth movement, less than 1 mm anteroposterior movement of the maxillary central incisor (U1) and U6 during treatment. All control group patients had Class I or Class II malocclusion at T0. Exclusion criteria for both groups were: restorative treatment of U1 or U6 at any time during the observation period, dentofacial deformity, history of orthognathic surgery, and age <18 years at T0.

Based on the inclusion/exclusion criteria, 19 subjects (mean age at T0, =24.9 years; 4 men and 15 women) for the distalization group and 19 subjects (mean age at T0, =25.4 y; 8 men and 11 women) for the control group were included (Table 1). Regarding retention, fixed lingual retainers from canine to canine were bonded in all subjects at T1. All patients wore removable circumferential retainers at night.

Measurements

Changes in position and axis of U6 and U1 and skeletal cephalometric parameters were measured (Figure 2). The pterygoid vertical (PTV) plane was used as a reference plane for horizontal linear measurements of tooth movement.²⁷ PTV, which is known to be a stable reference plane in the sagittal direction,²⁹ is constructed by connecting Sella ethmoidale, which is an intersection point of the anterior cranial base and the greater wing of the sphenoid bone, and the inferior point of the pterygomaxillary fissure on lateral cephalograms.³⁰ The reference plane for vertical linear measurements of tooth movement was palatal plane (PP), which connects the anterior and posterior nasal spine. The mesiobuccal cusp for U6 and incisal edge for U1 were used as landmarks, and their perpendicular distances to PTV and PP were measured for horizontal and vertical changes, respectively. In cases of double contours, the middle between the two landmarks was used for measurement.

To measure changes in axis, the long axis of U6 was defined as a line through the centroid point and furcation point and the long axis of U1 as a line

Table 1. Comparison of Pretreatment Age, Treatment Duration, and Duration of Retention Between Distalization and Control Groups^a

	Distalization (n = 19)	Control (n = 19)	P Value
Age at T0 (y)	24.9 ± 5.0	25.4 ± 4.9	.793
Duration of treatment (T0-T1, mo)	30.6 ± 12.2	16.2 ± 3.0	.010*
Duration of retention (T1-T2, mo)	36.9 ± 23.3	47.4 ± 11.1	.099

^a Data are present mean ± standard deviation. Independent t-tests were performed to compare two groups. T0 indicates before treatment; T1, after treatment; T2, retention.

* $P < .05$.

through the incisal edge and root apex. The dorsocaudal angle between the Sella (S) – Nasion (N) line and the respective long axis was measured as the angle of the long axis. Other cephalometric values such as SNA, SNB, ANB, posterior/anterior facial height ratio (PFH/AFH), occlusal plane angle (SN-OP), mandibular plane angle (SN-MP), overjet, and overbite were also measured.

Statistical Analysis

The minimum number of subjects was calculated using G*Power 3 (Düsseldorf, Germany) with a significance level of $P < .05$ and a power of 95% based on an article that reported 2.0 mm of mesial movement after distalization by the Pendulum appliance.³¹ Power analysis confirmed that 6 subjects per group were sufficient to detect a 2-mm difference of U6 movement after distalization.

One examiner performed all measurements. To test intraexaminer reliability, the measurements were repeated after a 1-month interval for eight subjects per group, which showed high reliability (range of the intraclass correlation coefficient, 0.947–0.991).

After confirmation of normal distribution of the data by Shapiro-Wilk test, an independent *t*-test was conducted using SPSS software, version 23.0 (IBM Corp, Armonk, NY, USA). A *P* value less than .05 was considered statistically significant.

RESULTS

Results are shown in Tables 1 through 4. Mean treatment duration was 30.6 months (standard deviation [SD] = 12.2) for the distalization group and 16.2 months (SD = 3.0) for the control group; mean duration of retention was 36.9 months (SD = 23.3) for the distalization group and 47.4 months (SD = 11.1) for the control group (Table 1).

Before treatment, some measurements showed significant differences between the groups (Table 2). Between the distalization and control group, for example, there was a significant difference in SNB angle ($P < .001$) and ANB angle ($P < .01$). PFH/AFH and SN-MP angle differed significantly between the distalization and control groups ($P < .01$), showing a more horizontal facial type in the control group compared with a neutral facial type in the distalization group. U6 angulation and U1 inclination did not differ significantly between the groups ($P > .05$).

During treatment (Table 3; Figure 3), in the distalization group compared with the control group, the U6

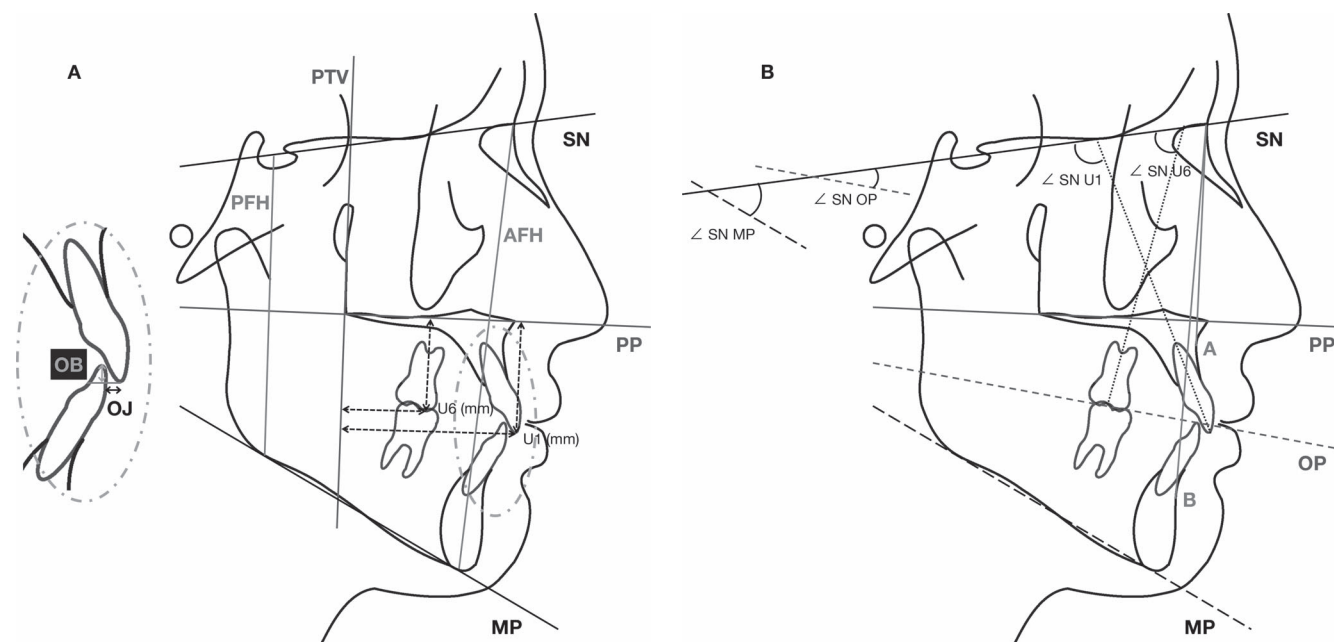
**Figure 2.** Cephalometric (A) linear and (B) angular measurements.

Table 2. Comparison of Skeletal and Dental Measurements Before Treatment Between Distalization and Control Groups^a

	Distalization (n = 19)	Control (n = 19)	P Value
Sagittal values			
SNA (°)	80.5 ± 4.6 (72.4, 88.4)	82.1 ± 2.4 (76.1, 84.6)	.196
SNB (°)	75.1 ± 3.6 (69.0, 80.7)	79.7 ± 3.6 (74.4, 81.8)	.000***
ANB (°)	5.3 ± 2.3 (3.1, 9.0)	2.4 ± 2.7 (-3.0, 5.5)	.001**
Overjet (mm)	4.9 ± 2.2 (1.8, 9.9)	3.9 ± 2.0 (1.0, 5.3)	.175
Overbite (mm)	2.2 ± 1.8 (-0.4, 6.8)	2.4 ± 1.6 (-2.0, 5.3)	.760
Vertical values			
PFH/AFH (%)	62.8 ± 6.5 (54.1, 74.6)	68.1 ± 5.1 (58.7, 78.6)	.008**
SN-OP (°)	20.7 ± 4.8 (13.0, 29.0)	18.7 ± 5.3 (12.2, 27.7)	.238
SN-MP (°)	39.1 ± 7.9 (23.2, 50.3)	31.5 ± 6.4 (19.8, 43.9)	.003**
Dental values			
U1 to SN (°)	105.2 ± 5.0 (97.8, 113.8)	106.5 ± 8.7 (91.1, 118.6)	.552
U6 to SN (°)	60.3 ± 7.2 (50.2, 69.8)	62.7 ± 7.6 (51.7, 74.1)	.338

^a Data are present mean ± standard deviation (minimum, maximum).

Independent *t*-tests were performed to compare two groups. AFH indicates anterior facial height; ANB, A point-nasion-B point; MP, mandibular plane; OP, occlusal plane; PFH, posterior facial height; SN, sella-nasion plane; SNA sella-nasion-A point; SNB, sella-nasion-B point; U1, maxillary central incisor; U6, first molar.

** *P* < .01; *** *P* < .001.

crowns moved significantly distally by 4.2 mm (*P* < .001) without any significant vertical movement or tipping (*P* > .05). As a result of the distalization mechanics, compared with the control group, the U1 crowns moved significantly in a posterior direction by 3.4 mm (*P* < .01) without significant movement in a vertical direction. However, there was significant palatal tipping (*P* < .05) which resulted in a significant decrease of overjet by 2.0 mm (*P* < .01). The nonsignificant intrusion of U6 crowns (*P* > .05) and extrusion of the U1 crowns (*P* > .05) in the distalization group, compared with the control group, steepened the occlusal plane significantly by 3.3° (*P* < .01).

During retention (Table 4), there were no significant differences between the two groups regarding horizon-

tal dental or skeletal parameters. Vertical changes were observed only in U6 movement and skeletal parameters: in the distalization group, compared with the control group, U6 extruded significantly, while in the control group compared with the distalization group, PFH/AFH (*P* < .05) and SN-MP (*P* < .05) changed to a more horizontal facial pattern.

DISCUSSION

In a sample of 38 adult patients, the present study revealed stable anterior and posterior distalization caused by maxillary total arch distalization compared with the control group over an average retention period of 42 months (SD = 19): (1) maxillary total arch

Table 3. Comparison of Skeletal and Dental Changes During Treatment (T1-T0) of Distalization and Control Groups^a

	Distalization (n = 19)	Control (n = 19)	P Value
Molar movement and vertical skeletal impact			
U6 Cr Hor (mm)	-4.2 ± 2.0 (-7.2, -2.1)	0.4 ± 0.5 (-0.3, 0.9)	.000***
U6 Cr Ver (mm)	-0.8 ± 2.6 (-4.8, 3.4)	0.4 ± 1.1 (-1.1, 1.1)	.087
U6 axis (°)	0.6 ± 3.8 (-4.6, 7.7)	0.1 ± 3.3 (-4.7, 5.9)	.689
PFH/AFH (%)	0.6 ± 2.6 (-3.2, 5.8)	-0.1 ± 1.9 (-2.7, 4.7)	.348
SN-OP (°)	3.3 ± 4.3 (-5.9, 8.7)	-0.6 ± 2.2 (-3.7, 2.2)	.001**
SN-MP (°)	-0.5 ± 4.3 (-5.9, 4.8)	0.4 ± 1.6 (-2.0, 2.8)	.442
Incisor movement and horizontal skeletal impact			
U1 Cr Hor (mm)	-3.4 ± 3.5 (-11.1, 0.5)	-0.1 ± 1.3 (-2.6, 2.5)	.001**
U1 Cr Ver (mm)	0.1 ± 1.7 (-6.0, 1.8)	-0.1 ± 1.4 (-2.1, 2.0)	.623
U1 to SN (°)	-3.9 ± 5.1 (-13.3, 1.2)	-0.7 ± 4.4 (-5.0, 5.4)	.045*
Overjet (mm)	-2.0 ± 2.0 (-8.1, 0.2)	-0.2 ± 1.5 (-2.6, 1.7)	.003**
Overbite (mm)	-0.2 ± 1.4 (-2.7, 1.5)	-0.1 ± 1.2 (-2.6, 3.0)	.929
SNA (°)	-0.6 ± 2.4 (-2.2, 2.7)	0.0 ± 1.2 (-1.9, 2.1)	.338
SNB (°)	0.1 ± 2.4 (-1.5, 3.4)	-0.1 ± 1.2 (-2.5, 2.8)	.779
ANB (°)	-0.6 ± 1.2 (-3.2, 0.8)	0.1 ± 1.0 (-1.8, 1.8)	.056

^a Data are present mean ± standard deviation (minimum, maximum).

Independent *t*-tests were performed to compare two groups. AFH indicates anterior facial height; ANB, A point-nasion-B point; Cr, crown; Hor, horizontal distance; MP, mandibular plane; OP, occlusal plane; PFH, posterior facial height; SN, sella-nasion plane; SNA sella-nasion-A point; SNB, sella-nasion-B point; U1, maxillary central incisor; U6, first molar; Ver, vertical distance.

* *P* < .05; ** *P* < .01; *** *P* < .001.

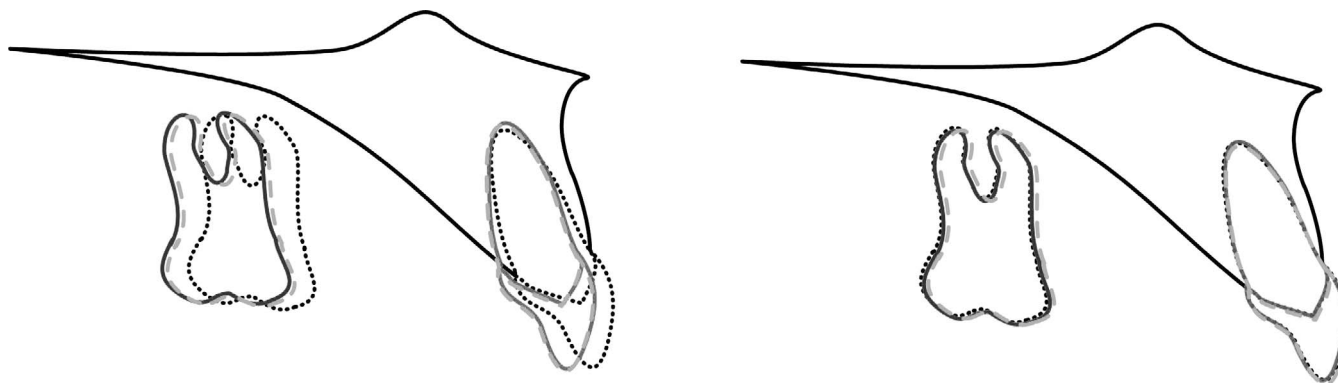


Figure 3. Schematic drawing of the changes in the distalization (left) and control (right) groups during and after distalization. Dotted, solid, and dashed lines indicate before, immediately after, and approximately 3–4 years after treatment, respectively.

distalization resulted in distal movement and intrusion of the maxillary first molars (without tipping), retraction and palatal tipping of the incisors (without significant vertical movement), and steepening of the occlusal plane; and (2) there was significant relapse of the achieved maxillary first molar intrusion. Although counterclockwise rotation of the mandible (increase of PFH/AFH and decrease of SN-MP) was found in the control group, compared with the distalization group during retention, the average range of 1.0 % PFH/AFH and 0.9° SN-MP can be considered clinically insignificant.

The two treatment groups of adult patients differed significantly regarding duration of treatment ($P < .05$). Logically, because of the need for greater orthodontic correction, the total arch distalization group underwent a longer treatment time than the control group with minor tooth movements. As for the duration of retention

investigated, the distalization group had an average of over 3 years of retention, which was similar to findings of recently published studies on retention, some even in growing patients.^{32–34} The control group with minor tooth movement had a slightly longer retention period of nearly 4 years.

Significant differences were noted between the distalization and control group at T0 in SNB and ANB angles as well as the vertical values PFH/AFH and SN-MP. The significant Class II relationship reflected by the SNB and ANB angle in the distalization group compared with a Class I relation in the control group, clearly indicated the treatment need for maxillary distalization in order to correct the Class II occlusion. PFH/AFH and SN-MP values revealed a neutral facial pattern in the distalization group, while patients in the control group showed a growth pattern that was significantly more horizontal. Posttreatment changes

Table 4. Comparison of Skeletal and Dental Changes During Retention (T2-T1) of Distalization and Control Groups^a

	Distalization (n = 19)	Control (n = 19)	P Value
Molar movement and vertical skeletal impact			
U6 Cr Hor (mm)	0.7 ± 0.6 (0.0, 1.6)	0.7 ± 0.4 (0.1, 1.6)	.730
U6 Cr Ver (mm)	0.9 ± 0.7 (–0.7, 1.9)	0.2 ± 0.9 (–1.6, 1.9)	.018*
U6 to SN (°)	0.6 ± 1.4 (–1.5, 4.0)	0.5 ± 2.2 (–3.2, 4.9)	.954
PFH/AFH (%)	–0.4 ± 0.7 (–1.7, 1.0)	0.6 ± 1.5 (–2.7, 3.1)	.012*
SN-OP (°)	–0.3 ± 2.1 (–3.7, 2.8)	–0.1 ± 2.1 (–5.0, 3.4)	.721
SN-MP (°)	0.5 ± 0.8 (–1.1, 1.2)	–0.4 ± 1.7 (–3.0, 2.9)	.049*
Incisor movement and horizontal skeletal impact			
U1 Cr Hor (mm)	0.2 ± 0.6 (–0.9, 1.1)	0.3 ± 0.5 (–0.5, 1.5)	.546
U1 Cr Ver (mm)	0.4 ± 1.2 (–2.0, 2.2)	0.3 ± 1.2 (–1.8, 2.3)	.825
U1 to SN (°)	0.1 ± 1.7 (–4.8, 5.7)	–0.5 ± 3.8 (–5.7, 6.8)	.516
Overjet (mm)	–0.2 ± 0.7 (–1.1, 0.6)	0.1 ± 0.8 (–1.0, 1.4)	.158
Overbite (mm)	0.1 ± 0.6 (–1.0, 1.1)	0.0 ± 0.6 (–1.0, 1.6)	.585
SNA (°)	–0.1 ± 0.6 (–1.0, 0.9)	–0.3 ± 1.0 (–2.0, 1.5)	.476
SNB (°)	0.0 ± 0.8 (–1.1, 1.1)	–0.0 ± 0.9 (–1.2, 1.5)	.821
ANB (°)	–0.1 ± 0.5 (–1.0, 1.0)	–0.2 ± 1.3 (–2.9, 1.6)	.663

^a Data are present mean ± standard deviation (minimum, maximum). Independent *t*-tests were performed to compare two groups. AFH indicates anterior facial height; ANB, A point-nasion-B point; Cr, crown; Hor, horizontal distance; MP, mandibular plane; OP, occlusal plane; PFH, posterior facial height; SN, sella-nasion plane; SNA sella-nasion-A point; SNB, sella-nasion-B point; U1, maxillary central incisor; U6, first molar; Ver, vertical distance.

* $P < .05$.

in both groups indicated minor, yet significant, differences in skeletal vertical changes which, on the one hand, could be attributed to “the normal maturational process”³⁵ of the respective growth pattern. On the other hand, these changes (1% average difference in PFH/AFH and 0.9° average difference in SN-MP) were minor enough to be considered clinically irrelevant.

In the distalization group, significant horizontal distal movement of the U6 crowns was achieved. This was also shown by others using different appliances^{8,36} and mechanics.^{15,20} Distalizing tooth movement at the crown level alone includes distal tipping, which has been described as a major cause of substantial relapse.^{37,38} Various skeletal anchorage mechanics have been shown to minimize distal tipping through distalization^{14,17} and to even entirely control root movement.^{39,40} The data also showed translational distal movement of U6, even with mesial tipping of 0.6° (SD = 2.6°) despite distal movement, in the distalization group. These changes in the U6 axis in the distalization group were insignificant compared with the control group; this movement pattern led to reliable sagittal stability of U6 throughout the posttreatment retention period.

Looking at the amount of palatal movement of the U1, significant palatal tipping was observed along with significant crown movement, but this remained stable during the retention period and therefore remained clinically acceptable. However, Lossdorfer et al.⁴¹ showed that occlusal plane rotation was distinctly influenced by incisor inclination. In the current study's distalization group, the insignificant intrusion of the maxillary molars ($P > .05$) in combination with significant palatal tipping of the maxillary incisors ($P < .05$) resulted in an even more significant steepening of the occlusal plane (SN-OP, $P < .01$), as has been shown before.¹⁷ The significant alterations of horizontal incisor positions helped to significantly correct overjet in the distalization group.

After treatment, the U6 on average extruded an amount to which it had been intruded during treatment. This could partially be ascribed to vertical relapse of the previous intrusion by total arch distalization mechanics. Occlusal adjustment and minor facial changes, which have been described to take place in humans in their third decade of life,⁴² were probably responsible for part of these measurements as well.

Over the posttreatment time investigated, the stability of the sagittal, vertical, and axial treatment results achieved was impeccable in miniscrew anchored total arch distalization. Therefore, it can be stated that, within the scope of this study, in Class II treatment, maxillary molar distalization by total arch distalization resulted in treatment of the anterior and posterior

dentition, as stable as treatment with minimal mesio-distal tooth movement.

CONCLUSIONS

- Total arch distalization against miniscrews between the first molar and second premolar can achieve translational molar distalization, resulting in minor steepening of the occlusal plane.
- Total arch distalization can achieve stable results lasting years after retention.
- Long-term skeletal changes may not be expected as a result of total arch distalization.

REFERENCES

1. Strang RHW. The fallacy of denture expansion as a treatment procedure. *Angle Orthod.* 1949;19:12–17.
2. Stöckli PW. Functional appliances and the extraction/nonextraction decision. In: Bolender CJ, Bounoure GM, Barat Y, eds. *Extraction versus Nonextraction*. Paris: SID Publisher; 1995:20–26.
3. Bechtold TE, Göz GR. Einfluss standardisierter Bogenformen auf die transversale Zahnbogendimension [The influence of straight-wire appliances and prefabricated archwires on the transversal arch dimension]. *Kieferorthopädie*. 2010; 24:27–35.
4. Jones RD, White JM. Rapid Class II molar correction with an opencoil jig. *J Clin Orthod.* 1992;26:661–664.
5. Hilgers JJ. The pendulum appliance for Class II non-compliance therapy. *J Clin Orthod.* 1992;26:706–714.
6. Bondemark L, Kuroi J. Distalization of maxillary first and second molars simultaneously with repelling magnets. *Eur J Orthod.* 1992;14:264–272.
7. Carano A, Testa M. The distal jet for upper molar distalization. *J Clin Orthod.* 1996;30:374–380.
8. Fortini A, Lupoli M, Parri M. The first class appliance for rapid molar distalization. *J Clin Orthod.* 1999;33:322–328.
9. Keles A, Erverdi N, Sezen S. Bodily distalization of molars with absolute anchorage. *Angle Orthod.* 2003;73:471–482.
10. Haas AJ. Headgear therapy: the most efficient way to distalize molars. *Semin Orthod.* 2000;6:79–90.
11. Solomon MJ, English JD, Bonham Magness W, McKeed CJ. Long-term stability of lip bumper therapy followed by fixed appliances. *Angle Orthod.* 2006;76:36–42.
12. Ghosh J, Nanda RS. Evaluation of an intraoral maxillary molar distalization technique. *Am J Orthod Dentofacial Orthop.* 1996;110:639–646.
13. Creekmore TD, Eklund MK. The possibility of skeletal anchorage. *J Clin Orthod.* 1983;17:266–269.
14. Sugawara J, Kanzaki R, Takahashi I, Nagasaka H, Nanda R. Distal movement of maxillary molars in nongrowing patients with the skeletal anchorage system. *Am J Orthod Dentofacial Orthop.* 2006;129:723–733.
15. Choi YJ, Lee JS, Cha JY, Park YC. Total distalization of the maxillary arch in a patient with skeletal Class II malocclusion. *Am J Orthod Dentofacial Orthop.* 2011;139:823–833.
16. Kanomi R. Mini-implant for orthodontic anchorage. *J Clin Orthod.* 1997;31:763–767.
17. Bechtold TE, Kim JW, Choi TH, Park YC, Lee KJ. Distalization pattern of the maxillary arch depending on the

- number of orthodontic miniscrews. *Angle Orthod.* 2013;83:266–273.
18. Kinzinger GS, Eren M, Diedrich PR. Treatment effects of intraoral appliances with conventional anchorage designs for non-compliance maxillary molar distalization: a literature review. *Eur J Orthod.* 2008;30:558–571.
 19. Mah SJ, Kim JE, Ahn EJ, Nam JH, Kim JY, Kang YG. Analysis of midpalatal miniscrew-assisted maxillary molar distalization patterns with simultaneous use of fixed appliances: a preliminary study. *Korean J Orthod.* 2016;46:55–61.
 20. Kuroda S, Hichijo N, Sato M, et al. Long-term stability of maxillary group distalization with interradicular miniscrews in a patient with a Class II Division 2 malocclusion. *Am J Orthod Dentofacial Orthop.* 2016;149:912–922.
 21. Lee SK, Abbas NH, Bayome M, et al. A comparison of treatment effects of total arch distalization using modified C-palatal plate vs buccal miniscrews. *Angle Orthod.* 2018;88:45–51.
 22. Mohamed RN, Basha S, Al-Thomali Y. Maxillary molar distalization with miniscrew-supported appliances in Class II malocclusion: a systematic review. *Angle Orthod.* 2018;88:494–502.
 23. Proffit WR, Fields HW, Sarver DM. *Contemporary Orthodontics*. 5th ed. St Louis, Mo: Elsevier; 2012.
 24. Southard TE, Behrents RG, Tolley EA. The anterior component of occlusal force. Part 2. Relationship with dental malalignment. *Am J Orthod Dentofacial Orthop.* 1990;97:41–44.
 25. Acar A, Alcan T, Erverdi N. Evaluation of the relationship between the anterior component of occlusal force and postretention crowding. *Am J Orthod Dentofacial Orthop.* 2002;122:366–370.
 26. Al Qassar SS, Mavragani M, Psarras V, Halazonetis DJ. The anterior component of occlusal force revisited: direct measurement and theoretical considerations. *Eur J Orthod.* 2016;38:190–196.
 27. Fontana M, Cozzani M, Mutinelli S, Spina R, Caprioglio A. Maxillary molar distalization therapy in adult patients: a multicentre study. *Orthod Craniofac Res.* 2015;18:221–231.
 28. Yamada K, Kuroda S, Deguchi T, Takano-Yamamoto T, Yamashiro T. Distal movement of maxillary molars using miniscrew anchorage in the buccal interradicular region. *Angle Orthod.* 2009;79:78–84.
 29. Brodie AG. On the growth pattern of the human head. From the third month to the eighth year of life. *Am J Anat.* 1941;68:209–262.
 30. Enlow DH, Kuroda T, Lewis AB. The morphological and morphogenetic basis for craniofacial form and pattern. *Angle Orthod.* 1971;41:161–188.
 31. Caprioglio A, Fontana M, Longoni E, Cozzani M. Long-term evaluation of the molar movements following pendulum and fixed appliances. *Angle Orthod.* 2013;83:447–454.
 32. Yoon W, Hwang S, Chung C, Kim KH. Changes in occlusal function after extraction of premolars: 2-year follow-up. *Angle Orthod.* 2017;87:703–708.
 33. Myrland R, Keski-Nisula K, Kerosuo H. Stability of orthodontic treatment outcomes after 1-year treatment with the eruption guidance appliance in the early mixed dentition: A follow-up study. *Angle Orthod.* 2019;89:206–213.
 34. Rice AJ, Carrillo R, Campbell PM, Taylor RW, Buschang PH. Do orthopedic corrections of growing retrognathic hyperdivergent patients produce stable results? *Angle Orthod.* 2019;89:552–558.
 35. Bishara SE, Treder JE, Jakobsen JR. Facial and dental changes in adulthood. *Am J Orthod Dentofac Orthop.* 1994;106:175–186.
 36. Chiu PP, McNamara JA Jr., Franchi L. A comparison of two intraoral molar distalization appliances: distal jet versus pendulum. *Am J Orthod Dentofacial Orthop.* 2005;128:353–365.
 37. Chung K-R, Kim S-H, Choo HR, Kook Y-A, Cope JB. Distalization of the mandibular dentition with mini-implants to correct a Class III malocclusion with a midline deviation. 2010;137:135–146.
 38. Tai K, Park JH, Tatamiya M, Kojima Y. Distal movement of the mandibular dentition with temporary skeletal anchorage devices to correct a Class III malocclusion. *Am J Orthod Dentofacial Orthop.* 2013;144:715–725.
 39. Lee KJ, Park YC, Hwang WS, Seong EH. Uprighting mandibular second molars with direct miniscrew anchorage. *J Clin Orthod.* 2007;41:627–635.
 40. Lee KJ, Joo E, Yu HS, Park YC. Restoration of an alveolar bone defect caused by an ankylosed mandibular molar by root movement of the adjacent tooth with miniscrew implants. *Am J Orthod Dentofacial Orthop.* 2009;136:440–449.
 41. Lossdorfer S, Schwestka-Polly R, Wiechmann D. Control of lower incisor inclination with a completely customized lingual appliance for dentoalveolar compensation of Class III malocclusion. *J Orofac Orthop.* 2013;74:381–396.
 42. Bondevik O. Dentofacial changes in adults: a longitudinal cephalometric study in 22–33 and 33–43 year olds. *J Orofac Orthop.* 2012;73:277–288.