

Cervicovertebral anomalies and/or normal variants in patients with congenitally bilateral absent maxillary lateral incisors: *A comparative lateral cephalometric study*

Taner Ozturk^a; Aykan Onur Atilla^b; Ahmet Yagci^c

ABSTRACT

Objective: To determine whether there is a relationship between congenitally bilaterally absent maxillary lateral incisors (BAMLI) and skeletal anomalies and/or normal variants.

Materials and Methods: The records of 86 patients (62 girls, 24 boys; age 12–17 years) with congenitally BAMLI and 86 patients (55 girls, 34 boys; age 13–18 years) without any dental or skeletal anomalies were collected and evaluated retrospectively. The study was based on the evaluation of lateral cephalometric and orthopantomographic radiographs. Posterior arch deficiency of the atlas bone (PADA); atlanto-occipital ligament calcification, known as “ponticulus posticus” (PP); and interclinoid ligament calcification, known as “sella turcica bridging” were recorded for each participant. Pearson χ^2 and Fisher exact tests were used to evaluate and compare skeletal anomalies and/or normal variants between patients with BAMLI and the control group.

Results: The prevalence of cervicovertebral anomalies and/or normal variants seen in the lateral cephalometric radiographs was higher in patients with BAMLI than in the control group. The prevalence of PP was lower and that of PADA was higher in patients with BAMLI than in the control group ($P < .05$).

Conclusion: The prevalence of PADA was increased and that of PP formation was decreased in patients with BAMLI. There was a significant relationship between skeletal anomalies and/or normal variants. (*Angle Orthod.* 2020;90:383–389.)

KEY WORDS: Absent maxillary lateral incisor; Cervicovertebral anomalies; Normal variants; Cephalometric radiography

INTRODUCTION

In orthodontics, lateral cephalometric radiographs are frequently used to investigate the growth, development, and morphometric relationships of craniofacial, maxillomandibular, and dental structures. They also provide diagnostic data about the cranium, face, cervical vertebrae, and dental structure. Information

about rare variants of cervicovertebral structures can also be obtained using these data.^{1–7} However, many developmental anomalies or normal variants may be associated with a significant problem in other systemic diseases.^{5–10} Some of these radiologic findings can be detected early during examinations performed at specific time points and may appear before other signs and symptoms in some syndromes.^{4,7,11–13}

Recently, a higher incidence of ponticulus posticus (PP) in the atlas, sella turcica bridge (STB) calcification, and specific craniofacial morphology has been associated with dental agenesis.^{14,15} Observation of craniofacial skeletal anomalies is often accompanied with congenitally absent maxillary lateral incisors. This association may be based on the development of neural crest cells (NCCs) and/or homeobox genes in the development of the craniofacial region.^{16,17} Tooth development and eruption, calcification of the STB, as well as neck and shoulder skeletal developments, have been shown to be influenced by NCCs.¹⁸

^a Orthodontist, private practice, Kayseri, Turkey.

^b Orthodontist, Osmanli Dental Center, Republic of Turkey Ministry of Health, Ankara, Turkey.

^c Associate Professor, Erciyes University, Faculty of Dentistry, Department of Orthodontics, Kayseri, Turkey.

Corresponding author: Taner Ozturk, DDS, MS, Orthodontist, Kosk Mahallesi Denizli Sokak No 19 38040, Melikgazi, Kayseri, Turkey
(e-mail: tanertr35@gmail.com)

Accepted: December 2019. Submitted: June 2019.

Published Online: February 3, 2020

© 2020 by The EH Angle Education and Research Foundation, Inc.

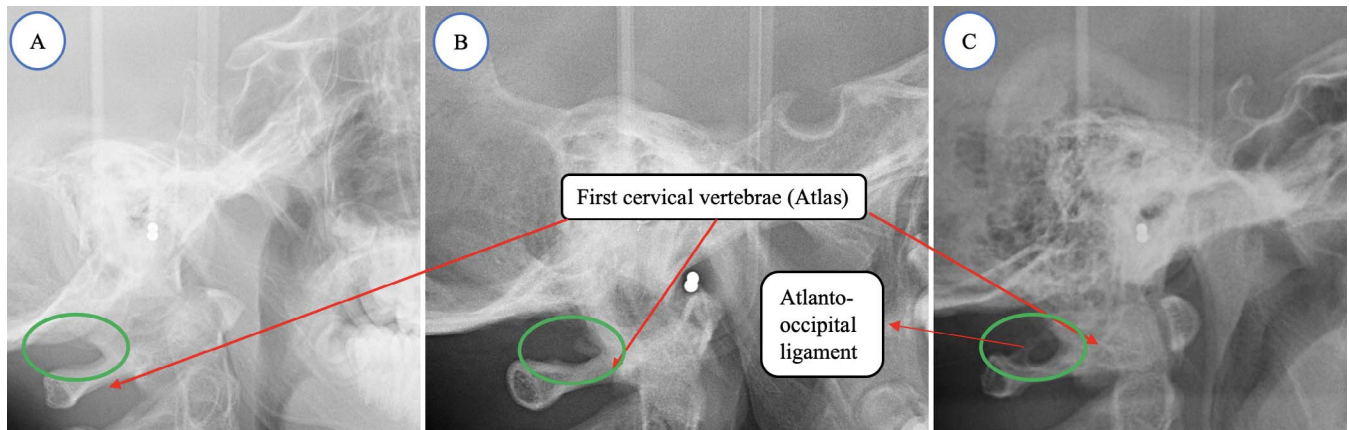


Figure 1. Analysis was performed on cephalometric films. The first cervical vertebra (atlas) area was evaluated. (A) The atlanto-occipital ligament is not calcified (no presence of ponticus posticus). (B) The atlanto-occipital ligament is partially calcified (ponticus posticus is partially present). (C) The atlanto-occipital ligament is fully calcified (ponticus posticus is completely present).

This study aimed to (1) identify the relationship between congenitally bilaterally absent maxillary lateral incisors (BAMLI) and skeletal anomalies and/or normal variants in the cervicovertebral region, (2) evaluate the presence and shape of STBs in patients with BAMLI, and (3) compare the findings obtained from the BAMLI and control groups. The null hypothesis was that the prevalence of skeletal anomalies and/or normal variants seen in lateral cephalometric radiographs of patients with BAMLI was similar to that of patients without dental or skeletal anomalies.

MATERIALS AND METHODS

This retrospective, case-control study was carried out with data obtained from the pretreatment records of 172 white patients who applied for treatment at Erciyes University Faculty of Dentistry Department of Orthodontics. This study was approved by the Erciyes University Local Ethics Committee (no: 2019/394). The patients were divided into two groups; a study group and a control group. The study group included 86 orthodontic patients (62 girls, 24 boys; age 12–17 years; mean age = 15.3 years) with BAMLI, and the control group included 86 orthodontic patients with no congenitally absent teeth (55 girls, 34 boys; age 13–18 years; mean age = 15.8 years). A diagnosis was made using the data obtained from clinical examination findings and standard radiographs (orthopantomographic and lateral cephalometric).

The inclusion criteria for case records were as follows: patients with dental orthopantomographic (Planmeca Proline CC 2002, Planmeca, Helsinki, Finland) and lateral cephalometric (Orthoceph OP300, Instrumentarium, Tuusula, Finland) radiographs with clear visualization of the first four cervical vertebrae for both groups, patients with congenitally

BAMLI and detailed clinical history for the study group, and patients with no absent teeth other than third molars for the control group. The exclusion criteria were trauma, dental or craniofacial anomalies or syndromes, chemotherapy affecting the musculoskeletal system, and insufficient diagnostic records.

To evaluate the differences in cervicovertebral anomalies between individuals with BAMLI and the control group, 86 patients without any dental or skeletal anomalies were found to be sufficient for the control group according to the power analysis. This group consisted of randomly selected patients who presented to the orthodontic clinic of the university between 2017 and 2019. Clinical and radiographic (with orthopantomographic and lateral cephalometric radiography) evaluation of the absence of maxillary lateral incisors was performed visually by a single author (T.O.) during patient examination. Skeletal anomalies and normal variants (PP, posterior arch deficiency of the atlas [PADA] or STB) on lateral cephalometric radiographs were detected visually by the same author. The necessary measurements to determine the skeletal classes of the patients were performed using Dolphin Imaging Software (version 11.0; Dolphin Imaging and Management Solutions, Chatsworth, Calif). Radiographs taken with the patient in a standardized natural head position were obtained by the same technician, uploaded to the Dolphin Imaging Software, and analyzed digitally.

PADA and PP were visualized on the first four cervical vertebrae on lateral profile radiographs. Data on PADA were evaluated as present or absent (Figure 1).^{1,5} Calcification of the atlanto-occipital ligament, called “arcuate foramen” or “PP,” was evaluated visually and scored using a standardized method.^{3,10,19} It was scored according to the degree of atlanto-occipital ligament ossification as no calcification

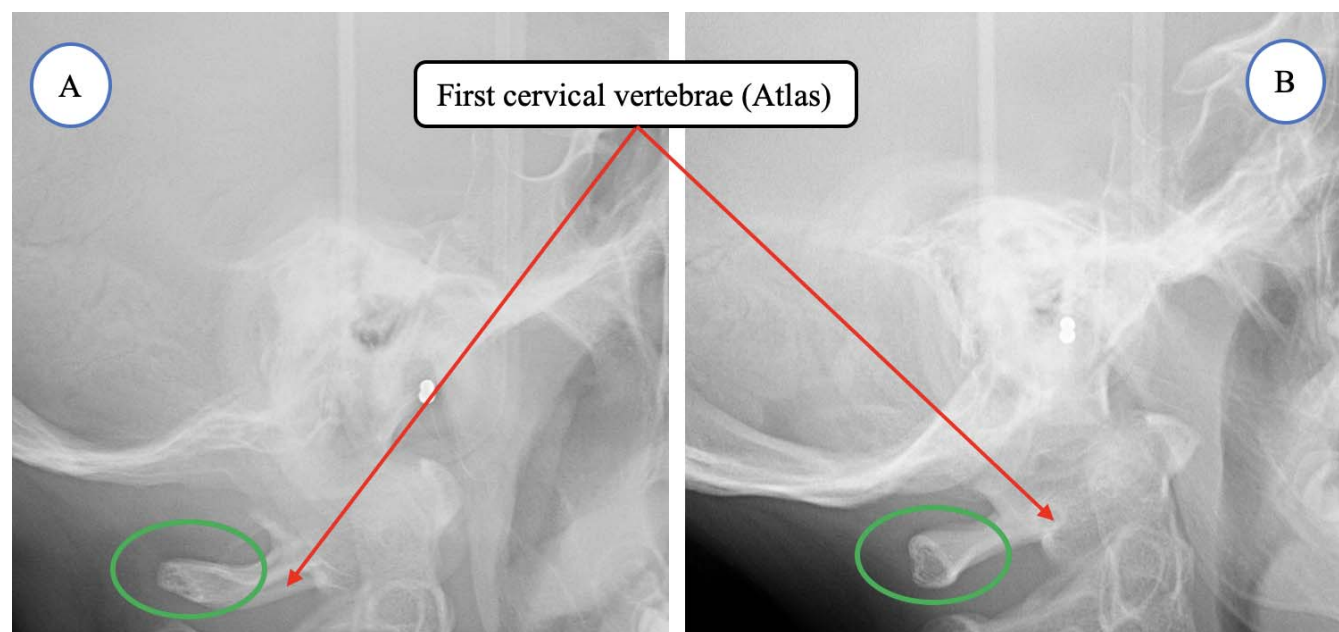


Figure 2. Analysis was performed on cephalometric films. The first cervical vertebra (atlas) area was evaluated. (A) There is a deficiency of the posterior arch in the atlas bone. (B) There is no posterior arch deficiency.

(absent), partial calcification (incomplete), or complete calcification (complete) (Figure 2). The presence of STB has been previously demonstrated on lateral cephalometric radiographs.^{6,20,21} The presence of STB was scored according to the degree of interclinoid ligament (ICL) calcification as no calcification of ICL (initial form), little or half calcification of ICL (partial form), or complete calcification of ICL (complete form) (Figure 3).

Statistical Analyses

Power analysis was used to determine that 172 patients were sufficient for the study and control groups

to establish a statistically significant difference between cervicovertebral anomalies and dental anomalies. Statistical comparisons for the evaluation of BAMLIs and skeletal anomalies and/or normal variants and intragroup evaluation included Pearson χ^2 test, Fisher exact test, and binary logistic regression analysis. Statistical Package for the Social Sciences (SPSS version 24.0 Inc, Chicago, Ill) software was used for all statistical analyses. Statistical significance was determined at $P < .05$.

To determine intraobserver error, cephalometric analysis of 43 randomly selected radiographs was repeated by the same author at a 2-week interval. The

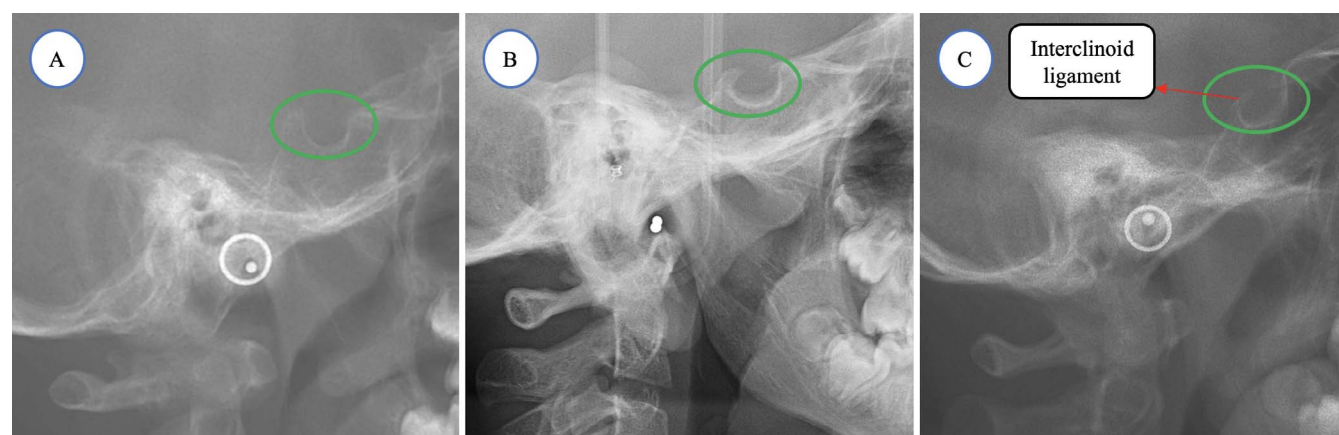


Figure 3. The sella turcica area was evaluated. (A) The interclinoid ligament is not calcified (no presence of sella turcica bridging). (B) The interclinoid ligament is partially calcified (sella turcica bridging is partially present). (C) The interclinoid ligament is fully calcified (sella turcica bridging completely present).

Table 1. Age and Gender Distribution of Patient Samples

Age Group (y)	N	%	Mean	SD	Girls		Boys	
					N	%	N	%
12–14	55	32.0	13.07	0.61	38	69.1	17	30.9
14–16	52	30.2	14.98	0.46	38	73.1	14	26.9
16–18	67	37.8	17.05	0.54	41	63.1	24	36.9
Total	172	100.0	15.15	1.75	117	68.0	55	32.0

degree of random error was evaluated as recommended by Dahlberg²² and Houston.²³

RESULTS

The errors for the length and diameter measurements made to determine the amount of STB were between 0.13 mm and 0.17 mm, and no statistical significant difference was found ($P > .05$). It was therefore concluded that these errors would not constitute a bias risk. Data regarding the age and gender distribution for the study sample are reported in Table 1.

The prevalence of the atlanto-occipital ligament (PP) in all patients included in the study group varied among complete, incomplete, and absent as the age of the patient increased (Table 2). The prevalence of PP complete and PP incomplete was 61.1% and 56.9%, respectively, in the 16–18 year age group. Similar to PP, the prevalence of PADA decreased with increasing age (Table 2). These differences were statistically significant ($P < .001$).

Compared with BAMLI (3.4%), PP was completely calcified in a significantly greater number of patients in the control group (17.4%). The prevalence of partially calcified PP was 32.6% in the control group and 43.0% in the experimental group. The prevalence of uncalcified atlanto-occipital ligament in both groups was similar. These results were found to be statistically

different when analyzed using Pearson χ^2 test ($P = .009$) and Fisher exact test ($P = .008$) (Table 3).

The prevalence of PADA was significantly higher in patients with BAMLI (29.1%) than in the control group (17.6%) using Pearson's χ^2 test ($P < .001$) and Fisher exact test ($P < .001$) (Table 4).

The prevalence of initial form and complete form STB was found to be higher in patients with BAMLI than in the control group, while incomplete STB prevalence was found to be higher in the control group. However, no statistically significant difference was found ($P > .05$) (Table 5).

The relationship between STB, PP, and PADA was investigated and found to be statistically insignificant ($P > .05$).

DISCUSSION

Skeletal anomalies and/or normal variants in cervical vertebrae are known to be associated with various syndromes.⁷ In addition, these anomalies in the cervical vertebrae have been previously reported to be associated with dental anomalies (such as hypodontia, hyperdontia, and palatally displaced canine impaction),^{1,2,5,10} maxillofacial malformations,¹⁰ and condylar and vertical craniofacial morphology.^{10,24,25} Additionally, the prevalence of PP formation has been reported in patients with craniofacial problems¹⁰ and dental anomalies^{1,14} and has also been reported to be associated with certain diseases and syndromes.⁷ The

Table 2. BAMLI, PP, PADA, and STB Among Age Groups^a

		Age Groups (y)						Pearson χ^2		Fisher Exact Test	
		12–14		14–16		16–18					
		n	%	n	%	n	%	Value	<i>P</i> *	Value	<i>P</i> *
BAMLI	Absent	22	25.3	26	29.9	39	44.8	4.777	.092	4.896	.095
	Present	33	38.8	26	30.6	26	30.6				
PP	Absent	47	52.8	25	28.1	17	19.1	1.769	<.001	1.876	<.001
	Incomplete	5	7.7	23	35.4	37	56.9				
	Complete	3	16.7	4	22.2	11	61.1				
PADA	Present	20	50.0	15	37.5	5	12.5	27.135	<.001	27.679	<.001
	Absent	28	21.2	40	30.3	61	46.2				
STB	Initial form	24	40.7	19	32.2	16	27.1	11.375	.287	10.989	.284
	Incomplete form	22	26.8	24	29.3	36	43.9				
	Complete form	9	29.0	9	29.0	13	42.0				

^a APA indicates posterior arch deficiency of atlas; BAMLI, bilateral absent maxillary lateral incisor; PADA, posterior arch deficiency atlas; PP, ponticulus posticus; STB, sella turcica bridging.

* Statistical significance $P < .05$.

Table 3. Ponticulus Posticus Among Patients (Bilateral Absent Maxillary Lateral Incisor) and Control Patients

Ponticulus Posticus	Maxillary Lateral Incisor				Pearson's χ^2		Fisher Exact Test	
	Present (Control)		Absent (Study)		Value	P^*	Value	P^*
	n	%	n	%				
No calcification (absent)	43	50.0	46	53.5	9.347	.009	8.987	.008
Incomplete calcification	28	32.6	37	43.0				
Completely calcified	15	17.4	3	3.5				
Total	86	100.0	86	100.0				

* Statistical significance $P < .05$.

results of this study showed that the prevalence of PP formation decreased and PADA increased in patients with BAMLIs.

In the absence of any clinical signs or symptoms, STB is considered to be a normal variant, although it is known to be affected by pathological processes.²⁶ It has been shown that the prevalence of STB formation increases in individuals with various syndromes,²⁷ craniofacial problems,²⁸ and dental anomalies.^{6,20,21} In a study conducted by Scribante et al.,²⁰ there was a relationship between sella turcica morphology and BAMLIs. The prevalence of completely calcified ICL was lower in patients with BAMLIs than in the control group. However, although the results in the current study did not differ significantly, the prevalence of completely calcified ICL was found to be higher in patients with BAMLIs than in the control group. This finding was thought to be due to the investigation of BAMLIs and the asymmetric distribution of boys and girls.

In patients with BAMLIs, partial PP prevalence was increased (study group 43.0%; control group 32.6%) and completely calcified PP prevalence was decreased (study 3.5% group; control group 17.4%) compared with the control group. In agreement with previous studies, this study showed that the prevalence of fully calcified PP was decreased in patients with tooth agenesis¹⁴ and that there was a relationship between dental anomalies and skeletal variations.^{1,2,24,25}

The prevalence of PADA was higher in patients with absent MLI (29.1%) than in the control sample (17.6%). Cervical vertebral fusion was not examined. Because cervical vertebral fusion is evaluated by radiography, the distances between the vertebrae should be examined more frequently using extension and flexion

radiographs as used in orthopedic medicine.²⁹ This finding was consistent with previous literature that stated that there was a relationship between dental anomalies and cervicovertebral anomalies and/or normal variants.^{1,5,30} Specifically, the data obtained in this study indicated that skeletal anomalies and/or normal variants found in lateral cephalometric radiographs were associated with craniofacial and jaw morphology, skeletal malocclusions, occlusion, and dental anomalies (such as congenitally missing teeth).

The effect of NCCs and various genes (homebox and hox) contributing to the formation of many parts of the cervicovertebral area and oral cavity seems to explain the relationship between dental and skeletal anomalies.^{17,24,31} Therefore, it can be assumed that the factors directing the development of the neck, shoulder, and craniofacial region are under the control of a common gene structure and NCCs.³¹ Additionally, because of the similar cellular differentiation of mineralized structures, such as skeletal and dental structures,^{32–34} their anomalies may be related.

The etiology of tooth agenesis, which has been discussed for a long time and has not been precisely determined, is likely influenced by genetics, dental trauma, various infections, chemotherapy, radiotherapy, and environmental factors.³⁵ Investigations of the genetic effect determined that there was a relationship between familial predisposition, dental anomalies, and tooth agenesis.^{16,36} This assumption supports the effect of genes. In this context, the current findings suggested that presence of BAMLIs was not only related to other tooth and skeletal anomalies but also to the variants of cervical vertebra. Tooth agenesis is a clinical finding that is associated with many diseases and is even effective for the diagnosis of these diseases.³⁷ Indeed, BAMLIs, often combined with other clinical features,

Table 4. Posterior Arch Deficiency of Atlas (PADA) Among Patients (Bilateral Absent Maxillary Lateral Incisor [BAMLI]) and Control Patients

	Present (Control)		BAMLI (Study)		Pearson χ^2		Fisher Exact Test	
	n	%	n	%	Value	P^*	Value	P^*
Present	15	17.6	25	29.1	13.341	<.001	13.134	<.001
Absent	71	82.4	61	70.9				
Total	86	100.0	86	100.0				

* Statistical significance $P < .05$.

Table 5. Sella Turcica Bridging (STB) Among Patients (Bilateral Absent Maxillary Lateral Incisor) and Control Patients

	Present (Control)		Absent (Study)		Pearson's χ^2		Fisher Exact Test	
	n	%	n	%	Value	P*	Value	P*
Interclonoid Ligament Calcification								
Initial form	27	31.4	32	37.6	2.274	0.321	2.346	.328
Partial form	45	52.3	37	42.4				
Complete form	14	16.3	17	20.0				
Total	86	100.0	86	100.0				

* Statistical significance $P < .05$.

can be considered as a part of an observable syndrome.

The null hypothesis was therefore partially rejected. The results of this study should encourage further investigation of the molecular and cellular relationship of dentofacial structures and skeletal and other anomalies. This relationship, supported by the findings of further studies, may increase the chances of diagnosing problems during routine examinations. In addition, when evaluated clinically, these skeletal anomalies and/or normal variants associated with BAMLI will allow clinicians to evaluate congenital absence more easily and accurately.

CONCLUSIONS

- The present report showed a statistically significant relationship between tooth deficiency and the prevalence of cervical vertebrae anomalies in patients with BAMLI compared with the control group.
- Both PADA and PP deficiency were found in individuals with BAMLI.
- The relationship between cervicovertebral anomalies and BAMLI predicts the presence of tooth deficiency in later life and can be used to diagnose these skeletal anomalies and/or normal variants for early detection measures.

REFERENCES

- Leonardi R, Barbato E, Vichi M, Caltabiano M. Skeletal anomalies and normal variants in patients with palatally displaced canines. *Angle Orthod.* 2009;79:727–732.
- Adisen MZ, Misirlioglu M. Prevalence of ponticulus posticus among patients with different dental malocclusions by digital lateral cephalogram: a comparative study. *Surg Radiol Anat.* 2017;39:293–297.
- Giri J, Pokharel PR, Gyawali R. How common is ponticulus posticus on lateral cephalograms? *BMC Res Notes.* 2017;10:172.
- Gungor AY, Turkkahraman H. Effects of severity and location of nonsyndromic hypodontia on craniofacial morphology. *Angle Orthod.* 2013;83:584–590.
- Haji Ghadimi M, Amini F, Hamed S, Rakhshan V. Associations among sella turcica bridging, atlas arcuate foramen (ponticulus posticus) development, atlas posterior arch deficiency, and the occurrence of palatally displaced canine impaction. *Am J Orthod Dentofacial Orthop.* 2017;151:513–520.
- Leonardi R, Barbato E, Vichi M, Caltabiano M. A sella turcica bridge in subjects with dental anomalies. *Eur J Orthod.* 2006;28:580–585.
- Lachman RS. The cervical spine in the skeletal dysplasias and associated disorders. *Pediatr Radiol.* 1997;27:402–408.
- Kjaer I, Becktor KB, Lisson J, Gormsen C, Russell BG. Face, palate, and craniofacial morphology in patients with a solitary median maxillary central incisor. *Eur J Orthod.* 2001;23:63–73.
- Tambawala SS, Karjodkar FR, Sansare K, et al. Prevalence of ponticulus posticus on lateral cephalometric radiographs, its association with cervicogenic headache and a review of literature. *World Neurosurg.* 2017;103:566–575.
- Pérez IE, Chávez AK. Frequency of ponticulus posticus, sella turcica bridge and clinoid enlargement in cleft lip and palate peruvian patients: a comparative study with non-cleft patients. *Int. J. Morphol.* 2015;33:895–901.
- Kendrick GS, Biggs NL. Incidence of the ponticulus posticus of the first cervical vertebra between ages six to seventeen. *Anat Rec.* 1963;145:449–453.
- Cederberg RA, Benson BW, Nunn M, English JD. Arcuate foramen: prevalence by age, gender, and degree of calcification. *Clin. Orthod. Res.* 2000;3:162–167.
- Bayrakdar IS, Miloglu O, Altun O, Gumussoy I, Durna D, Yilmaz AB. Cone beam computed tomography imaging of ponticulus posticus: prevalence, characteristics, and a review of the literature. *Oral Surg Oral Med Oral Pathol Oral Radiol.* 2014;118:e210–219.
- Putrino A, Leonardi RM, Barbato E, Galluccio G. The association between ponticulus posticus and dental agenesis: a retrospective study. *Open Dent J.* 2018;12:510–519.
- Tavajohi-Kermani H, Kapur R, Sciote JJ. Tooth agenesis and craniofacial morphology in an orthodontic population. *Am J Orthod Dentofacial Orthop.* 2002;122:39–47.
- Matalova E, Fleischmannova J, Sharpe PT, Tucker AS. Tooth agenesis: from molecular genetics to molecular dentistry. *J Dent Res.* 2008;87:617–623.
- Wang SK, Komatsu Y, Mishina Y. Potential contribution of neural crest cells to dental enamel formation. *Biochem Biophys Res Commun.* 2011;415:114–119.
- Matsuoka T, Ahlberg PE, Kessaris N, et al. Neural crest origins of the neck and shoulder. *Nature.* 2005;436:347–355.
- Hasan M, Shukla S, Siddiqui MS, Singh D. Posterolateral tunnels and ponticuli in human atlas vertebrae. *J Anat.* 2001;199:339–343.
- Scribante A, Sfondrini MF, Cassani M, Fraticelli D, Beccari S, Gandini P. Sella turcica bridging and dental anomalies: is there an association?. *Int J Paediatr Dent.* 2017;27:568–573.

21. Leonardi R, Farella M, Cobourne MT. An association between sella turcica bridging and dental transposition. *Eur J Orthod*. 2011;33:461–465.
22. Dahlberg G. *Statistical Methods for Medical and Biological Students*. London: George Allen and Unwin; 1940:98.
23. Houston W. The analysis of errors in orthodontic measurements. *Am J Orthod*. 1983;83:382–390.
24. Sonnesen L, Pedersen CE, Kjaer I. Cervical column morphology related to head posture, cranial base angle, and condylar malformation. *Eur J Orthod*. 2007;29:398–403.
25. Sonnesen L, Kjaer I. Cervical vertebral body fusions in patients with skeletal deep bite. *Eur J Orthod*. 2007;29:464–470.
26. Kantor ML, Norton LA. Normal radiographic anatomy and common anomalies seen in cephalometric films. *Am J Orthod Dentofacial Orthop*. 1987;91:414–426.
27. Korayem M, AlKofide E. Size and shape of the sella turcica in subjects with Down syndrome. *Orthod Craniofac Res*. 2015;18:43–50.
28. Becktor JP, Einersen S, Kjaer I. A sella turcica bridge in subjects with severe craniofacial deviations. *Eur J Orthod*. 2000;22:69–74.
29. Guille JT, Sherk HH. Congenital osseous anomalies of the upper and lower cervical spine in children. *J Bone Joint Surg Am*. 2002;84:277–288.
30. Tetradis S, Kantor ML. Prevalence of skeletal and dental anomalies and normal variants seen in cephalometric and other radiographs of orthodontic patients. *Am J Orthod Dentofacial Orthop*. 1999;116:572–577.
31. Miletich I, Sharpe PT. Neural crest contribution to mammalian tooth formation. *Birth Defects Res C Embryo Today*. 2004;72:200–212.
32. Morotomi T, Kawano S, Toyono T, et al. In vitro differentiation of dental epithelial progenitor cells through epithelial-mesenchymal interactions. *Arch Oral Biol*. 2005;50:695–705.
33. Abou Neel EA, Aljabo A, Strange A, et al. Demineralization-remineralization dynamics in teeth and bone. *Int J Nanomedicine*. 2016;11:4743–4763.
34. Abdel Meguid E, Ke Y, Ji J, El-Hashash AHK. Stem cells applications in bone and tooth repair and regeneration: new insights, tools, and hopes. *J Cell Physiol*. 2018;233:1825–1835.
35. Miletich I, Sharpe PT. Normal and abnormal dental development. *Hum Mol Genet*. 2003;12(special No 1): R69–R73.
36. Choi SJ, Lee JW, Song JH. Dental anomaly patterns associated with tooth agenesis. *Acta Odontol Scand*. 2017; 75:161–165.
37. Chhabra N, Goswami M, Chhabra A. Genetic basis of dental agenesis—molecular genetics patterning clinical dentistry. *Med Oral Patol Oral Cir Bucal*. 2014;19:e112–119.