

## **Orthodontic management of a complete and an incomplete maxillary canine-first premolar transposition**

**Carmen Lorente<sup>a</sup>; Pedro Lorente<sup>b</sup>; Maria Perez-Vela<sup>b</sup>; Cristina Esquinas<sup>c</sup>; Teresa Lorente<sup>a</sup>**

### **ABSTRACT**

Maxillary canine and first premolar transposition is a complicated dental anomaly to treat, especially if the clinician's goal is to orthodontically move the canine into its normal position. Early diagnosis with cone-beam computed tomography simplifies the treatment of this pathology. This case report describes a patient with bilateral transposition, one complete and the other incomplete, involving the maxillary canine and the first premolar (Mx.C.1P). The orthodontic treatment involved the correction of both transpositions. In the complete transposition, the traction was mesial and upward to move the canine into a more apical position with a wider dentoalveolar process for easier crown interchange. (*Angle Orthod.* 2020;90:457–466.)

**KEY WORDS:** Ectopic tooth eruption; Bilateral transposition; Mx.C.1P; Cone-beam computed tomography (CBCT); Orthodontic biomechanics

### **INTRODUCTION**

Tooth transposition is the positional interchange of two adjacent teeth or the development or eruption of a tooth in a position normally occupied by a nonadjacent tooth.<sup>1–3</sup> Transposition can be complete when both teeth have been completely transposed (crowns and roots) or incomplete when only the crowns or roots have interchanged their positions.<sup>4–7</sup> Etiologic factors such as genetic inheritance,<sup>7–9</sup> interchange of the position of the developing tooth buds,<sup>5,10</sup> trauma,<sup>7,11</sup> early loss of permanent teeth,<sup>8,12</sup> and lack of space<sup>13</sup> have been presented in the literature. The prevalence of tooth transposition varies depending on the population,<sup>14</sup> but low incidence is common to all (0.2%–0.4%).<sup>8,9,15,16</sup>

The effect of sex is unclear. Some studies have found that transpositions are more common in females<sup>3,17</sup> and others in males,<sup>9</sup> and some reported that there are no differences between the sexes.<sup>18</sup>

Transpositions occur more frequently in the maxilla than in the mandible,<sup>9</sup> and unilateral transpositions are more common than bilateral: 88% vs 12%, respectively.<sup>19</sup> The most frequent type of transposition involves a maxillary canine and a first premolar.<sup>4,8,20</sup>

There are several treatment options in these cases: tooth extraction if the degree of crowding requires it, posterior space closure, tooth extraction with posterior implant replacement, surgical repositioning, a surgical-orthodontic approach to reverse and correct the transposition, or orthodontic treatment that leaves the teeth transposed. At present, cone-beam computed tomography (CBCT) is the best method to ensure an accurate assessment and determine the feasibility of treating a transposition. If a surgical-orthodontic approach is necessary, assessing the position of a transposed tooth is crucial for determining the correct access and selecting the best direction in which to apply orthodontic forces.<sup>21</sup>

This case report discusses a bilateral Mx.C.1P transposition. The first quadrant involved a complete transposition and the second quadrant an incomplete transposition. The treatment of choice was the correction of both transpositions; the patient was previously informed of the associated risks and longer treatment time.

### **CASE REPORT**

#### **Diagnosis and Etiology**

A 12-year-old boy was referred for orthodontic assessment. His chief complaint was the position of

<sup>a</sup> Postdoctoral Researcher, Department of Human Anatomy and Histology, University of Zaragoza and Private practice, Zaragoza, Spain.

<sup>b</sup> Private practice, Zaragoza, Spain.

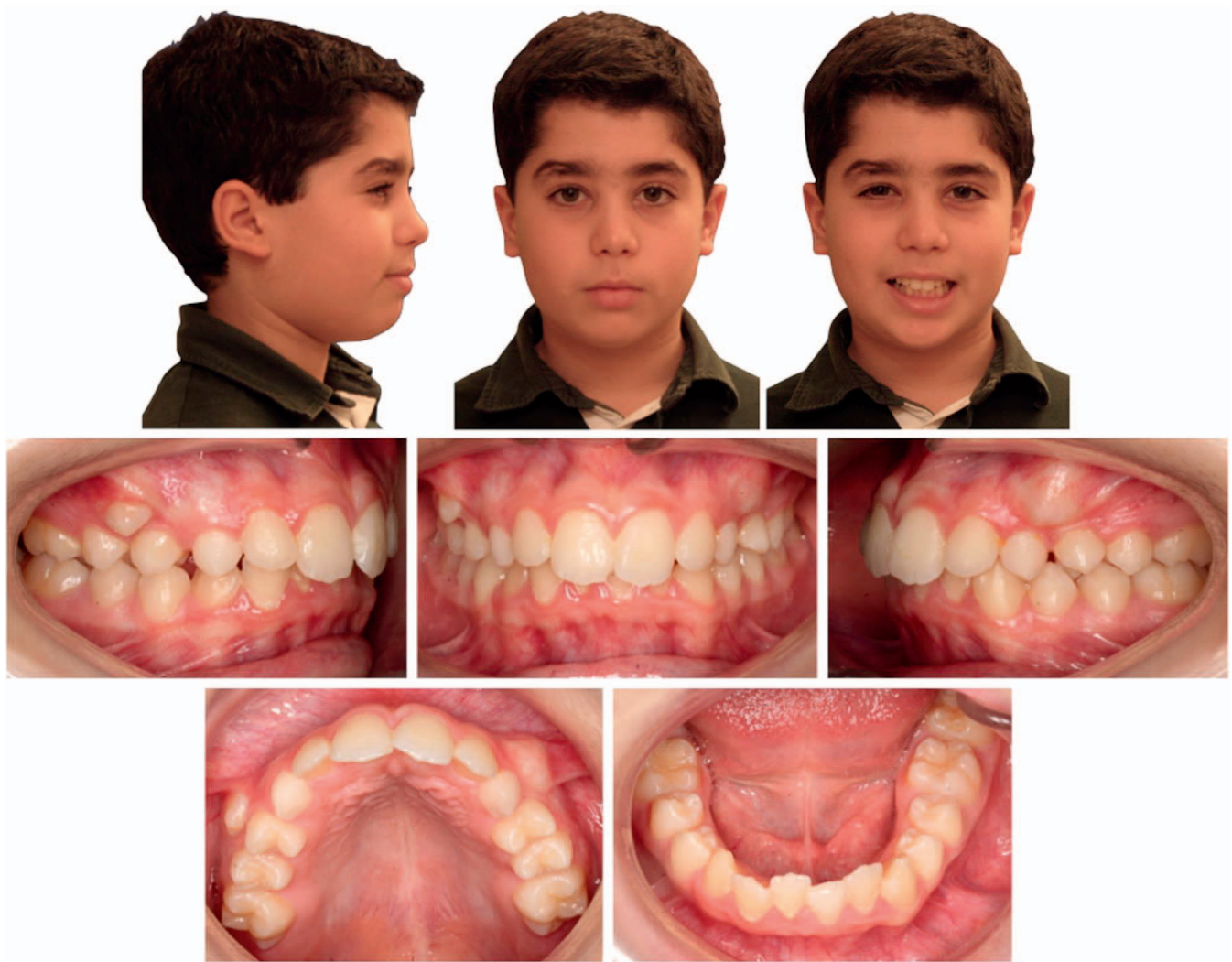<sup>c</sup> Biostatistician, Valle de Hebrón Hospital Research Institute, Barcelona, Spain.

Corresponding author: Dr Carmen Lorente, Lorente Clinic, Av. Paseo de la Constitución 29 (local), Zaragoza 50001, Spain (e-mail: carmen@lorenteortodoncia.com)

Accepted: December 2018. Submitted: August 2018.

Published Online: April 23, 2019

© 2020 by The EH Angle Education and Research Foundation, Inc.



**Figure 1.** Pretreatment facial and intraoral photographs.

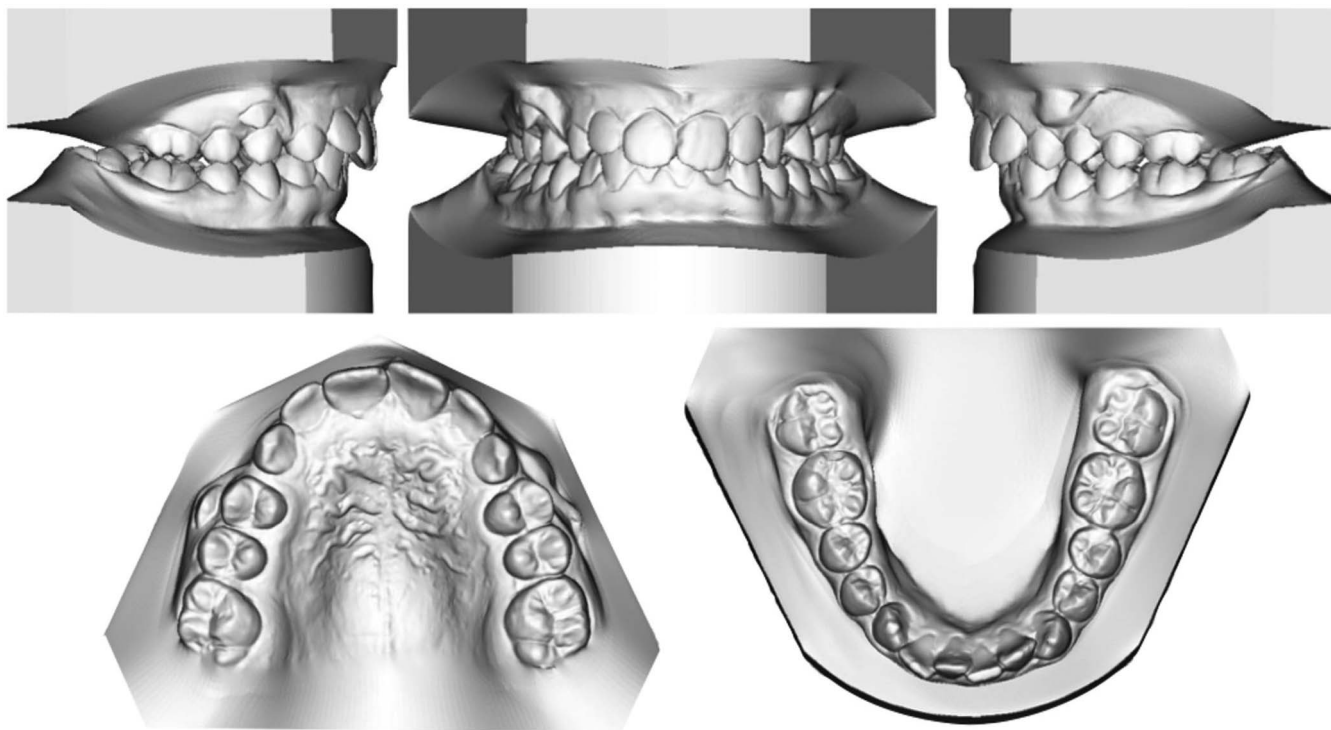
his maxillary right canine. The patient had no history of systemic disease or comorbidity and demonstrated a normal temporomandibular joint examination. Pretreatment facial examination showed a balanced and esthetic, convex soft tissue profile. The frontal view showed no gross asymmetry and acceptable smile characteristics (Figure 1).

Intraoral and dental cast examinations demonstrated a Class I molar relationship on the left side and a slight Class II molar relationship on the right side, with the lower midline shifted to the right side. The maxillary deciduous canines were present (Figure 2). A complete maxillary canine-first premolar transposition on the right side and an incomplete maxillary canine-first premolar transposition on the left side were diagnosed. Low frenal attachments were seen bilaterally, mesial to the right permanent canine crown and distal to the left permanent canine. Panoramic and lateral cephalomet-

ric radiographs and the CBCT scan were taken before treatment. Radiographic imaging showed a mixed dentition due to the maxillary deciduous teeth being retained. CBCT confirmed the complete and the incomplete transposition suspected clinically. No dental or bone pathology was evident (Figure 3). The cephalometric analysis confirmed a Class II skeletal relationship with protrusive maxillary incisors (Table 1).

### Treatment Objectives

The overall objective was to provide the patient with improved esthetics and a functional occlusion. To achieve this result, the specific treatment objectives were to (1) orthodontically correct the complete Mx.C.1P in the first quadrant to restore natural order, (2) orthodontically correct the incomplete Mx.C.1P in the second quadrant, (3) level and align the arches



**Figure 2.** Pretreatment digital 3D dental casts.

while maintaining a correct overjet and overbite, (4) correct the midlines, and (5) achieve Class I molar and canine relationships.

### Treatment Alternatives

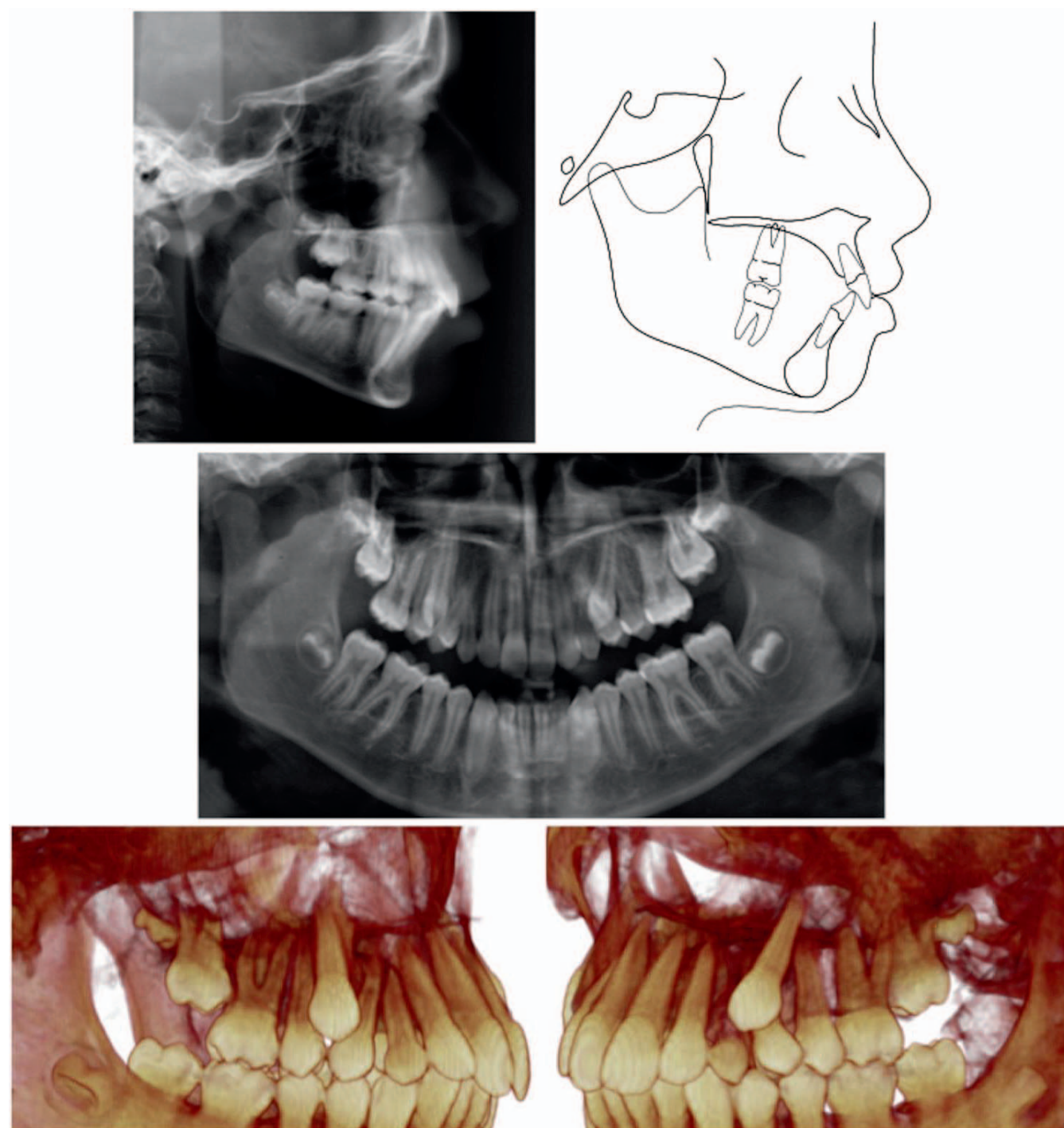
Two treatment alternatives were presented. The first involved the alignment of the teeth in their transposed positions followed by periodontal surgery and functional reshaping to achieve occlusal adjustment and restorative prosthetic camouflage. Although this option was more predictable, it was rejected because it required long-term maintenance, and the patient and his parents did not want postorthodontic restorations. The second alternative included repositioning of the transposed canines into their correct positions. This treatment plan was selected as it provided better final esthetics and functional results despite the risk of root resorption, more complex biomechanics, and increased treatment time.

### Treatment Progress

The patient was initially referred to the local dentist for removal of the primary canines. After extractions, the patient returned, and fixed appliances (Roth 0.022  $\times$  0.028-inch slot metal brackets) were placed in the maxillary and mandibular arch. Bands were placed on the first molars with a removable transpalatal bar.

No bracket was placed on the first premolar on the right side to allow freedom of root movement when tractioning the canine mesially. However, a button was bonded on the palatal surface of the premolar and attached loosely to the palatal bar to avoid unwanted mesial displacement. No surgical procedure was needed to access the maxillary right canine, and a button was bonded directly to the buccal surface. A cantilever spring of 0.019  $\times$  0.025-inch rectangular stainless-steel wire coupled to the auxiliary band tube was used to pull the canine in a mesial and apical direction. The aim was to correct the transposition by bringing the canine to the widest part of the dentoalveolar process where more bone width was available. Therefore, it was easier to correct the transposition and minimize the amount of periodontal recession. Activation was performed with an elastic thread every 2–3 weeks. On the left side, there was an incomplete Mx.C.1P transposition in which the roots were transposed but not the crowns. In this case, the correction involved less crown movement than in the complete transposition described earlier. This transposition was resolved with minimal canine crown exposure under local anesthesia and a bracket bonded to it. A 0.016-inch nickel-titanium wire was placed to start the canine alignment. To facilitate the interchange of the canine and the first premolar roots, the first premolar was





**Figure 3.** Pretreatment lateral cephalometric and panoramic radiographs, and 3D images generated using Dolphin software.

not included in the archwire, allowing freedom of movement while the canine was corrected and therefore decreasing the risk of resorption. To avoid root conflict, the brackets of both lateral incisors were bonded with a slight mesial root tip (Figure 4A).

After 6 months of treatment, the apical movement and mesialization of the right canine was evident. When the canine no longer posed a risk, the maxillary right first premolar bracket was included in the arch. On the left side, the first premolar was engaged into the archwire (Figure 4B).

**Table 1.** Cephalometric Measurements

| Measurement           | Norm | Pretreatment | Posttreatment |
|-----------------------|------|--------------|---------------|
| SNA, °                | 82   | 87.4         | 84            |
| SNB, °                | 80   | 79.4         | 80            |
| ANB, °                | 2    | 8            | 4.3           |
| Interincisal angle, ° | 130  | 125.6        | 121.9         |
| Mx1 to A-Po, mm       | 3.5  | 8.3          | 6             |
| Md1 to A-Po, mm       | 1    | 2.8          | 2.9           |
| Upper lip, mm         | -4   | -0.2         | -1            |
| Lower lip, mm         | -2   | 4            | 2.9           |

Once the transposition was resolved 22 months after the start of treatment, the brackets of the lateral incisors were rebonded to their correct positions. Six months later, further crown torque was applied by placing two Warren springs on the canines. For 1 month, a cross elastic was added from a button bonded on the palatal surface of the maxillary canine to the buccal aspect of the mandibular right canine and first premolar. The left side required Class II intermaxillary elastics for final settling (Figure 4C).

The duration of the active treatment was 38 months. After all of the appliances were removed, a fixed bonded retainer was placed in the mandible and an Essix retainer in the maxilla.

## RESULTS

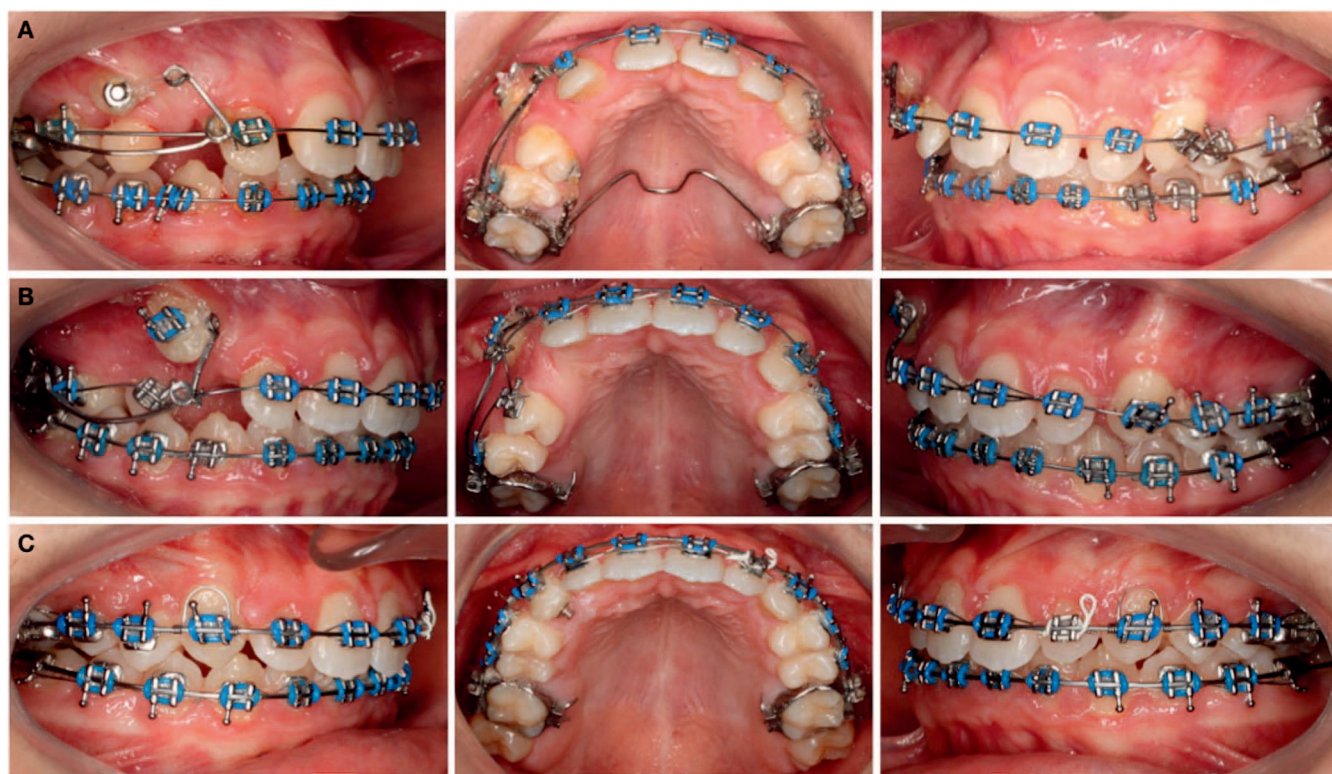
The final extraoral photographs showed smile harmony and good facial esthetics with an improvement in the facial profile (Figure 5). The intraoral and dental cast examination demonstrated that both transpositions were corrected. Good alignment of the teeth was observed while maintaining the correct overjet, overbite, and coincident midlines. A bilateral Class I molar and canine occlusion was achieved. However, in centric relation, a Class II tendency was observed in the right side of the dental casts. The maxillary right canine had a higher gingival margin, probably because of the tooth movement through the frenal attachment. The success of the final esthetic and functional results outweighed the maxillary right canine having slight recession (Figures 5 and 6).

Posttreatment CBCT showed a complete permanent dentition with the corrected transpositions without any appreciable bone loss or root resorption and proper root parallelism (Figure 7).

There was no evidence of relapse or complications 24 months after treatment (Figure 8; Table 1).

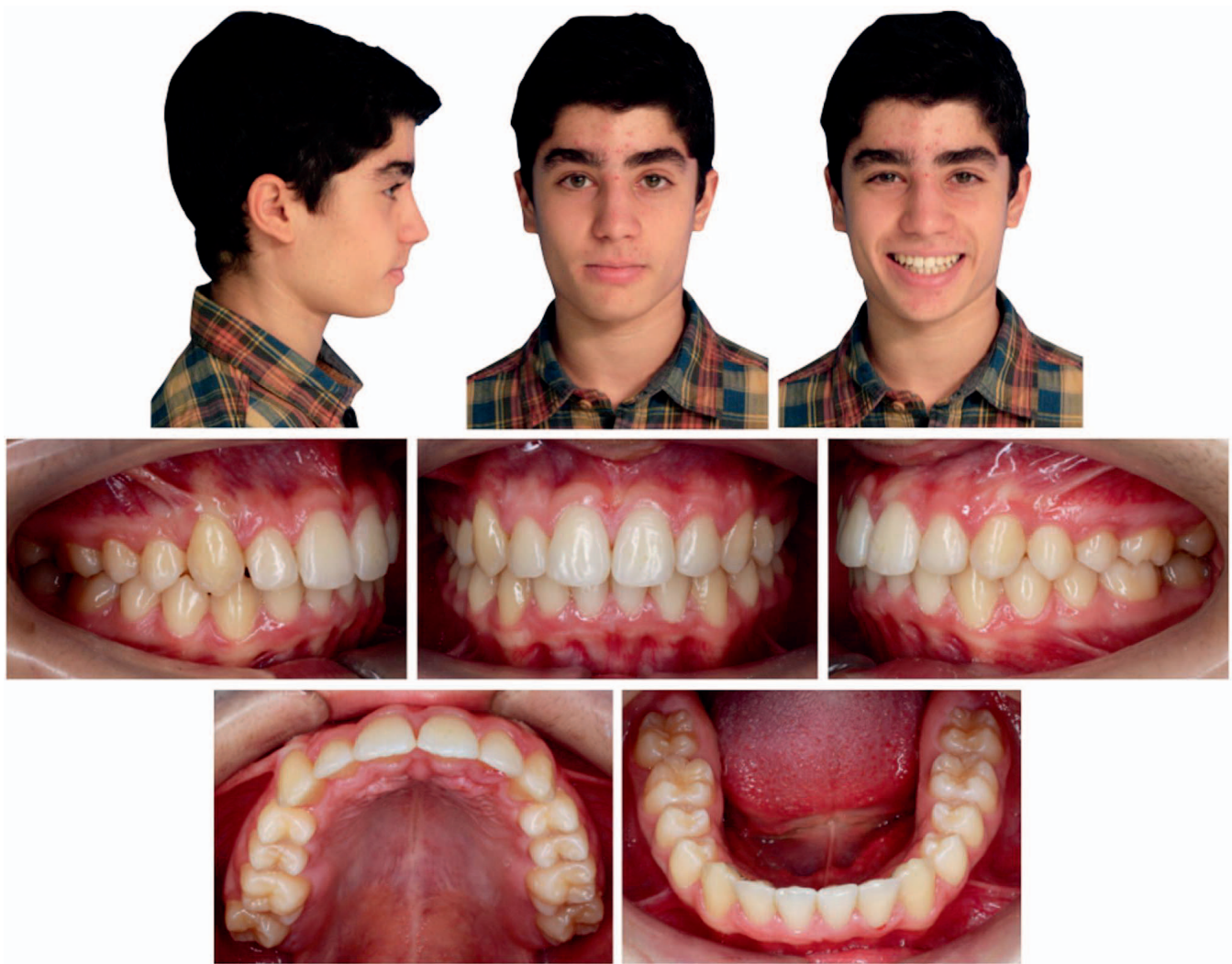## DISCUSSION

In this case, bilateral Mx.C.1P transpositions were treated successfully. Tooth transpositions most com-



**Figure 4.** Progressive intraoral photographs: (A) 2 months after the start of treatment; (B) 6 months after starting mesial traction of the right canine and after left canine surgery; (C) 28 months after the start of treatment.





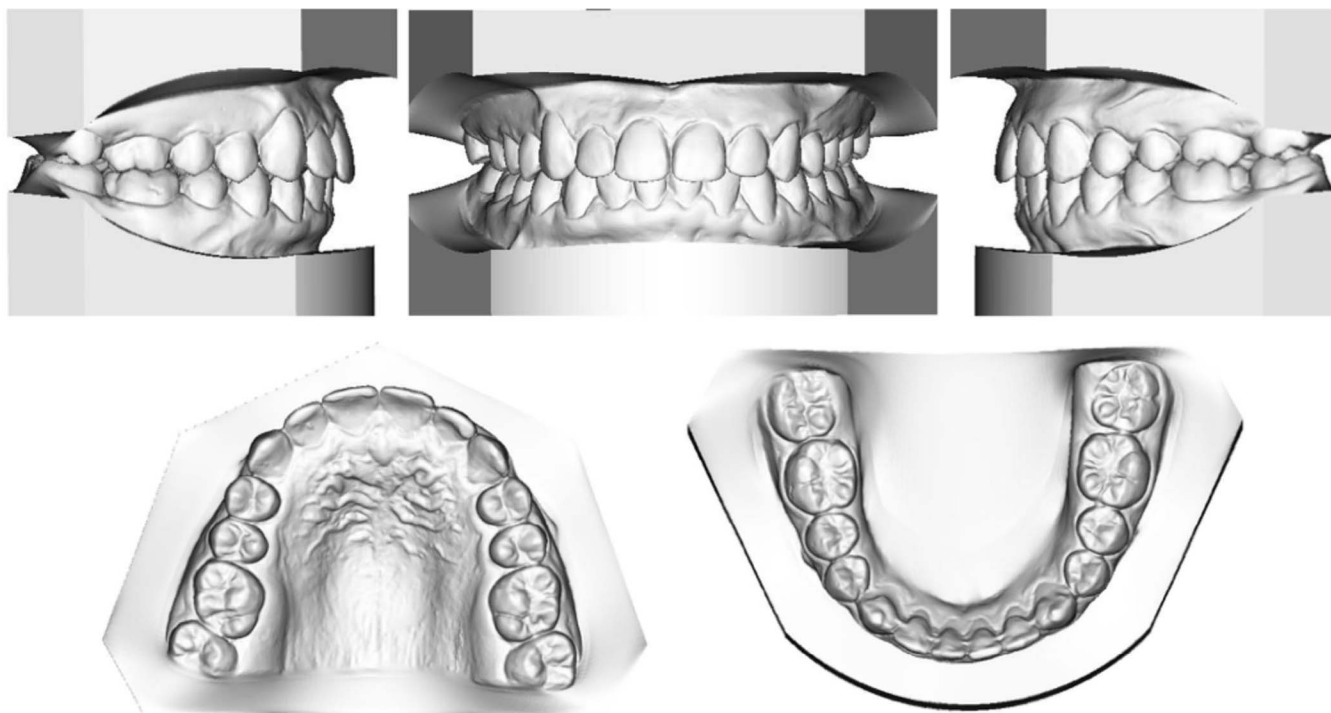
**Figure 5.** Posttreatment facial and intraoral photographs.

monly involve the canine with the first premolar or lateral incisor.<sup>3,22</sup> Peck and Peck<sup>8</sup> found that the most frequent maxillary transposition involves the maxillary canine and first premolar (71%), while only 20% involved the maxillary canine with lateral incisor.<sup>8</sup> Orthodontic correction of a dental transposition is considered a complex treatment and may be damaging to the teeth or supporting structures.<sup>4</sup> In the literature, it is highly recommended to accept and align the teeth in their transposed positions or to extract one tooth involved in the transposition.<sup>14</sup> However, other authors reported cases in which transpositions have been corrected.<sup>23,24</sup>

Canines are essential both for function, providing canine guidance for occlusion, as well as for esthetics, giving the patient correct dental and gingival symmetry.<sup>21</sup> In addition, from a facial esthetics point of view, the canine eminence provides support to the nasolabial

fold, which will help the patient have better facial aging, and a greater sense of width in the smile is achieved. If the case allows for correction of the transposition, the esthetic and functional results are improved with less long-term maintenance. However, there are several clinical considerations to take into account when planning to move the transposed teeth to their normal positions in the arch.

When correcting a transposition, some important factors to be considered include the position of the crowns and the roots within the dentoalveolar process in all three planes of space, the teeth and dental arch involved, the degree of root resorption, the patient's malocclusion, the experience of the professional, and the patient's motivation.<sup>7</sup> If the aim of the clinician is to correct the transposition, early diagnosis improves the prognosis. Regarding the position of the tooth, it is important to highlight not only the sagittal and



**Figure 6.** Posttreatment digital 3D dental casts.

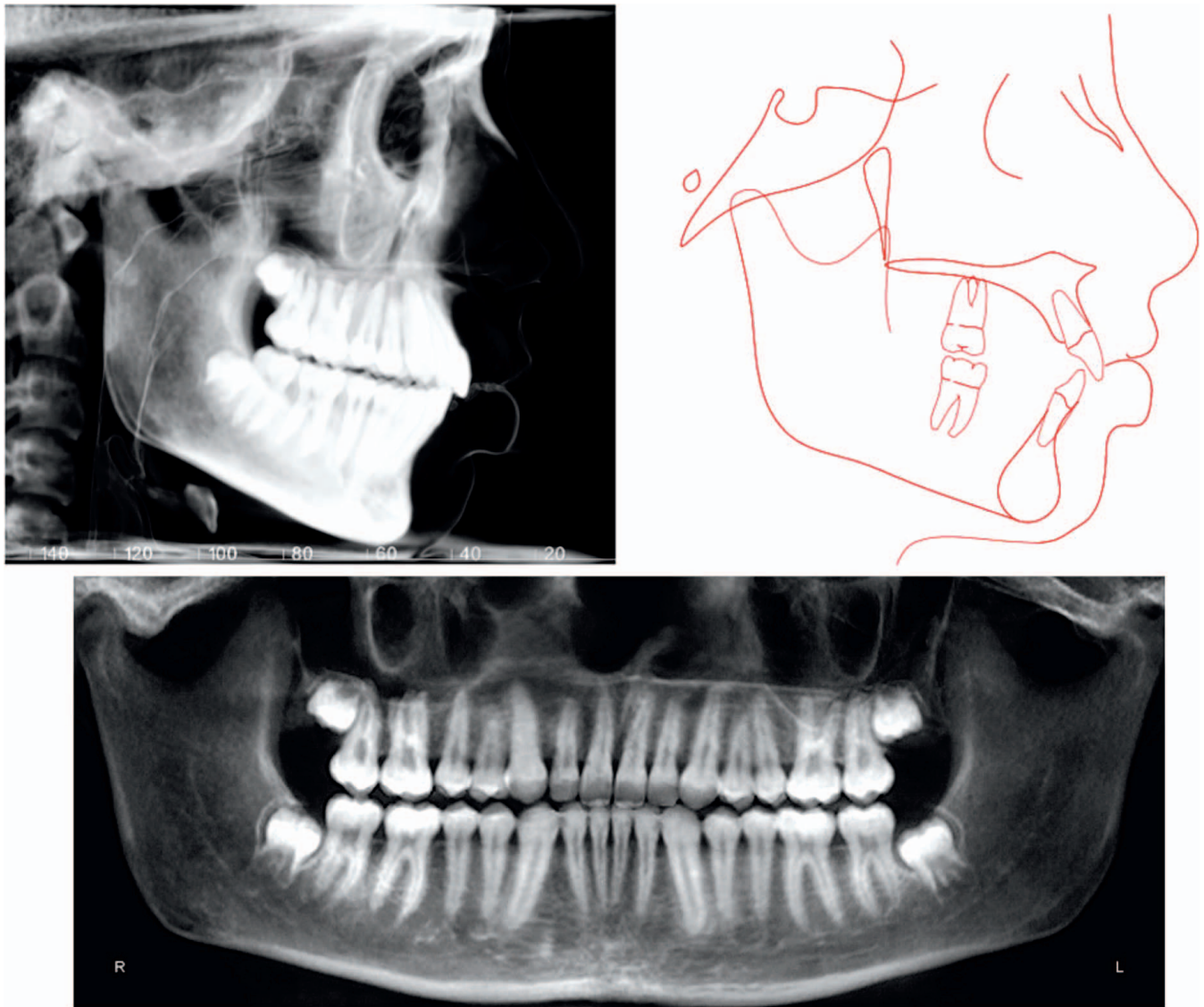
buccolingual position but also the vertical height, which is closely connected to the bone width. The less the canine has descended into its position, the wider the dentoalveolar process will be; this provides the opportunity to move the teeth within the bone and decreases the risk of negative effects.<sup>23</sup> In this case report, one of the main disadvantages was that the initial position of the canine crowns was not as high as desired to benefit the correction of the transposition. This was a challenge when designing the correct vector of traction, making the canine of the complete transposition move upward in order to avoid root contact during the displacement (Figure 4).

Treatment mechanics and appliance design need to be individualized for each patient.<sup>25</sup> This will depend on which teeth have erupted, when to pursue active traction or leave it passive, the periodontal status, and the three-dimensional (3D) tooth position to establish the direction of traction. One of the transpositions allowed direct bonding of all the teeth involved, while the other required minimal surgical exposure. When the maxillary right canine was being mesialized, the premolar was not included in the archwire to decrease the risk of resorption, and the lateral incisor brackets were bonded to tip their roots mesially. Therefore, treatment was performed with difficulty because of the complexity, which lengthened the overall treatment period.

Different types of appliances have been described to resolve transpositions, such as sectional arches, springs, and transpalatal arches.<sup>24,26</sup> In the case presented, it is important to highlight that the cantilever spring used to resolve the transposition was designed to pull the canine to the widest part of the dentoalveolar process during the transposition correction. The active part of the spring, the helix, had to be higher than the bonded button on the tooth being displaced. This made the line of force apical to the center of resistance, leading to effective root movement.<sup>27</sup> Because of the anchorage demand of moving a canine, a transpalatal bar was used to maintain the arch form and anchor the first premolar. At present, skeletal anchorage can be employed to simplify the use of auxiliary appliances.<sup>27,28</sup>

For image diagnosis, CBCT allows for more accurate 3D location of the teeth involved than conventional radiographs, which helps in the decision of the most appropriate biomechanics required to solve each transposition.<sup>26</sup> In this patient, CBCT was available at the start and end of treatment. Three-dimensional images were crucial for assessing possible pretreatment and posttreatment root resorption and for choosing the proper direction of the orthodontic force.

Resorption and recession are other important factors to take into account among the major posttreatment iatrogenic effects that concern clinicians in transposition cases.<sup>26,29</sup> Root resorption was not evident at the



**Figure 7.** Posttreatment lateral cephalometric and panoramic radiographs extracted from the CBCT showing good root parallelism and no resorption.

end of treatment, while slight recession at the maxillary right canine was apparent after treatment.

One of the most complex challenges for an orthodontist is correcting a transposition. The results showed that an early and 3D diagnosis is essential to select the best mechanics and design the correct traction to avoid complications such as periodontal compromise or root resorption of the adjacent or involved teeth.

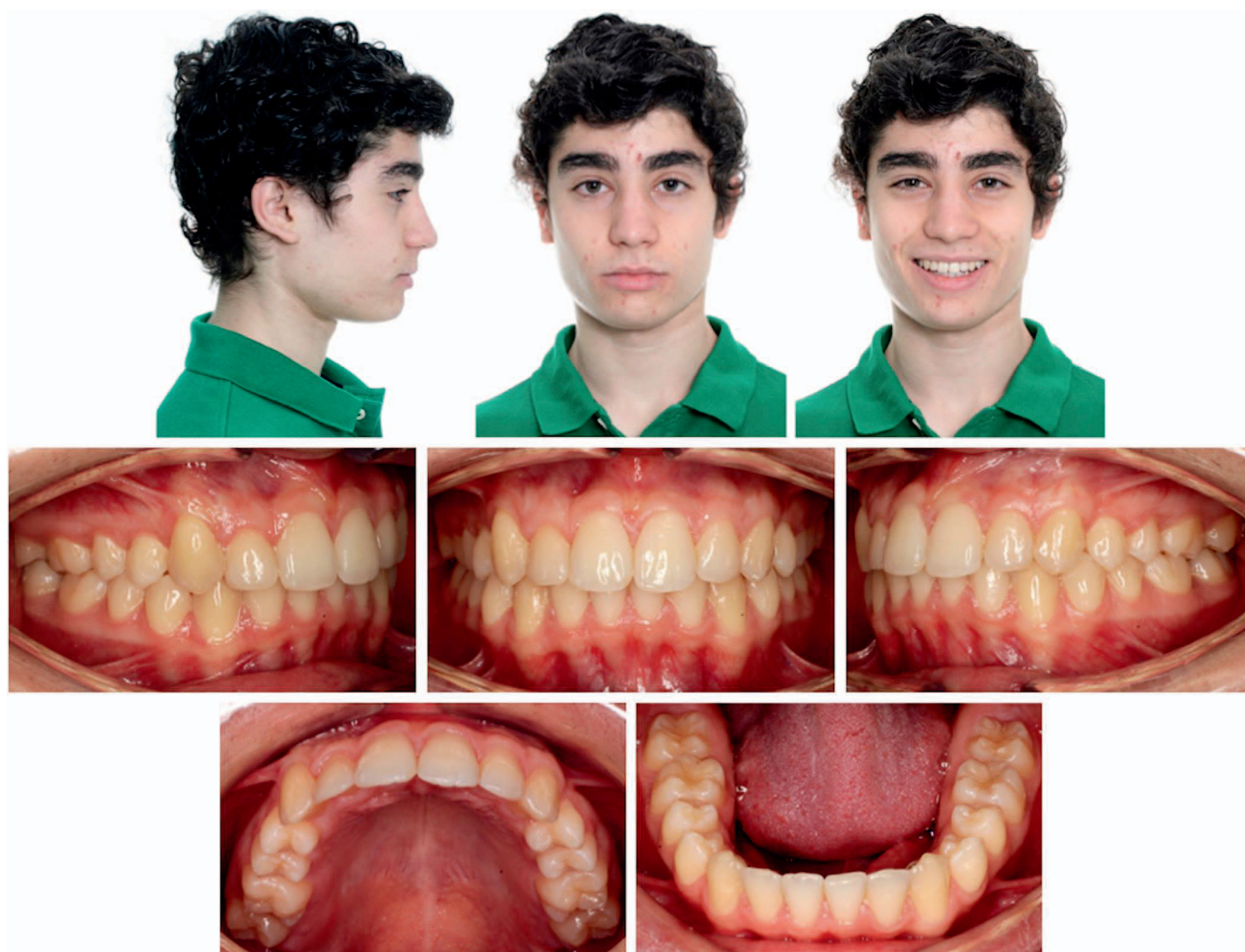
## CONCLUSIONS

- In this case report, bilateral transposition diagnosed

with CBCT was orthodontically corrected, achieving optimal results.

- On the right side where a complete Mx.C.1P transposition was observed, the traction was mesial and upward in order to move the canine into a more apical position with a wider dentoalveolar process for easier crown interchange, attempting to minimize the roots' spatial relationship conflict and periodontal problems.
- Noninvolvement of the erupted adjacent tooth during the initial months of treatment helped to minimize the risk of root resorption.
- The posttreatment records demonstrated that the treatment objectives were achieved.





**Figure 8.** Two-year posttreatment facial and intraoral photographs.

## REFERENCES

1. Thoma KH, Goldman HM. *Oral Pathology*. 5th ed. St. Louis, Mo: CV Mosby; 1960.
2. Pindborg JJ. *Pathology of the Dental Hard Tissues*. Philadelphia, Penn: Saunders; 1970.
3. Peck L, Peck S, Attia Y. Maxillary canine-first premolar transposition, associated dental anomalies and genetic basis. *Angle Orthod*. 1993;63:99–109.
4. Shapira Y, Kuflinec MM. Tooth transpositions—a review of the literature and treatment considerations. *Angle Orthod*. 1989;59:271–276.
5. Joshi MR, Bhatt NA. Canine transposition. *Oral Surg Oral Med Oral Pathol*. 1971;31:49–54.
6. Shapira Y, Kuflinec MM. A unique treatment approach for maxillary canine-lateral incisor transposition. *Am J Orthod Dentofacial Orthop*. 2001;119:540–545.
7. Weeks EC, Power SM. The presentations and management of transposed teeth. *Br Dent J*. 1996;181:421–424.
8. Peck S, Peck L. Classification of maxillary tooth transpositions. *Am J Orthod Dentofacial Orthop*. 1995;107:505–517.
9. Chattopadhyay A, Srinivas K. Transposition of teeth and genetic etiology. *Angle Orthod*. 1996;66:147–152.
10. Laptook T, Silling G. Canine transposition—approaches to treatment. *J Am Dent Assoc*. 1983;107:746–748.
11. Gholston L, Williams P. Bilateral transposition of maxillary canines and lateral incisors: a rare condition. *ASDC J Dent Child*. 1983;51:58–63.
12. Shapira Y, Kuflinec MM. Maxillary tooth transpositions: characteristic features and accompanying dental anomalies. *Am J Orthod Dentofacial Orthop*. 2001;119:127–134.
13. Jacoby H. The etiology of maxillary canine impactions. *Am J Orthod Dentofacial Orthop*. 1983;84:125–132.
14. Ciarlantini R, Melsen B. Maxillary tooth transposition: correct or accept? *Am J Orthod Dentofacial Orthop*. 2007;132:385–394.
15. Thilander B, Myrberg N. The prevalence of malocclusion in Swedish schoolchildren. *Eur J Oral Sci*. 1973;81:12–20.
16. Sandham A, Harvie H. Ectopic eruption of the maxillary canine resulting in transposition with adjacent teeth. *Tandlaegebladet*. 1985;89:9–11.
17. Plunkett DJ, Dysart PS, Kardos TB, Herbison GP. A study of transposed canines in a sample of orthodontic patients. *Br J Orthod*. 1998;25:203–208.

18. Shapira Y, Kuftinec MM, Stom D. Maxillary canine-lateral incisor transposition—orthodontic management. *Am J Orthod Dentofacial Orthop*. 1989;95:439–444.
19. Ely NJ, Sherriff M, Cobourne MT. Dental transposition as a disorder of genetic origin. *Eur J Orthod*. 2006;28:145–151.
20. Caplan D. Transposition of the maxillary canine and the lateral incisor. *Dent Practitioner and Dental Record*. 1972;22:307.
21. Lee MY, Park JH, Jung JG, Chae JM. Forced eruption of a palatally impacted and transposed canine with a temporary skeletal anchorage device. *Am J Orthod Dentofacial Orthop*. 2017;151:1148–1158.
22. Peck S, Peck L, Kataja M. Mandibular lateral incisor-canine transposition, concomitant dental anomalies, and genetic control. *Angle Orthod*. 1998;68:455–466.
23. Lorente T, Lorente C, Murray PG, Lorente P. Surgical and orthodontic management of maxillary canine-lateral incisor transpositions. *Am J Orthod Dentofacial Orthop*. 2016;150:876–885.
24. Laino A, Cacciafesta V, Martina R. Treatment of tooth impaction and transposition with a segmented-arch technique. *J Clin Orthod*. 2001;35:79–86.
25. Iwasaki LR, Covell DA Jr, Frazier-Bowers SA, Kapila S, Huja SS, Nickel JC. Personalized and precision orthodontic therapy. *Orthod Craniofac Res*. 2015;18(suppl 1):1–7.
26. Nishimura K, Nakao K, Aoki T, Fuyamada M, Saito K, Goto S. Orthodontic correction of a transposed maxillary canine and first premolar in the permanent dentition. *Am J Orthod Dentofacial Orthop*. 2012;142:524–533.
27. Liaw J, Lin J, Huang G. The applications of TADs in canine transpositions. *Semin Orthod*. 2018;24:155–190.
28. Hsu YL, Chang CH, Roberts WE. Canine-lateral incisor transposition: controlling root resorption with a bone-anchored T-loop retraction. *Am J Orthod Dentofacial Orthop*. 2016;150:1039–1050.
29. Becker A, Chaushu S. Long-term follow-up of severely resorbed maxillary incisors after resolution of an etiologically associated impacted canine. *Am J Orthod Dentofacial Orthop*. 2005;127:650–654.