

## Case Report

# Bone-anchored maxillary protraction long-term outcomes in UCLP:

## A case report

Daniela Garib<sup>a</sup>; Fernando Pugliese<sup>b</sup>; Renata Mayumi Kato<sup>c</sup>; Renato Faco<sup>d</sup>; Marilia Yatabe<sup>e</sup>; Hilde Timmerman<sup>f</sup>; Hugo De Clerck<sup>g</sup>

### ABSTRACT

This case report presents a 12-year-old boy with unilateral complete cleft lip and palate and severe maxillary retrusion treated with bone-anchored maxillary protraction (BAMP) therapy followed by fixed appliances. The follow-up period extended until the end of growth. Initially, the patient demonstrated a Goslon 4 interarch relationship with an overjet of  $-3.5$  mm and a Wits appraisal of  $-7.9$  mm. Six months after the secondary alveolar bone graft, Bollard miniplates were fixed bilaterally at the infrazygomatic region in the maxilla and between the canines and lateral incisors in the mandible. Class III elastics were used bilaterally full time for 12 months. After treatment, the overjet increased 5.9 mm. Significant maxillary advancement (SNA  $+3.2^\circ$ ) and skeletal convexity improvement (NA-APO  $+12.4^\circ$ ) were observed. Retrusion of the anteroposterior position of the mandible was observed (SNB  $-2.1^\circ$ ). Comprehensive orthodontic treatment was performed after BAMP therapy with nighttime bone-anchored Class III elastics as active retention until the end of growth. Occlusion and facial esthetics were satisfactory at the end of orthodontic treatment and growth. Le Fort I surgery for maxillary advancement was not required. BAMP therapy demonstrated an adequate orthopedic outcome, preventing the need for orthognathic surgery in unilateral complete cleft lip and palate. (*Angle Orthod.* 2020;90:734–741.)

**KEY WORDS:** Cleft lip; Cleft palate; Orthodontics

<sup>a</sup> Associate Professor, Department of Orthodontics, Bauru Dental School and Hospital for Rehabilitation of Craniofacial Anomalies, University of São Paulo, Bauru, SP, Brazil.

<sup>b</sup> Visiting Professor, Department of Orthodontics, School of Dental Medicine, Case Western Reserve University, Cleveland, Ohio, USA.

<sup>c</sup> MS student, Department of Orthodontics, Hospital for Rehabilitation of Craniofacial Anomalies, University of São Paulo, Bauru, SP, Brazil.

<sup>d</sup> Maxillofacial Surgeon, Department of Maxillofacial Surgery, Hospital for Rehabilitation of Craniofacial Anomalies, University of São Paulo, Bauru, SP, Brazil.

<sup>e</sup> Clinical Assistant Professor, Department of Orthodontic and Pediatric Dentistry, University of Michigan, Ann Arbor, Mich, USA.

<sup>f</sup> Private practice, Brussels, Belgium.

<sup>g</sup> Professor, Department of Orthodontics, University of North Carolina, Chapel Hill, NC, USA.

Corresponding author: Dr Daniela Garib, Department of Orthodontics, Bauru Dental School and Hospital for Rehabilitation of Craniofacial Anomalies, University of São Paulo, Alameda Octávio Pinheiro Brisolla 9-75, Bauru, SP 17012-901, Brazil (e-mail: dgarib@usp.br)

Accepted: May 2020. Submitted: December 2019.

Published Online: June 25, 2020

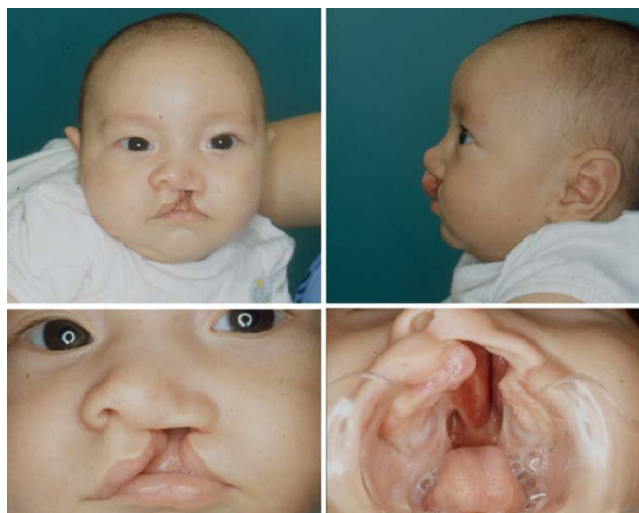© 2020 by The EH Angle Education and Research Foundation, Inc.

### INTRODUCTION

Patients with unilateral complete cleft lip and palate (UCLP) often present with maxillary deficiency as a side effect of primary surgeries, demonstrating esthetic and functional impairment.<sup>1</sup> The treatment protocol for moderate to severe maxillary deficiencies consists of orthognathic surgery with maxillary advancement at the end of the growth period.<sup>2</sup> The disadvantage of the current protocol is that patients with UCLP usually go through childhood and adolescence displaying facial dysmorphology.

Facemask therapy achieves limited orthopedic effects relative to the severity of maxillary deficiency in patients with UCLP.<sup>3–5</sup> Side effects such as molar mesialization and maxillary incisor proclination are also expected.<sup>6</sup> Additionally, facemask therapy can be unstable in patients with cleft lip and palate since the etiologic factor of maxillary deficiency is soft tissue tension of the repaired lip and palate, which remains until the end of growth.<sup>7–9</sup> Finally, the facemask consists of an extraoral device, and cooperation depends on patient/family acceptance.

Recently, miniplate bone anchors have been used with a potential for facial improvement before skeletal



**Figure 1.** Extraoral and intraoral photographs before lip and palate repair.

maturity in UCLP.<sup>10–12</sup> Bone-anchored maxillary protraction (BAMP) therapy showed significant maxillary advancement, gonial angle closure, ramus posterior displacement, and restriction of chin protrusion.<sup>11,12</sup> However, long-term stability of BAMP therapy in UCLP remains unknown. In this case report we describe a 12.4-year old male patient with UCLP and a severe

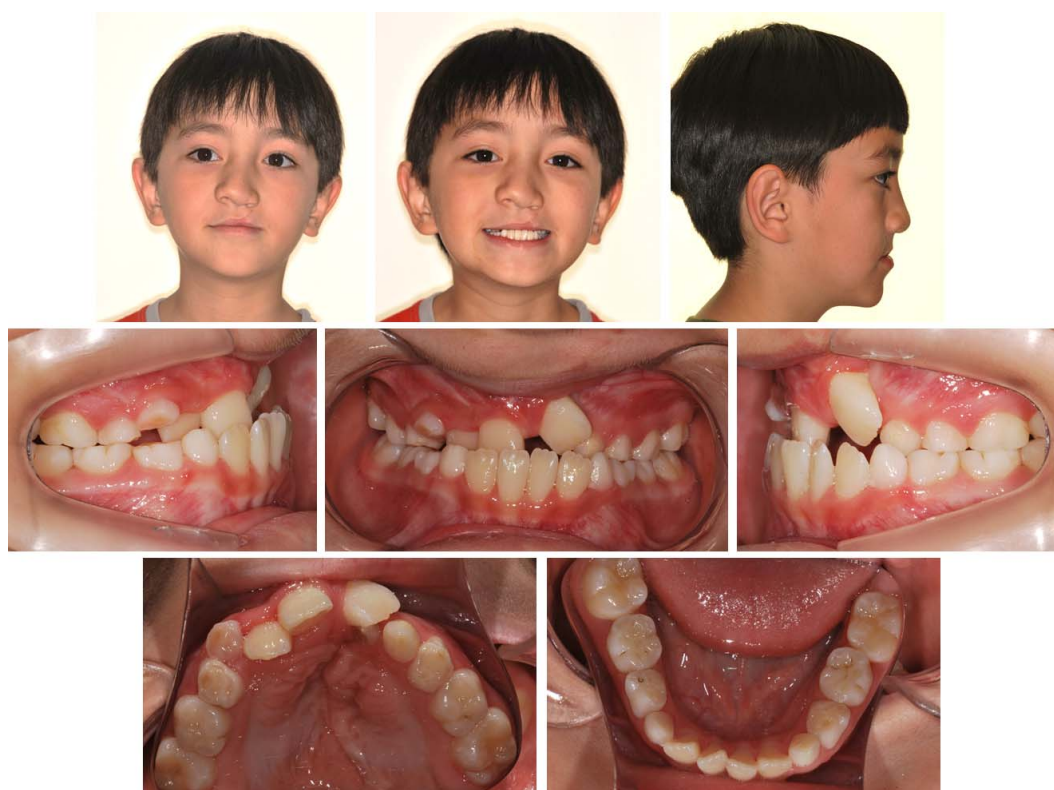maxillary deficiency treated with BAMP therapy and followed until the end of growth (17.6 years).

## CASE REPORT

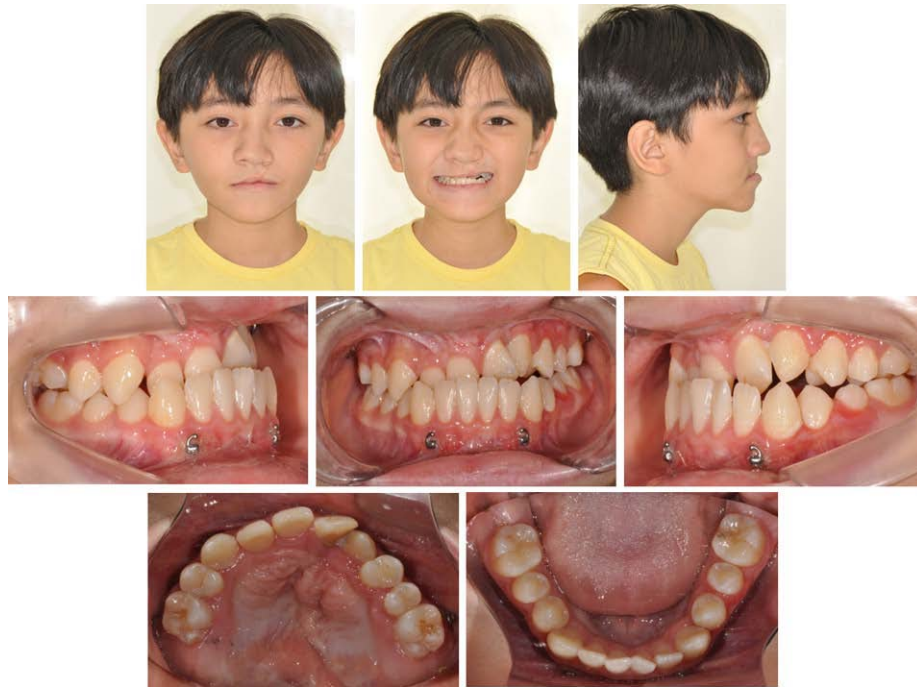### Etiology and Diagnosis

A 12.4-year-old male patient with left UCLP from the Hospital for Rehabilitation of Craniofacial Anomalies, University of São Paulo, Brazil, was selected for BAMP therapy. His medical history included lip repair performed at 3 months of age using the Spina and McComb techniques for nasal deformity correction and a palate repair at 9 months of age using the Furlow technique associated with the Hans-Pichler technique (Figure 1). A secondary surgery was performed at 2 years of age for palatal fistula revision. At 9 years of age, pre-bone graft orthodontic treatment was initiated (Figure 2). Rapid maxillary expansion was performed before alveolar bone grafting using a fan-shaped expander. The secondary alveolar bone graft was performed when the patient was 11 years 6 months old with rh-BMP2 (Infuse Bone Graft, Medtronic Sofamor Danek, Memphis, Tenn).

Before BAMP therapy, the patient had a concave facial profile due to severe maxillary deficiency and a hypodivergent growth pattern (Figure 3). The mandible was well positioned anteroposteriorly. Intraoral analy-



**Figure 2.** Photographs before orthodontic treatment at 9 years of age.



**Figure 3.** Extraoral and intraoral photographs before BAMP therapy at 12 years of age. Midface retrusion can be observed. The mandible was well positioned with an adequate mentolabial sulcus. The interarch anteroposterior relationship was Goslon Index 4. The posterior crossbite had been previously corrected right before the secondary alveolar bone graft procedure performed when the patient was 11 years 6 months old.

sis revealed a Goslon Index 4 with an overjet of  $-3.5$  mm in the permanent dentition (Figure 4). The panoramic radiograph showed agenesis of the maxillary right second premolar and the maxillary left lateral incisor (Figure 4). Cephalometric evaluation revealed severe maxillary retrusion ( $SNA\ 70.3^\circ$ ), a relatively well-positioned mandible ( $SNB\ 74.5^\circ$ ), and a Wits appraisal of  $-7.9$  mm (Table 1). The etiology of maxillary deficiency in unilateral cleft lip and palate is predominantly environmental due to primary lip and palate repair performed in early childhood.<sup>8</sup>

### Treatment Alternatives

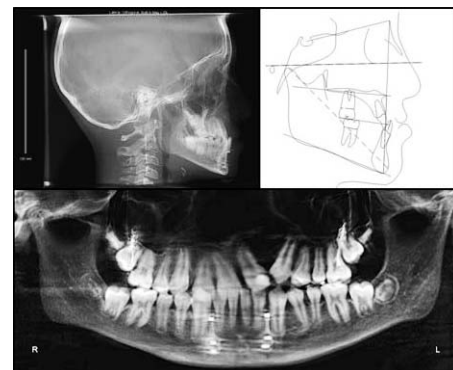
Treatment alternatives were orthopedic maxillary protraction with bone-anchored Class III elastics or waiting until the end of growth for Le Fort I maxillary advancement. The treatment option chosen was BAMP therapy with the aim of correcting the anterior crossbite and anticipating facial esthetic improvement.

### Treatment Progress

Under general anesthesia, two Bollard miniplates were installed bilaterally in the infrazygomatic ridge of the maxilla above the permanent maxillary first molars. Two miniplates were also inserted bilaterally in the mandibular anterior region between the permanent canine and lateral incisor. Three monocortical screws were used to fix the maxillary miniplates while two

screws were used for the mandibular miniplates. Three weeks after miniplate insertion, full-time Class III intermaxillary elastic use was initiated. The force was 150 g per side in the first month (5/16" elastics), reaching 250 g per side in the third month of therapy (1/4" elastics). Elastics were to be changed twice a day: morning and night.

A fixed transpalatal arch was used during the whole active therapy phase as a maxillary expansion retainer. A removable biteplate with proclination springs was used in the maxillary arch to avoid occlusal interference during crossbite correction. The springs were slightly activated only when the permanent incisors reached an edge-to-edge relationship. The patient and family were very cooperative with the therapy.



**Figure 4.** Initial panoramic and cephalometric radiographs.



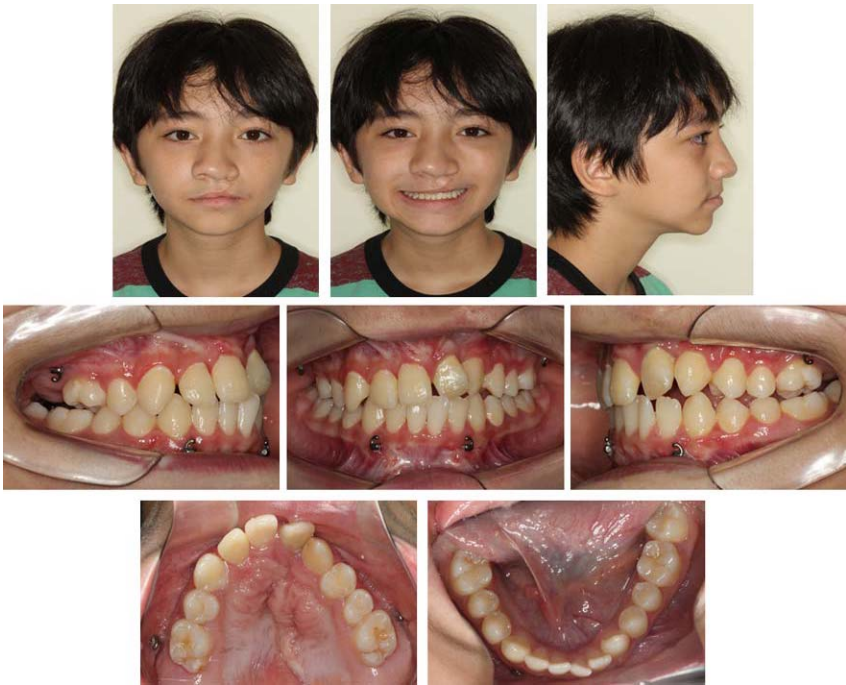**Table 1.** Cephalometric Values<sup>a</sup>

Variables	Before BAMP Therapy	After BAMP Therapy	After Fixed Appliance Therapy
SNA	70.3°	73.5°	72.6°
SNB	74.5°	72.4°	72.7°
ANB	-4.2°	1.1°	-0.1°
SNGoGn	31.9°	34.6°	28°
FMA	21.8°	24.1°	20.4°
U1 - Palatal Plane	110.5°	112.2°	117.1°
IMPA	85.9°	93.9°	94.1°
Nasolabial angle	102.9°	117.3°	94.9°
Convexity (NA-APo)	-11.9°	0.5°	-4.9°
Wits appraisal	-7.9 mm	-0.4 mm	-1.3 mm

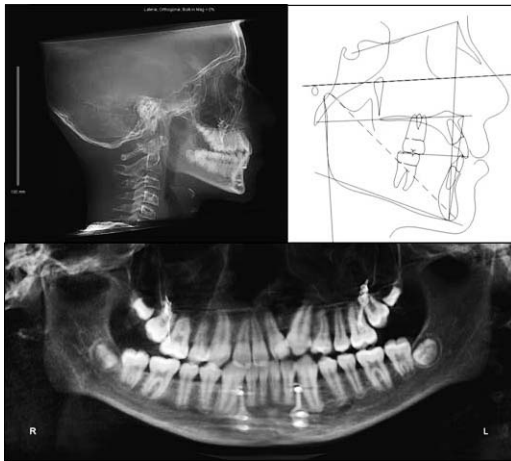
<sup>a</sup> BAMP indicates bone-anchored maxillary protraction.

After 12 months of treatment, the anterior crossbite was corrected (Figures 5 through 7). Comprehensive orthodontic treatment was initiated after BAMP therapy when the patient was 13 years old. The treatment plan included correction of the maxillary midline deviation, maintaining the left maxillary canine to replace the missing maxillary left lateral incisor. During fixed appliance treatment, the right maxillary miniplate was used as direct anchorage for maxillary midline correction (Figure 8). Nighttime bone-anchored Class III elastics were recommended as active retention during comprehensive orthodontic treatment until the end of growth (Figure 9). Debonding was accomplished at 17 years of age. A hand and wrist radiograph showed the end of active growth. Surgery for miniplate removal was scheduled.

Cone beam computed tomography (CBCT) was performed immediately before BAMP therapy (T1) for planning the placement of miniplates and evaluating the alveolar bone graft procedure. A second CBCT scan was taken after BAMP therapy (T2) and used for planning the comprehensive orthodontic treatment. The time between T1 and T2 CBCT exams was 14 months. After debonding, a conventional two-dimensional cephalometric radiograph was taken instead of a CBCT scan as a final posttreatment record in order to follow the ALARA (as low as reasonably achievable) principle. The retention protocol included a Hawley appliance for 2 years and a fixed permanent mandibular 3×3 retainer. A velopharyngeal flap using the Sommerlad technique was performed when the patient was 16 years old to improve speech.



**Figure 5.** Photographs after BAMP therapy. Facial profile improvement was achieved with the midface advancement. The anterior crossbite was corrected.

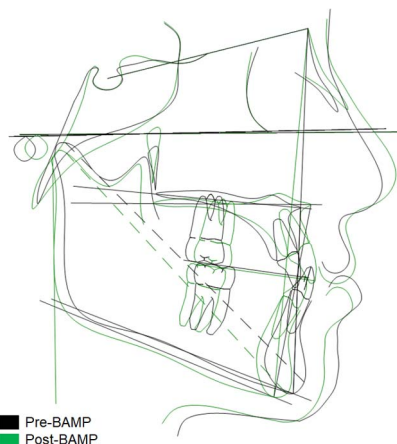


**Figure 6.** Panoramic and cephalometric radiographs after BAMP therapy.

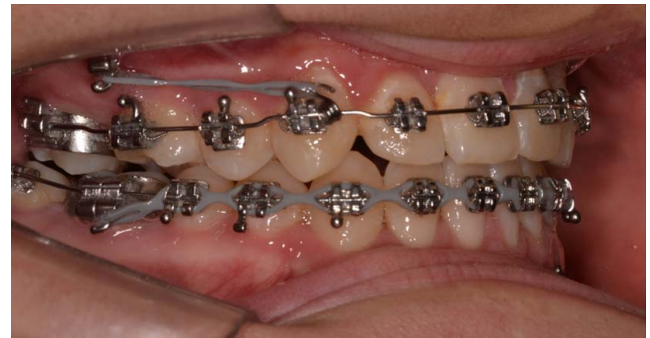### Treatment Results

During the orthopedic intervention with BAMP therapy, significant improvement of the facial profile was observed (Figure 5). The anterior crossbite was corrected, and an adequate change in the interarch sagittal relationship was observed (Figure 5). Cephalometric analysis (Figure 6; Table 1) demonstrated that the SNA angle increased  $3.2^\circ$ , the SNB angle decreased  $2.1^\circ$ , and facial convexity increased  $12.4^\circ$ . The mandibular plane inclination increased ( $+2.3^\circ$ ) after BAMP therapy (Table 1). A slight counterclockwise rotation of the maxilla was observed (Figure 7). Labial inclination of the maxillary ( $+1.7^\circ$ ) and mandibular ( $+8^\circ$ ) incisors was observed (Table 1). Figure 7 shows the cephalometric superimposition before and after BAMP therapy.

During comprehensive orthodontic treatment, the facial changes observed during BAMP therapy remained stable (Figure 10). Cephalometric changes



**Figure 7.** Conventional cephalometric superimposition of tracings before and after BAMP therapy (SN line centered on S).

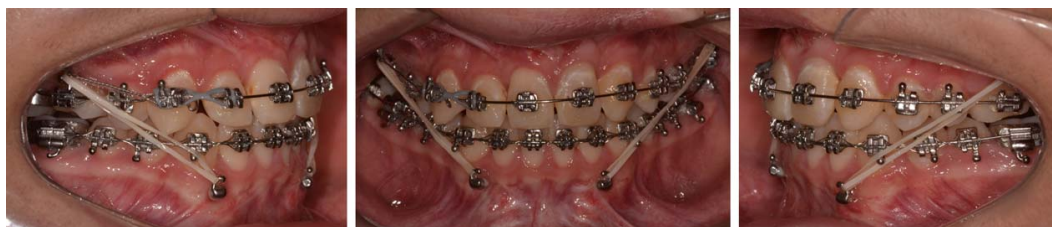

**Figure 8.** Comprehensive orthodontic treatment using miniplates as anchorage for maxillary midline correction.

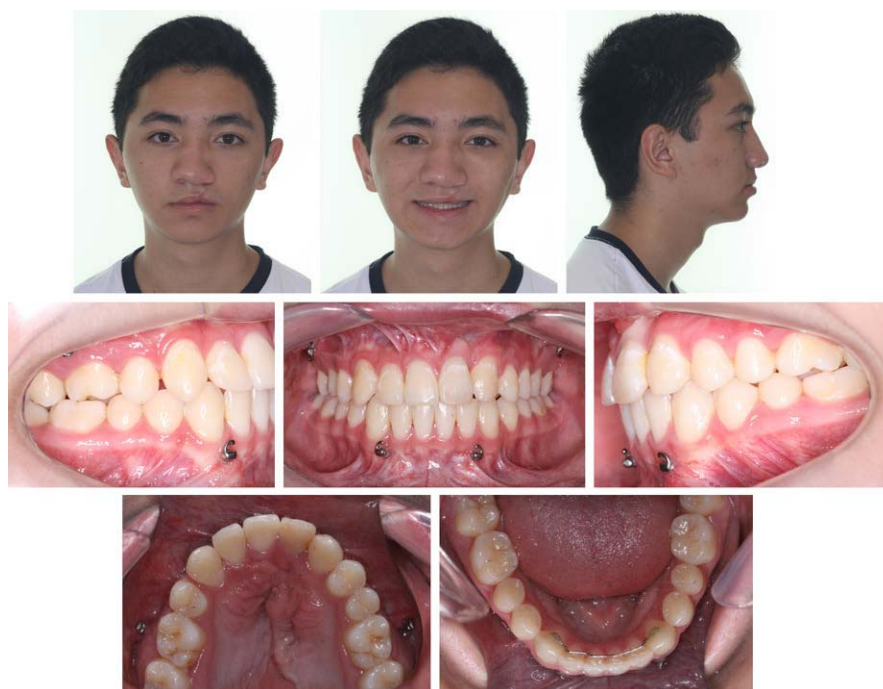after BAMP and fixed appliance treatment showed slight maxillary retrusion during BAMP therapy retention ( $-0.9^\circ$ ), an increase in SNB ( $+0.3^\circ$ ), and a decrease in ANB ( $-1.2^\circ$ ) (Figures 11 and 12). The maxillary midline was improved, and positive overjet was maintained. The molar relationship was Class II bilaterally at the end of treatment. The canine relationship was Class I on the right side and Class II on the left side (Figure 10). The long-term retention protocol included a Hawley appliance and a fixed  $3 \times 3$  mandibular retainer. Nighttime Class III elastics were recommended as active retention until the end of growth (Figure 13).

### DISCUSSION

The maxilla was significantly protracted after BAMP therapy, similar to results in previous reports.<sup>10–12</sup> Previous studies on facemask therapy in patients with cleft lip and palate during the mixed dentition demonstrated an SNA increase ranging from  $0.65^\circ$  to  $1.85^\circ$ .<sup>5,7,13,14</sup> Considering that this patient was in the permanent dentition, a very limited orthopedic effect could be expected if facemask therapy had been used. Maxillary protraction achieved by BAMP therapy in the present case was considered clinically significant as a substantial positive impact on the midface and upper lip was observed. On the other hand, BAMP therapy could not replace distraction osteogenesis. BAMP therapy produced a mean maxillary advancement of 2.5 mm in complete UCLP.<sup>12</sup> In contrast, distraction osteogenesis has been shown to achieve a mean maxillary advancement between 5 and 15 mm.<sup>15,16</sup> A slight counterclockwise rotation of the maxilla was observed in agreement with previous reports.<sup>17</sup> The possible explanation is that the protraction force was applied below the maxillary center of resistance. However, these results should be interpreted with caution because patients with cleft lip and palate have an atypical posterior nasal spine due to the cleft palate.



**Figure 9.** Nighttime Class III elastics were used as active retention during comprehensive orthodontic treatment until the end of growth.



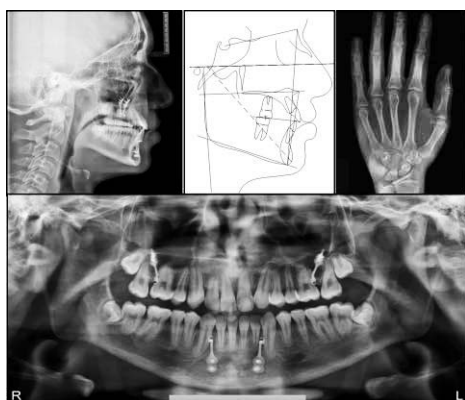
**Figure 10.** Final clinical photographs.

The mandibular sagittal position (SNB) showed retrusion after BAMP therapy. These results were probably related to gonial angle closure<sup>18</sup> and slight backward glenoid fossa remodeling.<sup>18–20</sup> The Wits appraisal showed an increase of 7.5 mm, and the

ANB angle increased by 5.3°. These results were considered adequate in the permanent dentition and with the presence of scar fibrosis and tension inherent to cleft lip and palate rehabilitation.<sup>9</sup>

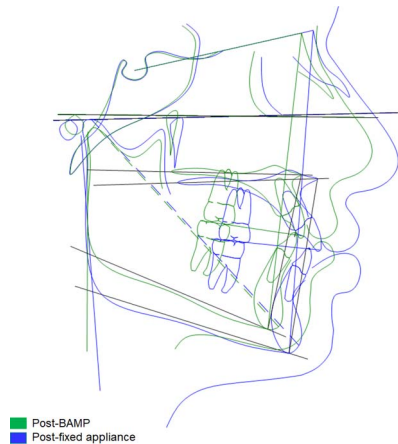The patient displayed a Goslon Index score of 4 before BAMP therapy, which is considered to be a severe interarch relationship with poor prognosis for orthodontic treatment without Le Fort I osteotomy.<sup>21</sup> However, excellent patient and family cooperation and discipline was very important for achieving these treatment outcomes. Miniplates were well accepted and caused no physical or psychological discomfort to the patient, in agreement with previous findings from Cornelis et al.<sup>22</sup> The patient's horizontal growth pattern also seemed to be a positive factor influencing the adequate outcome, although clinical studies should be performed to confirm this hypothesis.

Outcome stability cannot be expected in UCLP<sup>7</sup> because the etiologic factors of maxillary deficiency—scar fibrosis and soft tissue tension—cannot be removed.<sup>9</sup> For this reason, nighttime use of bone-



**Figure 11.** Final panoramic, cephalometric and hand-wrist radiographs.





**Figure 12.** Superimposition of cephalometric tracings after BAMP and fixed appliance therapy.

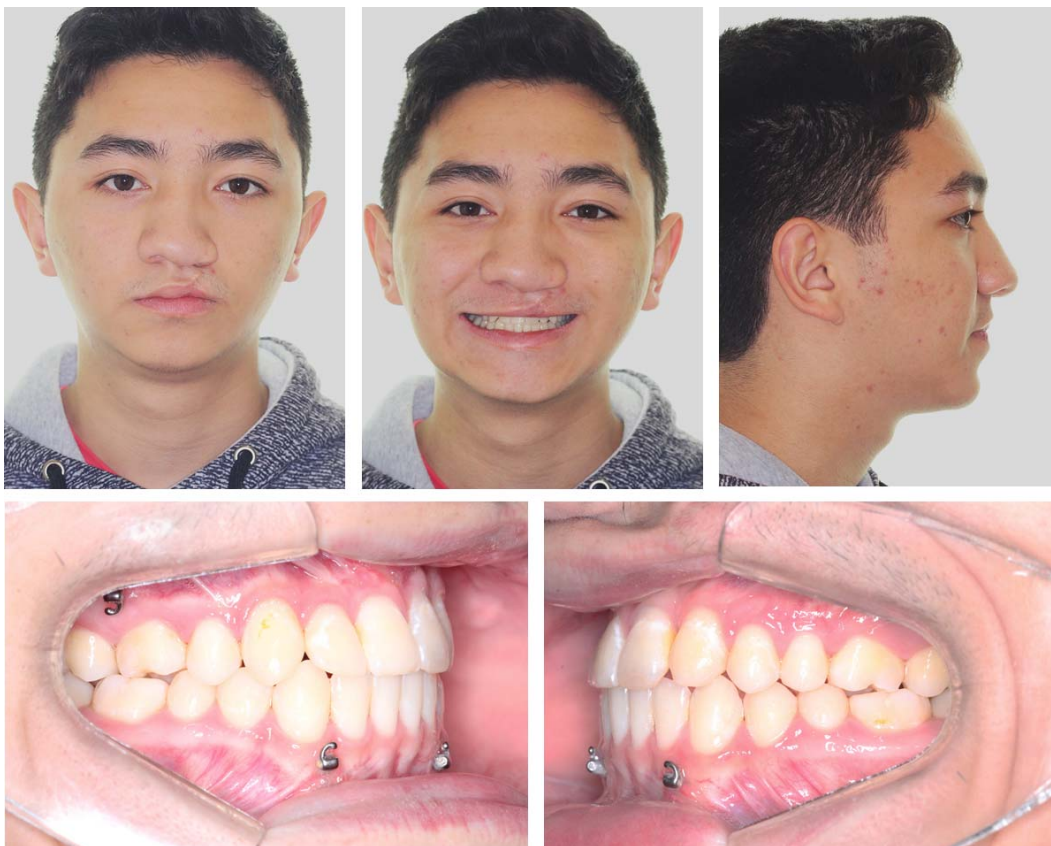anchored Class III intermaxillary elastics was maintained as active retention. Long-term Class III elastics as retention did not produce dental side effects. Miniplates can also be used as anchorage for tooth movement during comprehensive orthodontic treatment. In this case, the maxillary midline was improved with mechanics anchored by use of the miniplates. Potential problems in the long-term maintenance of

miniplates could be a decrease in patient cooperation and late instability of the miniplates, both of which were not observed in this case.

Comprehensive orthodontic treatment was accomplished in 42 months. The missing maxillary left lateral incisor was replaced by space closure and maxillary canine substitution. Adequate alveolar bone morphology is expected when the maxillary canine is moved toward the grafted alveolar cleft.<sup>23,24</sup> At debonding, the patient was at the end of growth. Le Fort I osteotomy and maxillary advancement was prevented. Improvement of facial esthetics was anticipated, allowing the patient to go through the delicate period of adolescence with a better appearance. BAMP therapy seems promising in improving quality of life and preventing bullying during adolescence in patients with UCLP. Future studies with larger samples should be performed to assess the long-term stability of BAMP therapy and the potential for avoiding orthognathic surgery in patients with UCLP and maxillary deficiencies.

## CONCLUSIONS

- Significant maxillary advancement was obtained



**Figure 13.** Facial and intraoral photographs 6 months after debonding. While using retention, the patient was awaiting the surgery for miniplate removal.

using BAMP therapy in an adolescent patient with complete UCLP. Patient and family compliance with the use of Class III elastics was high. Le Fort I osteotomy with maxillary advancement was avoided.

## REFERENCES

- Semb G. A study of facial growth in patients with unilateral cleft lip and palate treated by the Oslo CLP Team. *Cleft Palate Craniofac J*. 1991;28:1–21.
- Freitas JA, das Neves LT, de Almeida AL, et al. Rehabilitative treatment of cleft lip and palate: experience of the Hospital for Rehabilitation of Craniofacial Anomalies/USP (HRAC/USP) part 3: Oral and Maxillofacial Surgery. *J Appl Oral Sci*. 2012;20:673–679.
- Friede H, Lennartsson B. Forward traction of the maxilla in cleft lip and palate patients. *Eur J Orthod*. 1981;3:21–39.
- Ranta R. Forward traction of the maxilla with cleft lip and palate in mixed and permanent dentitions. *J Craniomaxillofac Surg*. 1989;17(suppl 1):20–22.
- Buschang PH, Porter C, Genecov E, Genecov D, Saylor KE. Face mask therapy of preadolescents with unilateral cleft lip and palate. *Angle Orthod*. 1994;64:145–150.
- Tindlund RS, Rygh P. Maxillary protraction: different effects on facial morphology in unilateral and bilateral cleft lip and palate patients. *Cleft Palate Craniofac J*. 1993;30:208–221.
- Mølsted K, Dahl E. Face mask therapy in children with cleft lip and palate. *Eur J Orthod*. 1987;9:211–215.
- Silva Filho OG, Ramos AL, Abdo RC. The influence of unilateral cleft lip and palate on maxillary dental arch morphology. *Angle Orthod*. 1992;62:283–290.
- Silva Filho OG, Valladares Neto J, Capelloza Filho L, de Souza Freitas JA. Influence of lip repair on craniofacial morphology of patients with complete bilateral cleft lip and palate. *Cleft Palate Craniofac J*. 2003;40:144–153.
- Garib D, Yatabe M, de Souza Faco RA, et al. Bone-anchored maxillary protraction in a patient with complete cleft lip and palate: a case report. *Am J Orthod Dentofacial Orthop*. 2018;153:290–297.
- Faco R, Yatabe M, Cevidanes LHS, Timmerman H, De Clerck HJ, Garib D. Bone-anchored maxillary protraction in unilateral cleft lip and palate: a cephalometric appraisal. *Eur J Orthod*. 2019;41:537–543. doi: 10.1093/ejo/cjz005.
- Yatabe M, Garib DG, Faco RAS, et al. Bone-anchored maxillary protraction therapy in patients with unilateral complete cleft lip and palate: 3-dimensional assessment of maxillary effects. *Am J Orthod Dentofacial Orthop*. 2017;152:327–335.
- Chen KF, So LL. Sagittal skeletal and dental changes of reverse headgear treatment in Chinese boys with complete unilateral cleft lip and palate. *Angle Orthod*. 1996;66:363–372.
- So LL. Effects of reverse headgear treatment on sagittal correction in girls born with unilateral complete cleft lip and cleft palate—skeletal and dental changes. *Am J Orthod Dentofacial Orthop*. 1996;109:140–147.
- Saltaji H, Major MP, Altalibi M, Youssef M, Flores-Mir C. Long-term skeletal stability after maxillary advancement with distraction osteogenesis in cleft lip and palate patients. *Angle Orthod*. 2012;82:1115–1122.
- Kloukos D, Fudalej P, Sequeira-Byron P, Katsaros C. Maxillary distraction osteogenesis versus orthognathic surgery for cleft lip and palate patients. *Cochrane Database Syst Rev*. 2016;9:CD010403. doi: 10.1002/14651858.CD010403.pub3.
- De Clerck HJ, Cornelis MA, Cevidanes LH, Heymann GC, Tulloch CJ. Orthopedic traction of the maxilla with miniplates: a new perspective for treatment of midface deficiency. *J Oral Maxillofac Surg*. 2009;67:2123–2129.
- De Clerck H, Nguyen T, de Paula LK, Cevidanes L. Three-dimensional assessment of mandibular and glenoid fossa changes after bone-anchored Class III intermaxillary traction. *Am J Orthod Dentofacial Orthop*. 2012;142:25–31.
- Cevidanes L, Baccetti T, Franchi L, McNamara JA Jr, De Clerck H. Comparison of two protocols for maxillary protraction: bone anchors versus face mask with rapid maxillary expansion. *Angle Orthod*. 2010;80:799–806.
- Nguyen T, Cevidanes L, Paniagua B, Zhu H, Koerich L, De Clerck H. Use of shape correspondence analysis to quantify skeletal changes associated with bone-anchored Class III correction. *Angle Orthod*. 2014;84:329–336.
- Mars M, Plint DA, Houston WJ, Bergland O, Semb G. The Goslon Yardstick: a new system of assessing dental arch relationships in children with unilateral clefts of the lip and palate. *Cleft Palate J*. 1987;24:314–322.
- Cornelis MA, Scheffler NR, Nyssen-Behets C, De Clerck HJ, Tulloch JF. Patients' and orthodontists' perceptions of miniplates used for temporary skeletal anchorage: a prospective study. *Am J Orthod Dentofacial Orthop*. 2008;133:18–24.
- Yatabe MS, Ozawa TO, Janson G, Faco RA, Garib DG. Are there bone dehiscences in maxillary canines orthodontically moved into the grafted alveolar cleft? *Am J Orthod Dentofacial Orthop*. 2015;147:205–213.
- Garib D, Massaro C, Yatabe M, Janson G, Lauris JRP. Mesial and distal alveolar bone morphology in maxillary canines moved into the grafted alveolar cleft: computed tomography evaluation. *Am J Orthod Dentofacial Orthop*. 2017;151:869–877.