

Evaluation of treatment outcome assessment using the American Board of Orthodontics Objective Grading System in subjects treated with lower incisor extraction with severe to moderate crowding

Inna Burnett^a; Vaibhav Gandhi^b; Loiy Alshami^a; Jay Patel^a; Janakiraman Nandakumar^c

ABSTRACT

Objectives: To assess case outcomes using the American Board of Orthodontics (ABO) Objective Grading System (OGS) in patients treated with lower incisor extraction.

Materials and Methods: Discrepancy indices (DI) were used to stratify patients into mild, moderate, and complex categories and overjet, overbite, and buccal occlusion were examined. Nineteen subjects were included in the study, among which 52.6% were females.

Results: The average (SD) age was 28.5 (15.1) years, and the average (SD) DI was 15.2 (8.6) with an even distribution of mild, moderate, and complex cases. The mean post-treatment OGS was 31, with 52.6% of the patients achieving passing ABO clinical scores. 31.6% achieved normal post-treatment overjet. A total of 52.6% achieved normal post-treatment overbite, and 84.2% achieved normal post-treatment buccal occlusion.

Conclusions: An increase in overbite and overjet, and a decrease in buccal occlusion measurement, were found after lower incisor extraction treatment. The ABO-OGS scores obtained were high, indicating that they may not pass the ABO criteria established. (*Angle Orthod.* 2025;95:420–428.)

KEY WORDS: Orthodontic tooth movement; Treatment Outcome; ABO-OGS

INTRODUCTION

Anterior mandibular crowding is a common clinical finding encountered in orthodontics, often necessitating the decision to extract permanent teeth to resolve arch length discrepancies.^{1,2} In certain cases, the extraction of a mandibular incisor is considered the optimal treatment strategy. This approach is commonly indicated in cases of severe localized crowding in the lower anterior segment, particularly when accompanied by reduced overbite and overjet.

Mandibular incisor extraction is recommended when a tooth size discrepancy of 4.5 mm or more is present, which may result from either a deficiency in maxillary tooth mass or an excess in mandibular anterior tooth mass.^{3,4} This treatment modality is particularly suited for patients with skeletal Class I and mild skeletal Class III malocclusions, especially those with a slight tendency toward open bite or presenting with edge-to-edge anterior occlusion.⁵ When extracting a mandibular incisor, the lateral incisor is typically preferred due to its variable anatomy compared to the central incisor. Ultimately, the decision on which tooth to extract should prioritize the incisor most displaced from the natural arch and closest to the area of crowding.⁶

The extraction of a mandibular incisor offers several advantages over premolar extraction. First, it can shorten the overall treatment duration, particularly when crowding is confined to the anterior region. Second, because the intercanine width remains relatively stable after lower incisor extraction, the treatment tends to result in greater long-term stability. Last, the anteroposterior position of the mandibular incisors is less affected by this procedure. However, studies have indicated that this approach can result in maxillary tooth-size excess, and increased overjet.³

^a Graduate Student, Orthodontic Graduate Program, The Georgia School of Orthodontics, Atlanta, GA, USA.

^b Assistant Professor, Department of Growth and Development, University of Nebraska Medical Center College of Dentistry, Lincoln, Nebraska.

^c Associate Professor, Orthodontic Graduate Program, The Georgia School of Orthodontics, Atlanta, GA, USA.

Corresponding author: Dr Vaibhav Gandhi, Private Practice, 4 Earl Close Red Deer Alberta T4P 3G5 Canada (e-mail: drvaibhavgandhi88@gmail.com)

Accepted: March 30, 2025. Submitted: December 5, 2024.

Published Online: May 1, 2025

© 2025 by The EH Angle Education and Research Foundation, Inc.

Table 1. Patient Demographics

	All patients (N = 19)
Age	
Mean (SD)	28.5 (15.1)
Median [Min, Max]	27.0 [13.0, 67.0]
Sex	
F	10 (52.6%)
M	9 (47.4%)
Discrepancy Index (DI)	
Mean (SD)	15.2 (8.57)
Median [Min, Max]	11.0 [4.00, 29.0]
DI groups	
Mild (<11)	7 (36.8%)
Moderate (11–20)	6 (31.6%)
Complex (21–30)	6 (31.6%)

Evaluating orthodontic treatment outcomes can be challenging, and one widely used tool to assess treatment quality is the American Board of Orthodontics Objective Grading System (ABO-OGS). This system assesses eight parameters to evaluate the quality of the final treatment outcome. In the ABO clinical examination, an OGS score below 20 is considered passing. Scores between 21 and 29 are classified as indeterminate with passing or failing determined on a case-by-case basis by the examiners. A score above 30 is regarded as a failure in the ABO clinical examination.⁷

Previous studies have assessed the Objective Grading System (OGS) in the context of premolar extraction vs nonextraction treatments. However, no studies have specifically investigated the changes or quality of treatment outcomes using OGS in cases involving mandibular incisor extraction. Therefore, the objective of this retrospective study was to evaluate the treatment outcomes in patients treated with mandibular incisor extraction, using the ABO-OGS. The null hypothesis was that no significant or beneficial dental changes would be observed in key parameters, namely overjet, buccal occlusion, and overbite, in patients treated with lower incisor extraction. In contrast, the experimental hypothesis was that favorable dental outcomes,

including normalization of overjet, overbite, and buccal occlusion, would be achieved upon the completion of treatment in cases involving mandibular incisor extraction.

MATERIALS AND METHODS

This retrospective study was conducted using patient records from the Georgia School of Orthodontics, focusing on individuals who underwent orthodontic treatment involving lower incisor extraction. Inclusion criteria for case selection were: moderate crowding with Class I or mild Class III molar relationship, with minimal overjet and overbite. To be included, patients were required to have completed orthodontic treatment with lower incisor extraction and to have pretreatment and posttreatment digital scans captured using the iTero system. These scans were critical for assessing treatment outcomes and quality, and their availability was a prerequisite for inclusion in the study. A total of 19 subjects met the established inclusion criteria for this study.

The exclusion criteria were carefully defined to ensure the integrity and diagnostic value of the data. Patients were excluded if their iTero scans were of poor quality, such as those producing blurry or unclear images that were not of sufficient diagnostic accuracy. Additionally, individuals with severe craniofacial deformities, which could confound the results and outcomes of standard orthodontic treatment, were excluded. Subjects without complete sets of pretreatment and posttreatment iTero scans, as well as those who did not complete their orthodontic treatment, were also omitted from the analysis.

To ensure inter-rater reliability in the evaluation of the study models using the ABO-OGS, a comprehensive calibration process was conducted prior to data collection. The calibration process was designed to standardize the assessment techniques of the two examiners, specifically for key parameters such as overbite, overjet, buccal occlusion, and overall ABO-

Table 2. Pre- and Post-Treatment Data by Individual Raters

	Pretreatment		Posttreatment	
	Rater A (N = 19)	Rater B (N = 19)	Rater A (N = 19)	Rater B (N = 19)
Overbite (mm)				
Mean (SD)	2.87 (1.84)	2.82 (1.67)	3.03 (0.979)	3.00 (0.957)
Median [Min, Max]	2.40 [0, 7.40]	2.50 [0, 6.70]	3.00 [1.50, 4.50]	3.00 [1.50, 4.50]
Overjet (mm)				
Mean (SD)	2.97 (1.37)	3.03 (1.35)	3.71 (1.36)	3.68 (1.30)
Median [Min, Max]	2.90 [0.600, 6.30]	2.90 [0.500, 6.80]	4.00 [1.00, 5.50]	4.00 [1.50, 5.50]
Buccal Occlusion (mm)				
Mean (SD)	9.47 (3.98)	9.24 (4.03)	7.16 (3.48)	7.24 (3.25)
Median [Min, Max]	8.50 [3.50, 17.5]	9.00 [3.00, 18.0]	7.00 [1.50, 17.5]	7.00 [2.00, 17.0]

Table 3. Reliability Estimates and 95% CI Between Raters

Measurement	Time Point	
	Pre	Post
Overjet	0.963 (95% CI: 0.908–0.986)	0.989 (95% CI: 0.972–0.996)
Overbite	0.981 (95% CI: 0.953–0.993)	0.979 (95% CI: 0.947–0.992)
Buccal occlusion	0.992 (95% CI: 0.976–0.997)	0.985 (95% CI: 0.963–0.994)

OGS scoring. Both examiners independently measured and scored 100% of the study models, ensuring that data collection was thorough and unbiased. Acceptability of the measurements between the two raters was defined as a difference within 1 mm. If discrepancies in measurements exceeded 1 mm, the raters reviewed the cases together and discussed the discrepancies to resolve any errors in measurement. This collaborative approach helped to rectify inconsistencies and maintain the integrity of the scoring process. Additionally, intraclass correlation coefficient (ICC) was calculated to quantify the degree of agreement between the two raters.

The primary outcome variables in this study were overjet, overbite, and buccal occlusion, all of which are critical parameters in evaluating orthodontic treatment outcomes. Overjet, as defined by the ABO, refers to the horizontal distance between the facial surface of the most lingually positioned mandibular incisor and the incisal edge of the corresponding, more facially positioned maxillary incisor. This measurement is typically taken between the lateral or central incisors that display the greatest overjet, with a normal range of 1 to 3 mm.⁸ Similarly, overbite is assessed by measuring the vertical overlap between the incisal edges of the opposing anterior teeth (lateral or central incisors) that exhibit the greatest overbite. According to ABO standards, normal overbite falls within the range of 0 to 3 mm.⁸ Buccal occlusion, another critical variable, was evaluated to determine the alignment of the posterior teeth, aiming for an Angle Class I occlusion. Ideally, this involves the maxillary canine cusp tip aligning with, or being within 1 mm of, the embrasure between the mandibular canine and the adjacent premolar. The same alignment criteria apply to the buccal cusps of the maxillary premolars and molars, with a normal acceptable range of 0 to 1 mm per tooth or 0 to 10 mm for all maxillary posterior teeth.⁸

To ensure a comprehensive evaluation of treatment outcomes, the ABO-OGS was used.⁸ This system assesses several criteria from 3D printed dental casts, including alignment and rotations, marginal ridges, buccolingual inclination, overjet, occlusal contacts, occlusal relationships, interproximal contacts, and root angulation. By utilizing this grading system, the study

was able to quantify the quality of treatment outcomes objectively by the defined orthodontic parameters.

RESULTS

Table 1 details the patient demographics of the 19 eligible subjects. The mean age was 28.5 years and 52.6% of study subjects were female and 47.4% were male. The mean (SD) discrepancy index was 15.2 (8.6) with mild, moderate, and complex cases equally distributed among the 19 patients.

Two residents measured both pre- and post-treatment overbite, overjet, and buccal occlusion as shown in Table 2. The intraclass correlation coefficient (ICC) estimates and 95% confidence intervals for the measurements between the raters are shown in Table 3. An ICC >0.9 is considered excellent reliability. The ICC for pretreatment was 0.963 for overjet, 0.981 for overbite, and 0.992 for buccal occlusion. The post-treatment ICC was 0.989 for overjet, 0.979 for overbite, and 0.985 for buccal occlusion.

Table 4 summarizes ABO-OGS scoring, which was the index used for quality of finish in this study. ABO-OGS scores along with post-treatment overjet, overbite, and buccal occlusion are included in the table. The mean (SD) OGS was 31 (10.4) and 31.5 (9.89) from rater A and B, respectively. Overall, 10 (53%) and 8 (42%) cases achieved passing ABO scores of

Table 4. Summary of Findings of ABO-OGS by Rater^a

	Rater A (N = 19)	Rater B (N = 19)
OGS		
Mean (SD)	31.0 (10.4)	31.5 (9.86)
Median [Min, Max]	30.0 [14.0, 52.0]	31.0 [17.0, 47.0]
OGS group		
Not passing (>30)	9 (47.4%)	11 (57.9%)
Passing (30)	10 (52.6%)	8 (42.1%)
Overjet groups		
Not normal	13 (68.4%)	12 (63.2%)
Normal	6 (31.6%)	7 (36.8%)
Buccal occlusion groups		
Not normal	3 (15.8%)	1 (5.3%)
Normal	16 (84.2%)	18 (94.7%)
Overbite groups		
Not normal	9 (47.4%)	8 (42.1%)
Normal	10 (52.6%)	11 (57.9%)

^a ABO-OGS indicates American Board of Orthodontics Objective Grading System.

Table 5. Posttreatment Overjet by Rater and Discrepancy Index

	Mild		Moderate		Complex	
	Rater A (N = 7)	Rater B (N = 7)	Rater A (N = 6)	Rater B (N = 6)	Rater A (N = 6)	Rater B (N = 6)
Posttreatment overjet						
Mean (SD)	2.86 (1.60)	2.93 (1.51)	4.25 (1.17)	4.25 (1.17)	4.17 (0.753)	4.00 (0.837)
Median [Min, Max]	2.50 [1.00, 5.00]	2.50 [1.50, 5.00]	4.75 [2.00, 5.00]	4.75 [2.00, 5.00]	4.00 [3.50, 5.50]	4.00 [3.00, 5.50]
Posttreatment overjet						
Not normal	2 (28.6%)	2 (28.6%)	5 (83.3%)	5 (83.3%)	6 (100%)	5 (83.3%)
Normal	5 (71.4%)	5 (71.4%)	1 (16.7%)	1 (16.7%)	0 (0%)	1 (16.7%)

30 or less from rater A and B, respectively. Of those patients with passing finishes, two patients had OGS scores <20. The raters assessed 31.6% (95% CI: 14.68–55.51%) and 36.8% (95% CI: 16.87– 61.05%) of the patients, respectively, as having normal overjet post-treatment. Posttreatment overbite was normal in 10 (52.6%) and 11 (57.9%) patients, as determined by rater A and B, respectively. The results showed that 16 (84.2%) and 18 (94.7%) patients achieved normal scores for posttreatment buccal occlusion from rater A and B, respectively.

Table 5 shows the overjet data summary as continuous data and is categorized in groups by rater. Mean overjet (SD) was: 2.86 (1.60) and 2.93 (1.51) for mild cases according to rater A and B, respectively; 4.25 (1.17) for moderate cases according to both raters; and 4.17 (0.753) and 4.00 (0.837) for complex cases according to rater A and B, respectively. Average overjet at posttreatment was in the normal range for patients who presented with a mild discrepancy index. Of the 7 “mild” discrepancy index patients, 5 (71.4%, 95% CI: 34.13–94.66%) had normal posttreatment overjet. This was not the case for patients who had a moderate or complex discrepancy index as their average posttreatment overjet was not normal, on average. Only one patient achieved normal overjet according to both raters in the moderate category, and only rater B found that one patient achieved normal posttreatment overjet in the complex category. Figure 1 shows the pre- and post-treatment overjet values plotted along with the overall data trend. Generally, higher pre-treatment overjet values tended to result in higher posttreatment values. However, this figure is only a snapshot and does not account for initial case complexity. Figure 2 is the same scatterplot with initial discrepancy index indicated. The shaded region represents “normal” overjet for the posttreatment values. The one red point outside of the shaded region represents two patients who both had posttreatment overjet of 5.0 mm. Figure 2 also shows 10 patients (with varying discrepancy index) who had normal pretreatment overjet that did not remain in the normal region for posttreatment. Cases that had a discrepancy index of moderate or complex

finished with overjet that was not normal, though they started with normal overjet pretreatment. Therefore, pretreatment overjet and initial discrepancy index were associated with posttreatment normal overjet values.

Table 6 shows the post-treatment overbite by rater and discrepancy index. The median (SD) posttreatment overbite was 2.64 (0.690) and 2.50 (0.645) for mild cases according to rater A and B, respectively; 3.67 (1.13) for moderate cases according to both raters; and 2.83 (0.931) and 2.92 (0.801) for complex cases according to rater A and B, respectively. Mean and median overbite measurements were within normal limits for those patients who had mild or complex cases. Mean and median values exceeded normal overbite for cases with a moderate discrepancy index. Of the seven mild cases, five and six had normal overbite as measured by Rater A and B, respectively. Of the six complex cases, four had normal overbite post-treatment according to both raters. Only one of the six moderate discrepancy index cases had normal overbite posttreatment, according to both raters. Figure 3 shows a similar trend as overjet; lower pretreatment values were more likely to have lower posttreatment values. Figure 4 indicates the normal window with a shaded region. Although the sample sizes were small, cases with both a mild and complex discrepancy index tended to have normal overbite at posttreatment.

Table 7 shows the posttreatment buccal occlusion by rater and discrepancy index. The mean (SD) post-treatment buccal occlusion was 5.93 (2.26) and 6.00 (2.24) for mild cases according to rater A and B, respectively; 9.92 (3.99) and 9.58 (3.85) for moderate cases according to rater A and B, respectively; and 6.25 (3.16) and 6.33 (2.73) for complex cases according to rater A and B, respectively. Mean and median buccal occlusion measurements were within normal limits for all patients and both raters for mild cases. However, a total of three and one subject(s) exceeded the buccal occlusion maximum distance after treatment based on rater A and B, respectively, for moderate and complex cases. The one subject that both raters assessed as having buccal occlusion that was not normal had a distance of at least 17 mm. Figure 5

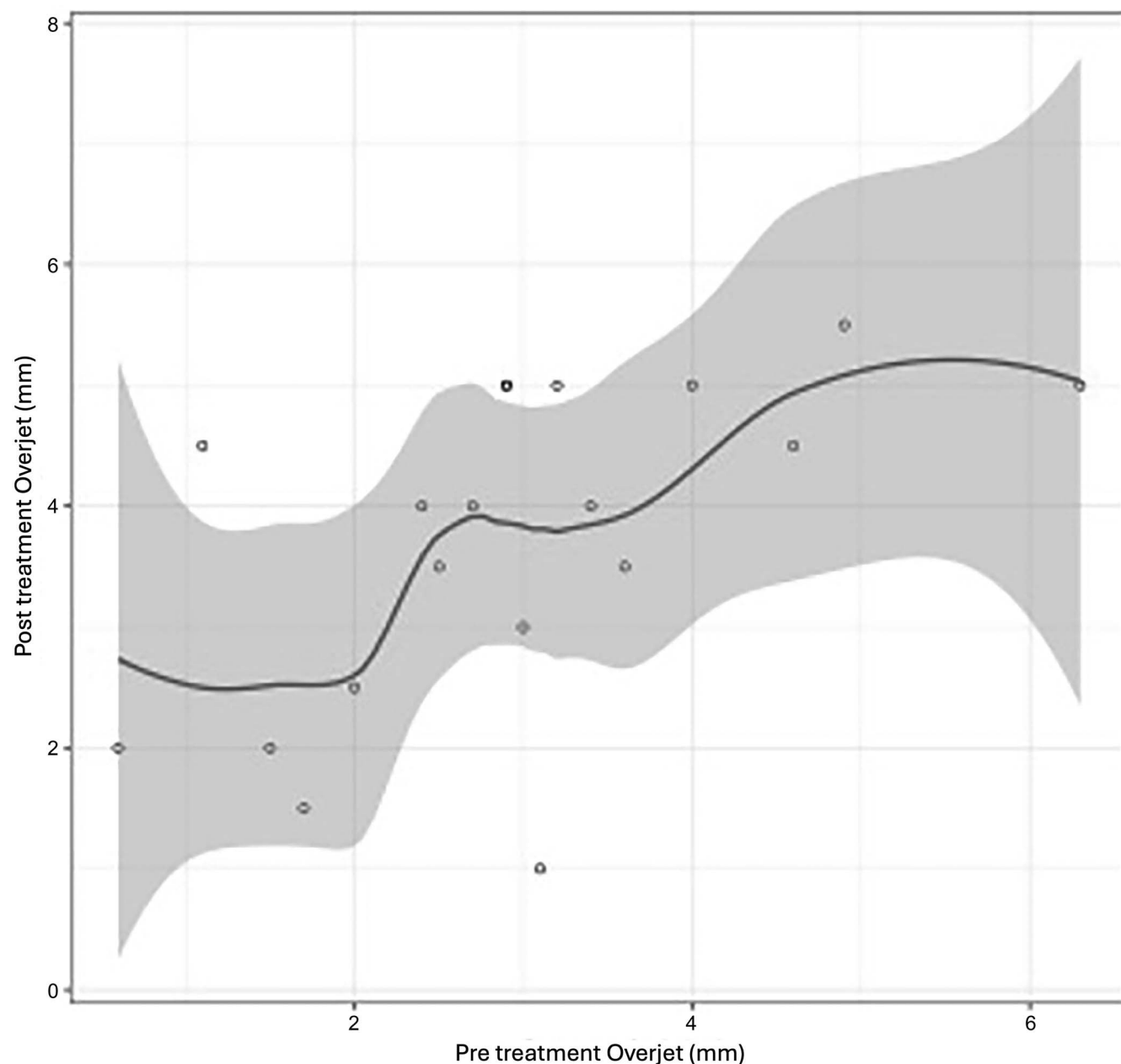


Figure 1. Overjet scatterplot with Loess curve.

shows buccal occlusion before and after treatment. The “normal” range for buccal occlusion at posttreatment is in gray. The discrepancy index is plotted by color with the legend on the right. Even complex cases showed normal buccal occlusion posttreatment, with very few subjects outside the normal range.

DISCUSSION

The primary objective of this study was to evaluate treatment outcomes in patients treated with lower incisor extraction using the ABO-OGS. Given the limited

amount of published data on posttreatment outcomes utilizing this specific treatment modality, the results from this study provide valuable insight into the effectiveness and consequence of lower incisor extraction. By providing objective, data-driven results, this study can help inform clinical decision-making and guide the management of similar cases in orthodontic practice, ultimately contributing to better patient care.

Lower incisor extraction treatment resulted in roughly half of the patients achieving a passing ABO score of ≤ 30 . About one-third of patients had normal overjet post-treatment. However, this was only the case for

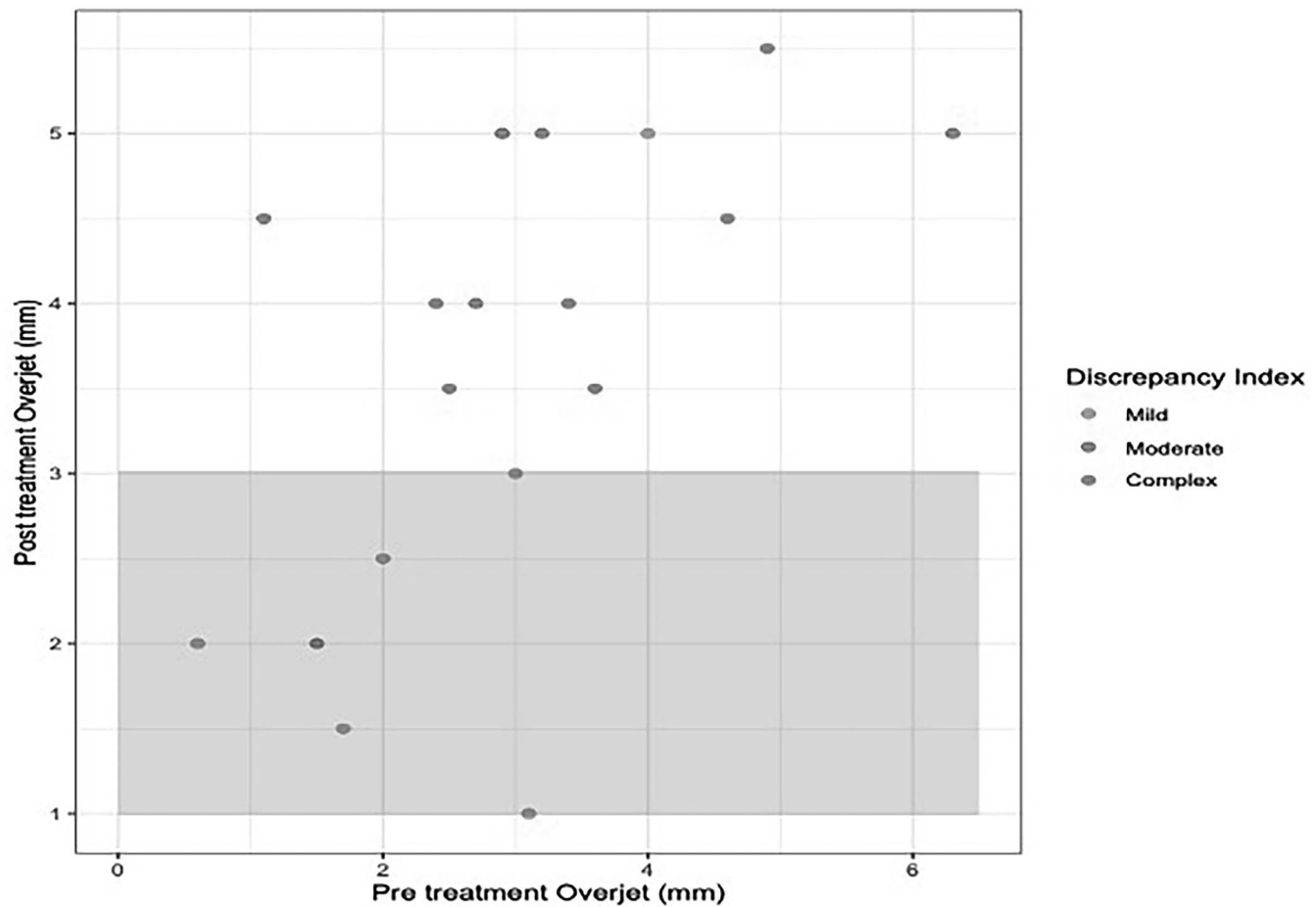


Figure 2. Overjet scatterplot with discrepancy index.

mild cases, as moderate and complex cases resulted in overjet that was not normal (increased). Specifically, mild cases with normal pretreatment overjet finished with normal overjet. Moderate or complex cases with normal overjet finished with overjet that was not normal. Additionally, although posttreatment overjet was considered normal in the mild cases, mean values were at the upper limit of normal, 2.86 mm for rater A and 2.93 mm for rater B (normal < 3mm). These findings show that pretreatment overjet and initial discrepancy index were associated with normal overjet values post-treatment. These results indicated a strong association

between pretreatment overjet, malocclusion severity (discrepancy index), and the likelihood of achieving normal posttreatment overjet. The data emphasize the impact of case complexity on treatment outcomes, particularly highlighting the challenges of managing moderate and complex cases with lower incisor extraction.

Mild and complex cases tended to have normal overbite measures posttreatment. Of those patients in the moderate case category, only one patient was assessed by both raters to have normal posttreatment overbite. Lower pretreatment overbite values were more likely to have lower posttreatment values.

Table 6. Posttreatment Overbite by Rater and Discrepancy Index

	Mild		Moderate		Complex	
	Rater A (N = 7)	Rater B (N = 7)	Rater A (N = 6)	Rater B (N = 6)	Rater A (N = 6)	Rater B (N = 6)
Posttreatment overbite						
Mean (SD)	2.64 (0.690)	2.50 (0.645)	3.67 (1.13)	3.67 (1.13)	2.83 (0.931)	2.92 (0.801)
Median [Min, Max]	2.50 [2.00, 3.50]	2.00 [2.00, 3.50]	4.00 [1.50, 4.50]	4.00 [1.50, 4.50]	3.00 [1.50, 4.00]	3.00 [2.00, 4.00]
Posttreatment overbite category						
Not normal	2 (28.6%)	1 (14.3%)	5 (83.3%)	5 (83.3%)	2 (33.3%)	2 (33.3%)
Normal	5 (71.4%)	6 (85.7%)	1 (16.7%)	1 (16.7%)	4 (66.7%)	4 (66.7%)

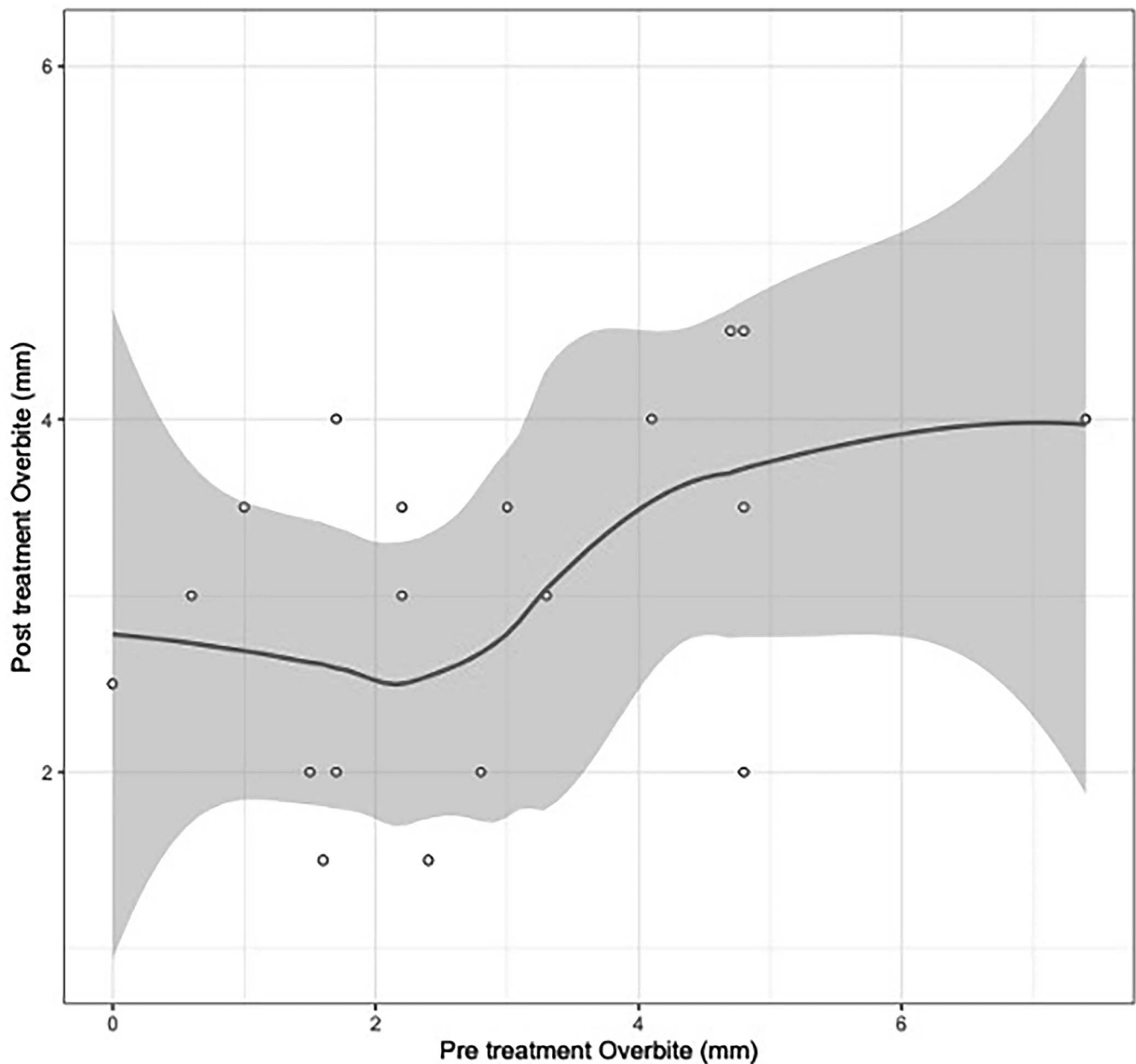


Figure 3. Overbite scatterplot with Loess curve.

Most patients finished with normal buccal occlusion after lower incisor extraction treatment, regardless of the initial case complexity. Specifically, all but three of the 19 subjects were within the normal buccal occlusion maximum distance after treatment. Interestingly, the one subject that both raters assessed as having posttreatment buccal occlusion that was not normal was a case classified in the moderate discrepancy index category, yet they scored >40 for ABO-OGS, far exceeding the failing threshold.

Cansunar et al.⁹ conducted a comparative analysis of orthodontic treatment outcomes across three

protocols: nonextraction, extraction of two maxillary premolars, and extraction of four premolars, utilizing the ABO-OGS. Their study revealed that the nonextraction group exhibited the highest percentage of passing cases (51.2%), followed by the two maxillary premolar extraction group (24.5%), with the lowest percentage observed in the four premolar extraction group (24.3%). In the current study, focusing on single lower incisor extraction cases, an average of 47.35% (Table 4: 52.6% for Rater A and 42.1% for Rater B) met the OGS criteria.

Fida et al.¹⁰ observed that mandibular incisor extraction led to an increase in maxillary anterior

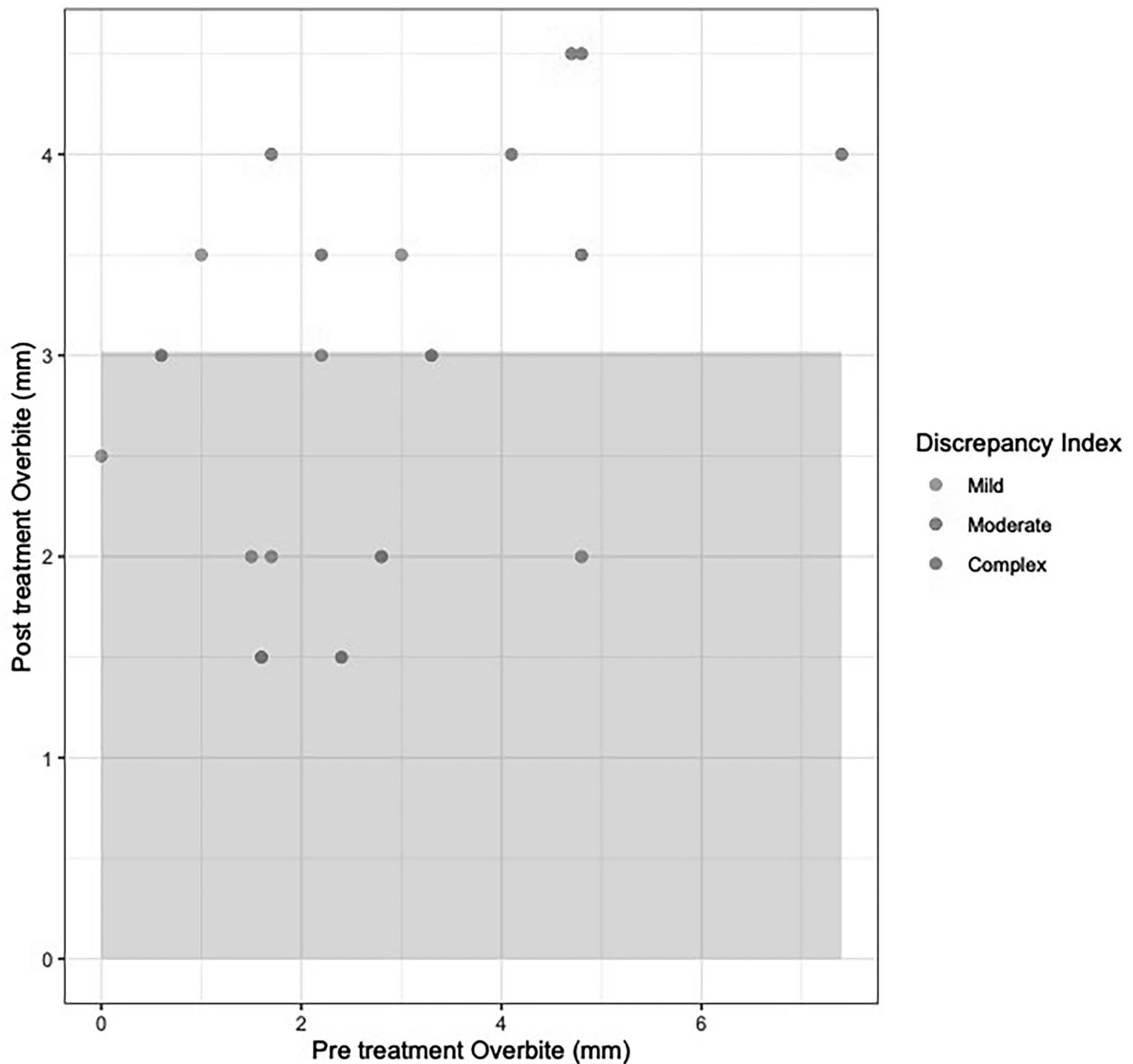


Figure 4. Overbite scatterplot with discrepancy index.

Bolton excess, consequently increasing overjet scores. In the current study, patients presenting with mild discrepancy and normal pretreatment overjet typically concluded treatment with normal overjet. Conversely, moderate or complex cases with normal pretreatment overjet often finished with overjet deviating from normal parameters. Additionally, while post-treatment overjet in mild cases was deemed normal, the mean values approached the upper threshold of normal (2.86 mm). These findings not only establish a correlation between pretreatment overjet and initial discrepancy index with posttreatment normal overjet values, but they were also in agreement

with the findings of Fida et al.,¹⁰ illustrating an average increase of 0.7 mm in posttreatment overjet compared to pretreatment measurements.

It is important to acknowledge some limitations of this study. First, a small sample size of only 19 patients was included. Additionally, the inclusion criteria limited patients to only those treated with incisor extraction in the mandibular arch and nonextraction in the maxillary arch. Future studies can include patients treated with premolar extractions in the maxillary arch, which may potentially affect posttreatment overjet, overbite, and buccal occlusion.

Table 7. Posttreatment Buccal Occlusion by Discrepancy Index and Rater

	Mild		Moderate		Complex	
	Rater A (N = 7)	Rater B (N = 7)	Rater A (N = 6)	Rater B (N = 6)	Rater A (N = 6)	Rater B (N = 6)
Posttreatment buccal occlusion						
Mean (SD)	5.93 (2.26)	6.00 (2.24)	9.92 (3.99)	9.58 (3.85)	6.25 (3.16)	6.33 (2.73)
Median [Min, Max]	5.50 [3.00, 10.0]	5.00 [3.00, 10.0]	8.25 [6.50, 17.5]	8.50 [6.50, 17.0]	6.25 [1.50, 10.5]	6.50 [2.00, 10.0]
Posttreatment buccal occlusion category						
Not normal	0 (0%)	0 (0%)	2 (33.3%)	1 (16.7%)	1 (16.7%)	0 (0%)
Normal	7 (100%)	7 (100%)	4 (66.7%)	5 (83.3%)	5 (83.3%)	6 (100%)

CONCLUSIONS

- Normal overjet, overbite, and buccal occlusion were not achieved in all patients; therefore the null hypothesis was rejected.
- However, further analysis needs to be done to establish the link between initial severity of malocclusion and treatment outcomes.
- The ABO-OGS scores obtained in these cohorts were high, indicating that they may not pass the ABO criteria established.

ACKNOWLEDGMENTS

The authors of this paper would like to acknowledge Dr. Leong for helping with statistical analysis and Dr. Loiy Al Shami for his contribution with data collection.

REFERENCES

1. Little RM, Wallen TR, Riedel RA. Stability and relapse of mandibular anterior alignment-first premolar extraction cases treated by traditional edgewise orthodontics. *Am J Orthod.* 1981;80(4):349–365.
2. Klein DJ. The mandibular central incisor, an extraction option. *Am J Orthod Dentofacial Orthop.* 1997;111(3):253–259.
3. Bennett JC, McLaughlin RP. *Mecánica en el tratamiento de ortodoncia y la aparatología, de arco recto.* Madrid, España: Editorial Mosby/Doyma libros; 1994:35–238.
4. Owen AH. Single lower incisor extractions. *J Clin Orthod.* 1993;27(3):153–160.
5. Zhylich D, Suri S. Mandibular incisor extraction: a systematic review of an uncommon extraction choice in orthodontic treatment. *J Orthod.* 2011;38(3):185–195.
6. Nanda R. *Esthetics and Biomechanics in Orthodontics* (2nd ed.) W.B. Saunders; 2015.
7. American Board of Orthodontics. Available at: <https://www.americanboardortho.com>. Accessed April 9, 2025.
8. The American Board of Orthodontics. *Grading System for Dental Casts and Panoramic Radiographs.* Available at: <https://www.americanboardortho.com/media/1191/grading-system-casts-radiographs.pdf>. Accessed April 9, 2025.
9. Akinci Cansunar H, Uysal T. Comparison of orthodontic treatment outcomes in nonextraction, 2 maxillary premolar extraction, and 4 premolar extraction protocols with the American Board of Orthodontics objective grading system. *Am J Orthod Dentofacial Orthop.* 2014;145(5):595–602.
10. Fida M, Tahir K. Comparison of Bolton analysis between interproximal stripping and mandibular incisor extraction to resolve lower anterior crowding – a cross-sectional study. *Int J Orthod.* 2023;34(2):40–45.